HENRY KIMPTON,
MEDICAL BOOKSELLER,
82, HIGH HOLBORN,
LONDON, W.C.

A 3

Hugh Cecil Earl of Lonsdale.

Descriptive Anatomy of the Horse and Domestic Animals, chiefly compiled from manuscripts of **Thomas Strangeways**, LL.D., M.R.C.V.S., Late Professor of Anàtomy in the Edinburgh Veterinary College, and the late **Professor Goodsir**, F.R.S.S., L. and E. By J. Wilson Johnston, M.D., F.R.S.E., Member of the Royal College of Veterinary Surgeons, Bengal Medical Staff, and T. J. Call, L.R.C.P.E., Honorary Medical Officer to Ilkley Hospital. London. 1870.

8vo. 525 pp. 181 illustrations and photograph of Thomas Strangeways. M., $7\frac{5}{8}$ in. by 5 in.

Dedicated by permission to the Right Honourable Earl of Dalhousie, K.T., G.C.B., Lord-Lieutenant of Forfarshire.

20/- E/-

put 24

9/

NATIONAL SPORTING LIBRARY & MUSEUM

THIS BOOK RESTORED IN 2019

lou-STR 29

DESCRIPTIVE ANATOMY

OF

THE HORSE

AND

DOMESTIC ANIMALS.

Thomas Strangeways, L.L.D.

DESCRIPTIVE ANATOMY

OF

THE HORSE

AND

DOMESTIC ANIMALS

CHIEFLY COMPILED FROM THE MANUSCRIPTS OF

THOMAS STRANGEWAYS, LL.D., M.R.C.V.S.,
LATE PROFESSOR OF ANATOMY IN THE EDINBURGH VETERINARY COLLEGE,

AND THE LATE

PROFESSOR GOODSIR, F.R.SS. L. & E.

BY

J. WILSON JOHNSTON, M.D., F.R.S.E.,
MEMBER OF THE ROYAL COLLEGE OF VETERINARY SURGEONS, BENGAL MEDICAL STAFF,

AND

T. J. CALL, L.R.C.P.E.,
HONORARY MEDICAL OFFICER TO ILKLEY HOSPITAL.

EDINBURGH:
MACLACHLAN AND STEWART, SOUTH BRIDGE.
LONDON: SIMPKIN, MARSHALL, & CO.
MDCCCLXX.

1870

PRINTED BY NEILL AND COMPANY, EDINBURGH.

DEDICATED,

By Permission,

TO THE

RIGHT HONOURABLE EARL OF DALHOUSIE,
K.T., G.C.B.,

LORD-LIEUTENANT OF FORFARSHIRE,

WHOSE BRILLIANT PUBLIC CAREER

IS GRATEFULLY ACKNOWLEDGED BY HIS COUNTRY,

AND WHOSE GENEROUS PRIVATE CHARACTER HAS ENDEARED HIM

TO HIS TENANTRY.

PREFACE.

On the death of Professor Strangeways, there was a very general feeling that his anatomical lectures should be given to the world. Working daily with him during my furlough, and being present at his death-bed, I was solicited to take the matter in hand. His friend, Dr Call, and I accordingly undertook to rewrite and arrange the lectures.

The late Professor Goodsir's detached manuscript on the Myology of the Horse was, after an effectual search, discovered, and considerately placed in my hands by his brother, the Rev. Joseph Taylor Goodsir, F.R.S.E. It is believed this will enhance the value of the work, more especially as Strangeways was not only an ardent admirer of the great anatomist, but he informed me his principal lectures had been perused and approved of by Professor Goodsir.

Strangeway's lectures, although generally very complete

and excellent, demanded an entire recasting. In doing so, I adopted Leyh's arrangement, which, with due regard to French and English veterinary anatomy, I selected as the best.

Dr Call, notwithstanding his many professional engagements, has rewritten the Osteology and the Anatomy of the Nervous System, the Eye, and the Ear. The Comparative Osteology, the Ligaments, Muscles, Digestive, Urinary, Sexual, and Respiratory Organs, and the Organs of Circulation, Lymphatics, Skin, and Hoof, have fallen to my lot.

It has been our object to produce what is greatly desiderated—a thorough-going Manual of Anatomy for the veterinary student.

The Photo-lithographs, with few exceptions, are selections from Leyh and Lecoq's classical works. To Dr Morrison Watson, Assistant Demonstrator of Anatomy in Edinburgh University, my thanks are due for his assistance in arranging them during my absence on the Continent.

The Editors cordially thank Mr Thomas H. Douglas, Photographer, Chamberlain Road, for his handsome gift of the Vignette of his friend, which will be appreciated by all the Professor's former students.

Messrs Maclachlan and Stewart, the Publishers, deserve every praise for the generous manner in which they have undertaken the publication; and Messrs Waterston, Hanover Street, for the style of the photo-lithographs.

To Professor Turner of Edinburgh University, and Mr Joseph Johnston of Montrose, I am indebted for many valuable suggestions.

The work owes no small measure of its completeness to the kindly helping-hand of Dr John Gray M'Kendrick, Assistant to the Professor of Physiology in the University of Edinburgh, who not only has been of immense service to me in the tedious work of proof correcting, but to whom the Editors are indebted for the complete Index and Glossary which accompanies the work.

The Appendices speak for themselves. The work would have been incomplete without a "dissection manual," and a translation was accordingly made of Chaveau's directions, adopted because they are superior to any I am acquainted with.

The Editors confidently commend the work to the veterinary student, farmer, stockbreeder, and to any and every one interested in domestic animals, inasmuch as the true pathological site of disease is incidentally pointed out *au courant* with the anatomical description. The Dentition Plates of the Horse, Cow, Sheep, and Dog, afford a *coup d'œil* which will be a reminder to the adept, and a useful guide to the veriest tyro in the difficult subject of dentition as an index of age.

It has been our effort to produce the work at the lowest remunerative rate commensurate with the interests of the deceased's family, to whom all benefit directly passes.

Assured that the student will find in these pages a good *quid pro quo* investment, we leave it with him, along with Seneca's advice and the sententious rule given by Sir William Hamilton in an autograph letter—

"Non multa sed multum."

"Be more anxious to read attentively a few than to read many works."

J. WILSON JOHNSTON.

KINNABER HOUSE,
Sept. 24, 1869.

CONTENTS.

PAGE

INTRODUCTION, . . . 1

OSTEOLOGY.

Characters and histology of bone, ... 2
Periosteum, . . . 6
Long bones, . . . 7
Flat bones, . . . 8
Irregular bones, . . 9
Nomenclature of Osteology, 10–11
Formation of bone, . . 12
Cartilage, . . . 13
Nomenclature in Veterinary Anatomy, . . . 14
THE VERTEBRAL COLUMN, . 15
General characters, . . 15
Cervical vertebræ, . . 17
First Cervical, Atlas, . 18
Second Cervical, Axis, . 20
Sixth Cervical, . . 21
Seventh Cervical, . . 21
Dorsal vertebræ, . . 22
Lumbar vertebræ, . . 24
False vertebræ, . . . 25
Sacrum, . . . 25
Coccyx, . . . 27
THE PELVIS, ... 27
Ossa innominata, . . 27
Ilium, . . . 28
Ischium, . . . 29
Pubis, ... 30
THE THORAX, . . . 32
Sternum, ... 32
Ribs, ... 33
Thorax as a whole, . . 35

PAGE

FORE EXTREMITY, . . . 36
Scapula, . . . 36
Humerus, . . . 37
Radius, . . . 40
Ulna, . . . 41
Carpus, . . . 42
Scaphoid, . . . 43
Os lunare, . . . 43
Cuneiform, . . . 44
Trapezium, . . . 44
Trapezoid, . . . 45
Magnum, . . . 45
Unciform, . . . 46
Pisiform, . . . 46
Metacarpal bones, . . 46
Os metacarpi magnum, . 47
Ossa metacarpi parvi, . 48
Os suffraginis, . . . 49
Two Sesamoid bones, . 50
Os coronæ, . . . 50
Os pedis, . . . 51
Os naviculare, . . . 52
HIND EXTREMITY, . . . 53
Femur, ... 53
Patella, ... 55
Tibia, ... 56
Fibula, ... 57
Tarsus or Hock, . . 57
Astragalus, . . . 58
Os calcis, . . . 58
Os cuboides, . . . 59
Os cuneiforme magnum, 60
Os cuneiforme medium, 60
Os cuneiforme parvum, 60
Os metatarsi magnum, . 61
Ossa metatarsi parvi, . 61

PAGE

THE SKULL, 69
The Cranium, 69
Occipital bone, 69
Parietal bones, 74
Frontal bones, 75
Temporal bones—
Squamous temporal, 66
Petrous temporal, 67
Sphenoid bone, 69
Ethmoid bone, 71
The Face, . 72
Nasal bones, . . 73
Superior maxillary bone, 73
Inter-maxillary bone, 76
Malar or Jugal bone, 76
Lachrymal bone, . 76
Palatine bone, 77
Vomer, . . 78
Pterygoid bones, . 78
Turbinated bones, 79
Inferior maxillary, 80
Os hyoides, . . 81
The Skull as a whole, 82
Cranial cavity, 85
Nasal fossæ, . 86
Sinuses, . . 86
COMPARATIVE OSTEOLOGY, 87
Skull of ox, 87
pig, 90
dog, . . 92
Vertebral column of ox, 94
of sheep. 94
Ribs of ox, 90
of sheep, . . . 96
Hind limb of ox and sheep, 96
Vertebral column of pig, . 99
of dog, . 101
Ribs of dog, . . . 103
Fore extremity of dog, . 103
Hind „ „ . 104

SYNDESMOLOGY.

Classes of joints, . . 105, 110
General characters of joints, . 105
Varieties of cartilage, . . 106
Varieties of ligaments, . . 108
Varieties of synovial membranes, 109
ARTICULATIONS OF TRUNK AND HEAD, ... 112
Articulations of the vertebral column, ... 112

PAGE

ARTICULATIONS OF TRUNK AND HEAD—*continued*
Articulations of the atlas, axis, and occipital, 114
Temporo-maxillary, 115
Sacro-lumbar, 115
Costo-vertebral, . 115
Costo-sternal, 116
Sacro-iliac of horse, 116
of cow, 117
Ischio-pubic, . . 117
Ligaments of os hyoides, 117
ARTICULATIONS OF FORE EXTREMITY, . . . 118
Shoulder joint, 118
Elbow „ 118
Carpal „ . . . 119
ARTICULATIONS OF HIND EXTREMITY, . . 123
Hip joint, . 123
Stifle joint, 124
Tarsus, 126

MYOLOGY.

Characters of tendons, 128
Varieties of 128
Aponeuroses, . . . 129
Muscular nomenclature, . 129
Fascæ, ... 130
Histology of muscular tissue, 131
Voluntary, . . 132
Involuntary, . . 132
Connective or areolar tissue, 133
Muscles of subcutaneous region, 134
Inferior abdominal .. 135
Axillary 140
Inferior cervical 142
Superior „ 146
Dorsal scapular 151
Costal „ 153
Sternal „ 155
Dorsal 156
Internal femoral „ 160
Anterior crural 162
Gluteal 165
Posterior crural 167
Diaphragmatic 170
Auricular 171
Palpebral 174
Facial 175
Anterior maxillary 175

	PAGE
Muscles of posterior region,	178
Hyoidean „	180
Glossal „	182
Sacro-coccygeal „	183
Fore limb,	186
Scapular „	186
Humeral „	189
Anterior brachial „	190
Posterior „ „	191
Fore-arm,	193
Anterior region of fore-arm,	193
Posterior „ „	196
Hind extremity,	199
Anterior tibial region,	200
Posterior „ „	201
COMPARATIVE MYOLOGY,	204

ORGANS OF DIGESTION.

Physiological operations,	207
Mouth,	207
Palate,	208
Soft palate,	209
Tongue,	210
Salivary glands,	212
Parotid,	213
Submaxillary,	213
Sublingual,	213
Saliva,	214
TEETH.	
Chemical analysis,	215
Histology.	
General,	215
Dentine,	216
Enamel,	216
Crusta petrosa,	217
In the horse,	217
Incisors	217
Canines,	219
Molars,	219
Development,	220
As indicative of age in the horse,	223
Girard's method,	225
Tonsils,	226
Pharynx,	226
Œsophagus,	227
In ox,	227
ABDOMEN,	228
Divisions,	229
Stomach,	229
Intestines,	231
Small,	231
Large,	233
ACCESSORY ORGANS OF DIGESTION,	237
Liver,	237
Duct,	241
Pancreas,	241
Duct,	242
Spleen,	242
Peritoneum,	244
SPECIAL VARIATIONS IN DIGESTIVE APPARATUS OF RUMINANTS.	
Ox lips,	245
Cheeks,	245
Palate,	246
Tongue,	246
Parotid,	246
Teeth,	246
As indicative of age,	247
Pharynx,	249
Œsophagus,	249
Stomach,	249
Intestines,	254
Liver,	254
Pancreas,	255
Spleen,	255
SHEEP lips,	245
Cheeks,	245
Tongue,	246
Teeth,	248
As indicative of age,	248
RUMINATION,	255
SPECIALITIES IN DIGESTIVE APPARATUS OF PIG AND DOG.	
PIG.—Mouth,	255
Teeth,	256
As indicative of age,	257
Stomach,	258
Intestines,	258
Liver,	258
Pancreatic duct,	258
DOG.—Lips,	255
Salivary glands,	256
Teeth,	257
As indicative of age,	258
Stomach,	258
Intestines,	258
Liver,	258
Pancreatic duct,	258

PAGE

URINARY ORGANS.

Urine, . 259
Kidneys, general anatomy, 259
In horse, 259
In ox, ... 259
In sheep, ... 259
Histology, ... 260
Ureters, ... 262
Bladder, ... 262
Suprarenal capsules, 268
Bladder in Fœtus, . . . 263

SEXUAL ORGANS.

Varieties of modes of reproduction, ... 264

IN MALE.

Testicles, general anatomy, 266
Histology, . . . 267
Prostate vesicle, . . 268
Cowper's glands, . . 269
Urethra, ... 270
Penis, ... 271
Muscles, . . . 272

IN FEMALE.

External.

Vulva, ... 273
Vagina, . . . 275

Internal.

Uterus, . . . 275
Fallopian tubes, . . 277
Ovaries, . . . 277

SPECIALITIES IN GENERATIVE ORGANS OF DOMESTIC ANIMALS.

BULL.—Testicles, 278
Vesiculæ seminales, 278
Penis, . . . 278
COW.—Canals of Gaertner, 279
RAM.—Vasa deferentia, 278
BOAR.—Testicles, 279
Penis, . . . 279
SOW.—Canals of Gaertner, 279
Clitoris, . . . 279
Ovaries, . . . 279
DOG.—Testicles, &c., . 279
Penis, ... 280
CAT.—Testicles, &c., . . 279
Penis, ... 280
Mammary glands, 280
In cow, ... 282
Milk, analysis, &c. 282

PAGE

ORGANS OF RESPIRATION.

Physiology of respiration, 283
Nose, ... 284
Ass and mule, . . 284
Ox, ... 285
Pig, ... 285
Dog, ... 285
Nasal chambers, . . . 285
Ox and sheep, . . . 287
Sinuses, . . . 287
Pharynx, ... 287
Larynx, ... 287
Cartilages, . . . 288
Muscles, ... 290
Ligaments, . . . 292
Trachea, ... 294
Thymus gland, 294
Bronchi, ... 295
Bronchial glands, 295
THORAX, ... 295
Lungs, ... 296
of ruminants, . . 298
of pig, ... 299
of dog, ... 299
of birds, . . . 299

ORGANS OF CIRCULATION.

General characters of blood, . 300
Pericardium, ... 301
Heart, ... 302
Course of circulation, 302
Right auricle, 303
Right ventricle, 305
Left auricle, 307
Left ventricle, 307
Structure of heart, 308
Arteries, 311
General anatomy, 311
Arterial system, 314
Pulmonary, . . 314
Aorta, ... 315
Posterior, . . . 316
Visceral Branches.
Posterior intercostals, 316
Lumbar, ... 317
Phrenic, ... 317
Middle sacral, . . 317
Thoracic Visceral Branches.
Bronchial, ... 317
Œsophageal, . . . 317

PAGE

Abdominal Visceral Branches.

Cœliac axis, . . . 318
Gastric, . . . 318
Splenic, . . . 318
Hepatic, . . . 318
Anterior mesenteric, . . 319
Renal, ... 319
Spermatic, . . . 319
Utero-ovarian, . . 320
Posterior mesenteric, . . 320
Internal iliac, . . . 320
Umbilical, . . 320
Vesico-prostatic, . . 320
Obturator, . . 321
Ischiatic, . . . 321
Pudic, . . . 321
Gluteal, . . . 321
Lateral sacral, . . 321
Perenial, . . . 321
External iliac, . . . 321
Branches, . . . 322
Artery of cord, . . 322
Deep femoral, . . . 322
Branches, . . . 323
Femoral, ... 323
Popliteal, . . . 324
Posterior tibial, . . 324
Anterior tibial, . . 325
Collateral metatarsal, . . 325
Large metatarsal, . . 325

Anterior aorta, . . . 325
Arteria innominata, . . 325
Branches, . . . 326
Axillary, . . . 327
Humeral, or brachial, . 328
Deep humeral, . . 328
Anterior radial, . . 329
Posterior radial, . . 329
Small metacarpal, . . 329
Large „ . . . 330
External and internal plantar, . 330
Right innominate, . . . 332
Common carotid, . . 332
Thyroid accessory, . 332
Thyro-laryngeal, . . 332
Occipital, . . . 333
Prevertebral, . . . 333
Mastoid, ... 333
Retrograde, . . . 333
Musculo-occipital, . . 333
Cerebro-spinal, . . . 333

PAGE

Internal carotid, . . . 334
External „ . . . 335
Submaxillary, . . . 335
Maxillo-muscular, . . 337
Posterior auricular, . . 337
Superficial temporal, . 337
Internal maxillary, . . 338
Ophthalmic, . . . 339

VEINS.

General anatomy, . . 341
Pulmonary, . . . 343
Cardiac, . . . 343
Bronchial, . . . 343
Posterior vena cava, . . 344
Phrenic, . . . 344
Hepatic, ... 344
Portal, ... 344
Renal, ... 345
Spermatic, . . . 345
Lumbar, ... 345
Common iliacs, . . 345
Laminal plexus, . . 346
Coronary plexus, . . 346
Plantar, ... 347
Metatarsal, . . . 347
Anterior tibial, . . 348
Posterior tibial, . . 348
Vena saphena major, . . 348
minor, . . 349
Popliteal, . . . 349
Femoral, . . . 349
External iliac, . . . 349
Internal iliac, . . . 349
Internal thoracic, . . 350
Vertebral, . . . 350
Superior cervical, . . 350
Dorsal, ... 350
Vena azygos, . . . 350
Axillary, . . . 350
Pedal plexus, . . . 351
Metatarsal, . . . 351
Posterior radial, . . 351
Anterior radial, . . 351
Ulnar, ... 351
Internal brachial, . . . 352
External subcutaneous brachial, 352
Subcutaneous thoracic, . 352
Humeral, . . . 352
Jugular, ... 352
Branches, . . . 353
Internal maxillary, . . . 354

PAGE

Veins—*continued.*
Lingual, . . . 355
Circulation of the Fœtus, 355

LYMPHATICS.

General Anatomy, 356
Glands, 357
Thoracic duct, . . . 358
Lymphatics of posterior extremity, organs of pelvis, and abdominal wall, 359
of organs situated in thorax, 362
of thoracic wall, . . 363
of head, neck, and fore-limb, 363

NERVOUS SYSTEM.

General anatomy, 365
White fibres, 366
Grey fibres, 366
Nerve cells, . 366
Structure of nerves, 367
Origin of nerves, 367
Terminations of nerves, 367
Meninges of Spinal Cord, 368
Meninges of Brain, 369
Spinal Cord, . . 372
The Encephalon, . . 374
Medulla oblongata, 374
Inferior pyramids, 374
Corpora olivare, 374
Corpora restiformæ, 375
Superior pyramids, 375
Intermediate fasciculi, 375
Pons Varolii, . . . 375
Cerebellum, . . 376
Fourth ventricle, 377
Cerebrum, . . 377
Pituitary gland, . 378
Tuber cinereum, 379
Corpora albicans, 379
Olfactory bulbs, 379
Corpus callosum, 380
Lateral ventricles, 380
Septum lucidum, 381
Fornix, . . 381
Corpus fimbriatum, 382
Hippocampus, 383
Corpus striatum, 383
Tænia semicircularis, 383
Velum interpositum, 383
Choroid plexus, 383
Optic thalamus, 383

PAGE

Cerebrum—*continued.*
Third ventricle, . 384
Pineal gland, 384
Corpora quadrigemini, or optic lobes, . . . 385

ENCEPHALIC CIRCULATION.

Arterial, 386
Venous, 388
Sinuses, 389

Cranial Nerves, 390
1st pair, Olfactory, 391
2d pair, Optic, 391
3d pair, Motores oculorum, 392
4th pair, Pathetici, 392
5th pair, Trifacial, 392
Ophthalmic, 393
Superior maxillary, 394
Inferior maxillary, 394
Lingual, . 395
6th pair, Abducens, 396
7th pair, Portio dura, . 396
8th pair, Mollis, . . 396
9th pair, Glosso-pharyngeal, 398
10th pair, Pneumo-gastric, 398
11th pair, Spinal accessory, . 400
12th pair, Hypo-glossal, 401
Spinal Nerves, . . 401
Cervical, 402
Dorsal, 404
Lumbar, 404
Sacral, 406
Coccygeal, . . . 406
Nerves formed by inferior branches of the spinal nerves, 407
Brachial plexus, . 407
Lumbo-sacral plexus, . 410
Sympathetic nerves, 413
Cervical portion, 414
Thoracic, 416
Lumbar, 418
Sacral, 419

ORGAN OF HEARING.

External ear, 419
Meatus, . . 419
Membrani tympani, 420
Bones of ear, . . 420
Tympanum, . 420
Muscles of ear, 421

PAGE

ORGAN OF HEARING—*continued.*

Ligaments of ear, ... 421
Internal ear, ... 422
Guttural pouches, ... 424

THE EYE, WITH ITS APPENDAGES.

Globe, ... 424
Tunics of eyeball, ... 425
Humours of eye, ... 429
Muscles of eye, ... 429
Appendages of eye, . . . 431
Lachrymal apparatus, . . . 433

THE SKIN AND ITS APPENDAGES.

Epidermis, ... 434
Dermis, ... 435
Hair, ... 435
Glands of skin, ... 436

THE FOOT OF THE HORSE.

Wall, ... 437
Sole, ... 438
Frog, ... 439

PAGE

FOOT OF HORSE—*continued.*

Horn, ... 440, 441
Fatty or sensitive frog, . . 442
Sensible sole, ... 443

APPENDIX.

I. Dissections, ... 445
Of ligaments, . . . 445
Muscles, ... 446
Organs of digestion, 456
Respiration, . 460
Urination, . . 460
Circulation, . 461
Lympatic system, . 464
Nervous system, . 465
II. Morphology of vertebrate skeleton, ... 469
III. On the supernumerary oblique muscle of the eyeball, ... 472
IV. Upon a non-striped muscle connected with the orbital periosteum of man and mammals, . . 474
V. On the dentition of domestic animals, ... 479
INDEX, ... 483

ERRATA.

Page 177, to foot note *add* initials "J. W. J."
,, 384, line 31, *for* "acqueduct" *read* "aqueduct."
,, 384, ,, 31, *for* "quartam" *read* "quartum."
,, 398, ,, 1, *for* "Dura" *read* "Mollis."
,, 400, ,, 32, *for* "vagnum" *read* "vagum."
,, 422, ,, 21, *for* "penetarting" *read* "penetrating."
,, 422, ,, 31, *for* "scalævestibuli" *read* "scalæ vestibuli."
,, 424, ,, 7, *for* "liquor scarpæ" *read* "liquor Scarpæ."

DIRECTIONS FOR PLATES.

Plate	I.	Skeleton of Horse and Ox,	To face page 15
,,	II.	,, of Cat, Dog, and Pig,	,, 87
,,	III.	Ligaments of Trunk,	,, 113
,,	IV.	,, of Extremities,	,, 119
,,	V.	Muscles of Head and Fore-Leg,	,, 143
,,	VI.	,, of Fore-Leg,	,, 193
,,	VII.	,, of Trunk and Hind-Leg,	,, 159
,,	VIII.	,, of Hind-Leg and Tail,	,, 165
,,	IX.	Dentition of Horse,	,, 217
,,	X.	,, ,, as indicative of age,	,, 223
,,	XI.	,, of Ox,	,, 247
,,	XII.	,, of Ox and Sheep,	,, 248
,,	XIII.	,, of Dog,	,, 257
,,	XIV.	Digestive Organs,	,, 227
,,	XV.	,, of Ox, Pig, and Dog,	,, 251
,,	XVI.	,, Liver and Spleen of Horse and Ox,	,, 237
,,	XVII.	Male Generative Organs,	,, 267
,,	XVIII.	Female ,,	,, 275
,,	XIX.	Respiratory Organs,	,, 285
,,	XX.	Circulatory Organs—Heart and Arteries.	,, 303
,,	XXI.	,, Arteries of Head and Neck,	,, 333
,,	XXII.	,, Arteries of Thorax and Abdomen,	,, 317
,,	XXIII.	,, Arteries of Abdomen,	,, 319
,,	XXIV.	,, ,, of Limbs,	,, 327
,,	XXV.	,, Veins,	,, 345
,,	XXVI.	,, Portal Vein and Thoracic Duct,	,, 359
,,	XXVII.	Brain and Ear,	,, 379
,,	XXVIII.	Cranial Nerves,	,, 391
,,	XXIX.	Spinal ,,	,, 405
,,	XXX.	Visceral ,,	,, 417
,,	XXXI.	The Eye,	,, 425
,,	XXXII.	The Hoof,	,, 437

DESCRIPTIVE ANATOMY

OF THE

HORSE AND DOMESTIC ANIMALS.

Descriptive Anatomy comprehends Human, Comparative, and Veterinary. Human deals with man only, Veterinary with domestic animals, while Comparative embraces the rôle of zoological life. This work treats only on Veterinary Anatomy. The horse is the type or standard, the specialties of other domestic animals being noted.

We describe, *seriatim*—

Organs of Locomotion, including bones, ligaments, and muscles.

Digestive organs.

Urinary ,,

Sexual ,, male and female.

Respiratory ,,

Organs of Circulation, including arteries and veins.

Lymphatics.

Nervous System, including brain, spinal cord, spinal and sympathetic nerves.

Organs of Sense, including eye and ear.

Skin.

Hoof.

OSTEOLOGY.

Bones are hard, yellowish-white, insensible bodies, consisting of inorganic salts and a cellular lemma of organic matter; they form the endoskeleton, give attachment to soft parts, and are admirably adapted for variety of function, being of every size, form, and density. In the limbs they are usually cylindrical, with expanded extremities, and thus not only effectually support the body and afford leverage and attachment to the muscles, but form the basis of all true joints. Where cavities, such as the cranium, chest, and pelvis, enclose viscera essential to life, the osseous framework assumes a flat, expanded shape.

Living bone is bluish pink, insensible, and elastic. On exposure to air, bone gets diseased, assumes a black or whitish hue, and is extremely sensible and painful; it is harder and, teeth excepted, of a higher specific gravity than any other animal tissue. To earthy salts, it owes its density and hardness, to animal matter, elasticity and tenacity—this union being calculated to withstand all ordinary stress, rendering it solid and elastic enough to obviate fracture from causes to which it is naturally exposed. These substances are so intimately blended that, to the naked eye, it appears homogeneous. But, by steeping in dilute hydrochloric acid, the earthy matter is dissolved, while the tough flexile animal cast is left. Again, if we expose, burn, or boil it, we get rid of the animal matter, and a white, brittle, earthy, chalky substance is left, retaining its original shape.

The relative proportions of animal and earthy matter vary at different periods of life. In the young, the organic constitutes nearly one half of the bone, in the adult it diminishes to about a third, while in old age the earthy matter increases, which is the reason that the bones of old animals are brittle, inelastic, and so liable to fracture. The animal and earthy proportions do not vary in the true bone tissue, but there is a gradual filling up of the cavities originally occupied by fat cells, thus condensing

the bone. The earthy ingredients consist chiefly of carbonate and phosphate of lime; the animal matter of a cartilaginous basis or gelatine, vessels, membrane, lining the cancellated structure and medullary cavities, and a quantity of fat. An average analysis, by Von Bibra, is appended :—

	Femur of 4-year old Sheep.	Femur of 4-year old Bull.	Femur of 6-year old Horse.	Humerus of 6-year old Cat.
Phosphate of Lime, with trace of Fluoride Calcium, . .	55·94	54·07	54·37	59·30
Carbonate of Lime, . .	12·18	12·71	12·00	10·69
Phosphate of Magnesia, . .	1·00	1·42	1·83	1·70
Soluble Salts, . . .	0·50	0·80	0·70	0·40
	69·62	69·00	68·90	72·09
Cartilage, ...	29·68	29·09	27·99	27·21
Fat, &c., ...	0·70	1·91	3·11	0·70
	30·38	31·00	31·10	27·91
	100·00	100·00	100·00	100·00

You see, then, that in adult bones the proportion of animal matter is about a third, varying in different animals and bones of the same skeleton. The bones of the young may have too great a proportion of animal matter, when they give way under the superincumbent weight, as in rachitis; ossification advancing, the animal becomes a cripple. This disease, rare in the foal, sometimes occurs in the calf, and frequently in the pig and dog. The degree of hardness varies not only with the age, but also with the class of the animal, the bones of birds being white, hard, and brittle, especially those of the wings and legs; the bones of the chamois and its congeners are also very hard and brittle, whereas fish bones are soft and flexible. The bones of some fish contain a great proportion of animal matter, and these are known as cartilaginous fish. In different parts of the same skeleton they vary in hardness, the petrous temporal being the hardest in the body. The shank bones are also very hard and

dense; the ribs, again, are soft and flexible; the external plates of flat bones are harder than the internal. The leg bones of a thorough-bred are more compact than those of a heavy cart-horse. The latter are larger, but do not weigh so much, because the shell is more expanded, and much thinner, containing less compact and more cancellated tissue, the animal requiring greater surface for muscular attachments; whereas, in the thorough-bred, a greater density of bone is necessary to meet the intense concussion of speedy action. Thus it is decreased in size, but increased in thickness of shell, affording the maximum of strength with the least expenditure of material.

In all bones there are two modifications of texture, the compact and cancellated. The former—hard, dense, and ivory-like—is always situated externally; the latter—porous and spongy—lies within. They exist in an inverse ratio. The shaft of a long bone is made up entirely of compact tissue, arranged cylindrically round the cavity or medullary canal, which not only renders the bone lighter, but considerably stronger—a hollow cylinder being stronger than a solid one—while its extremities consist almost entirely of cancellated, with a thin investing layer of compact, tissue. In all irregular bones this tissue is thin, and encloses a large cancellated surface. Flat bones, likewise, consist of external plates or tables, with an interposed lattice-like texture or cancelli, and, like the medullary canal, replete with marrow in the cranial flat bones. These cancelli become diploë. The direction of the bony plates forming the cancelli is always that in which the weight falls. They are arranged at various distances, and so disposed as to allow free communication between the cancelli.

Although the compact tissue appears uniformly dense, and destitute of porosity, yet, if we transversely section the shaft of a long bone, and examine it under the microscope by transmitted light, it is found to contain numerous round openings. These are called Haversian canals, and transmit blood-vessels. They run in a longitudinal direction, but have many

transverse branches of communication, which are often of greater diameter than the trunks. These canals are $\frac{1}{1200}$th of an inch apart, and surrounded by concentric layers of bone or lamellæ, which are shady or opaque, and vary in number from ten to twelve, the internal being most distinct, each succeeding one becoming less so. Amongst them may be seen many dark, irregular, oval, and stellate bodies. These are the minute reservoirs or lacunæ which, in the living bone, are filled with nutritious fluid. From the lacunæ, from their irregular edges, pass a number of dark radiating lines, which always decrease in diameter and increase in number as they recede from the lacunæ. These are the minute tubular vessels or canaliculi, which establish a vascular communication between the Haversian canal and the lacunæ. On the external shell of the compact tissue of long bones, lying immediately within the periosteum, are several concentric osseous layers passing completely round the shaft. There is also a corresponding concentric disposition of layers on the inner or medullary surface. Both of these systems of lamellæ are in a great measure destitute of Haversian canals, and are supplied with nutrition by means of lacunæ and canaliculi, disposed generally as in the compact tissue.

The size of these bone capillaries varies, but the average diameter of the canaliculi is $\frac{1}{1800}$th, and that of the Haversian canals $\frac{1}{600}$th of an inch. The lacunæ are somewhat oval, and lie with their long diameters, which are about $\frac{1}{1800}$th of an inch, parallel to the lamellæ. Their short diameter is $\frac{1}{3600}$th of an inch. The compact tissue is therefore copiously supplied with nutriment by means of minute vessels, which enter from almost every conceivable point, covered by periosteum and endosteum. Each Haversian canal may be considered a vascular longitudinal centre, round which successive concentric layers of bone are arranged, so as to form a dense cylindrical ossicle. Series of these are repeated, and united by laminæ destitute of canals, but with closely packed canaliculi and lacunæ, and called connecting laminæ, or Haversian interspaces, the whole of them

being encircled by the external and internal concentric osseous laminæ, constituting the entire long shaft in such a way as to combine strength and economy of material with efficient nutrition, which is sustained by the canals, canaliculi, and lacunæ. The last two only transmit the fluid portion of the blood. The canaliculi may interlace, pass right through the laminæ to the nearest Haversian canal, open into the medullary canal or cancelli, on to the bony superficies.

The external surface of every bone is covered by a tough, fibro-vascular, inelastic membrane, the periosteum, unless where tendons play over it, or at the articular surface which is covered by cartilage.

The *Periosteum*, firmly adherent to the bone, is composed of a dense network of white fibrous tissue, amongst which blood-vessels are minutely distributed before entering the osseous tissue. It affords support, protection, and nutrition to the superficies, secures muscular attachment as well as tendons and ligaments, the latter frequently becoming continuous with it; it varies in thickness, being dense and strong on bones nearest the skin, and liable to injury; in the horse, it is well developed on the inner surface of the tibia, over the anterior surfaces of large metacarpal and metatarsal bones, and on the face it is thin where muscles abound. By its strength it sometimes retains surfaces in contact after an oblique fracture; in the young, it is thicker and more vascular than in the adult. Blood vessels which ramify in the periosteum pass directly to the bone; the external surface of a long bone of a young animal is always studded with numerous foramina through which these enter.

When the periosteum is inflamed, through concussion or otherwise, it pours out lymph between it and the bone, which becomes organised, and converted into cartilage and then into bone. It is thus that splints and exostoses are formed; they generally appear in the middle of the fore leg, as that limb is most liable to concussion, the centre of gravity falling through it. The periosteum, owing to its inelasticity, is, when inflamed, the seat

of intense pain. Should it be stripped off any part, there is every probability of the bone dying and exfoliating.

It is most vascular near the joints, where it terminates by joining with the cartilage, or passes to the next bone, but it never proceeds over an articular surface. The internal or medullary cavities are lined by a more delicate vascular membrane, endosteum, or medullary membrane, which is prolonged into the cancelli, Haversian canals, and the cells of flat bones. It is very thin, contains little fibrous tissue, acting as a medium by which the inner portion of the bone and marrow are nourished; the nutrient arteries entering the shafts of long bones by distinct foramina, are chiefly distributed to it. The periosteum covering the bones of the skull is called the pericranium. *Marrow* is a yellow semi-fluid fat, contained in the medullary canal and cancelli; it fills up the cavities in the bone, and supports the blood-vessels. The large bones of birds contain air instead of marrow. In the horse and its allies, some of the bones of the head are filled with air. These cavities or sinuses freely communicate with the air passages. In an animal in perfect health there is a considerable amount of marrow, which can be drawn on in disease. In the bones of the fœtus there is no true marrow, only a transparent reddish fluid in the bodies of the vertebræ, ribs, and cranial segments. Bones are supplied by blood in three ways—by periosteum, small arteries entering the ends, and nutrient or medullary arteries. They are divided into long, flat, and irregular.

Long or cylindrical bones are found in the extremities, where they serve as levers for progression and pillars of support. Each is divisible into a centre or shaft, a superior and inferior extremity. The shaft is cylindrical, and consists of a compact shell of osseous tissue of varying thickness, which encloses the medullary canal. It is smallest in the centre, expanding towards the extremities, having a circular or prismoid form. When a long bone is placed nearly vertically under the body, its shaft approaches to the true cylinder. The internal wall being nearest

the centre of gravity, is the thickest. When obliquely placed, the thick portions of the shaft correspond with the line through which the centre of gravity passes, both in rest and motion. When the shaft is convex on one side, and concave on the other, the latter is the thickest, and may be elevated into a prominent ridge. Long bones are never straight; they may be twisted, as the humerus is, and are generally convex on the exposed surfaces, and pierced by the medullary foramen.

The extremities of long bones always exceed the shaft in circumference, and are remarkable for the irregularity of their outline. They are expanded and roughened, to afford surface for the attachment of tendons, muscles, and ligaments. Their protuberances also materially increase the mechanical power by serving as pulleys over which tendons play. The extremities are composed of cancellated, with a thin layer of compact tissue, the cancellated getting gradually less as they reach the centre of the shaft, its place being occupied by the medullary canal. While the extremities exceed the shaft in circumference, their weight is not relatively greater—their increase being due to a diffusion or expansion of material, not to an addition of substance. This arrangement will lighten and strengthen the bone, besides filling its cavities with a fatty buffer to obviate concussion. The hardest bone is a thin portion lying next the articular surface of long bones. It is non-vascular, insensible, and destitute of Haversian canals, only found when the bone is fully developed. It is called the non vascular tissue, and rests upon a series of arches formed by the cancelli. It is covered with cartilage, which in disease is abraded; the exposed bone by friction becomes polished and porcelainous. Unless at their articulating surfaces, the extremities are copiously pierced by foramina, which chiefly transmit veins and absorbents from the interior. They are always united to the next bone by ligaments, and enter into a synovial cavity.

Flat or tabular bones exist where mechanical action is at a minimum, and enclose cavities containing important organs. Thus,

the cranium protects the brain, the sternum, scapula, and, more especially in a cow, the ribs protect the respiratory organs. They are composed of two thin expanded plates of compact tissue, seldom arranged parallel to each other, and contain a cancellated structure between them. The internal is considerably harder than the external plate, but not so thick or tough, the outer being more elastic and not so liable to fracture. The connecting cancellated tissue is plentifully supplied with large blood-vessels; the tables, as in facial bones, may be widely separated with air cavities between them. They articulate variously; in the skull by sutures, or approximation of their serrated edges; by a dense fibro-cartilaginous or bony substance in the symphysis pubis; or by true synovial joints with long bones, when they are increased in thickness, contributing to the formation of the joint, as the scapula and ossa innominata.

Irregular bones include all which, in consequence of their length or breadth not exceeding their other dimensions, are not classed in the foregoing. They are found in those parts most subject to pressure, and where limited motion is demanded, as in the vertebral chain, knee, hock, and hoof. They possess many angles and indentations, with numerous surfaces for articulation and tendinous attachments, and consist of a thin, dense external case of compact tissue enclosing an internal cancellated structure. In proportion to their size, they present a much larger extent of articular surface and greater mechanical strength than any other class.

No bone is strictly geometrical, although, to a casual observer, some may appear so. This deviation is produced by certain eminences and depressions, a knowledge of which is the first requisite of osteology. Each *eminence* or projection is *articular* or *non-articular*, the former, usually found at the extremities of long bones, are clothed with cartilage, and enter into the formation of joints. Non-articular eminences exist extensively on the external surfaces of most bones, and receive the insertion of tendons, ligaments, or muscles. They are of

every variety of shape, size, and density, and named in accordance with their real or supposed resemblance to a known object,—prominent elevations being called *processes*, which are again distinguished according to their form or direction. A slender pointed elevation is called a *spine*; a small rough, round eminence, a *tubercle*; a broad one, a *tuberosity*; a prominent border is a *crest*; when continued above the surface, a *ridge*; a very prominent one becomes a *trochanter* or rounded articular eminence. At the superior extremity of a long bone there is a *capat* or head. The *cervix* or neck is the constricted portion on which the head is supported. A round articulating surface at the inferior extremity of a bone is termed a *condyle*; when it assumes a pulley-like form, a *trochlea*.

Depressions are also articular and non-articular, and vary in size, shape, and depth. They are lined with cartilage for the reception of articular eminences; a shallow one is a *glenoid*, a deep one a *cotyloid* cavity. Non-articular depressions serve as channels of transmission; they also give origin or insertion to muscles, tendons, or ligaments. An open excavation is a *fossa* or pit; an aperture or passage, with an external opening, is a *foramen*; an internal passage is a *canal*, *aqueduct*, or *meatus*; a small groove is a *fissure*; a depression on an articular head, a *sulcus*.

These irregularities of surface are more distinctly marked in the bones of the horse than in most other animals; their size is always proportioned to muscular development. Thus, they are best shown in well-bred hacks and old hunters; in heavy dray horses possessing maximum power, but minimum activity, they are small in proportion to the absolute size of the bones.

Although the bones of the foal, calf, and young of many other large quadrupeds, possess greater solidity at birth than those of the human infant, yet they all pass through certain progressive stages of development before arriving at that degree of density which they ultimately possess. The tracing of future bone is recognised about the seventh week of fœtal development in

local collections of soft, granular, gelatinous pulp, which becomes gradually flooded with nucleated cells, held together by an opaque, intercellular basis or matrix, which, with the cells equally distributed through it, forms temporary or hyaline cartilage—a material closely resembling ordinary gristle in its physical properties.

When bony development commences, that part of the cartilage about to become ossified is permeated by large channels for the passage of the blood-vessels which convey the bone-earth; and the cells, instead of being equally distributed throughout the matrix, become arranged into parallel groups, and increase by multiplication, those nearest the point of ossification enlarging. Matter, in the form of very minute granules, is now deposited in this column of intercellular or hyaline substance, as well as between each cell, denoting the commencement of what is termed ossification.

Ossification of the cell walls ensues, which is followed by the absorption of the osseous matter between the cells, converting what was a row of closed cells into a tube, which is a rudimentary Haversian canal, no trace being left of the nucleus of the original cartilage corpuscle; but there are numerous very minute reddish granules, which almost fill the cavity, and are concerned in the formation of blood-vessels, which now begin to appear. The ossific parieties of the cartilage cells lining the tube, at first thin, enlarge and thicken by successive layers of dense osseous matter, and thus produce the concentric laminæ, the lamina last formed pushing out the older, until what was the lining of the tube becomes the external lamina of a Haversian system, while the ossific matter which was deposited in the column of intercellular matter, becomes the connecting lamina between the Haversian cylinders. In long bones, this ossific process commences in the centre of the shaft, gradually spreading to the extremities, in which there are separate points of ossification; there are always three such points, one for the shaft, and one for each extremity. The shaft, when unconnected with its ex-

tremities, is called the diaphysis, the extremities, epiphyses. When any large process is superadded, as the trochanter of the femur, it possesses a distinct point of ossification, which is termed apophysis. As ossification commences in the shaft, there are, for some time after birth, intervening portions of unossified cartilage, marked by a deep ring in the dry long bones of young animals, which disappear at variable periods, the portions of bone hitherto imperfectly united becoming consolidated into one firm mass. The bone increases in length by four surfaces, which continue to grow until it is completed, when the ring fills up. Should the epiphysis unite through inflammation, the one bone is longer than another. The shaft of a long bone increases in circumference by deposits of new bone on its external surface beneath the periosteum, not from cartilage, but from membrane. In young periosteum there are two layers or strata—an outer, strong and fibrous, an inner, soft and full of bone cells, which is constantly renewed, so as to present a basis of animal matter, which ossifies round the blood vessels forming Haversian canals, which become Haversian systems. This goes on till the bone has reached its full development, when Haversian systems cease to be formed, and then, as a climax, the circumferential lamina is formed, and the medullary canal enlarges by internal absorption. In flat bones, ossification usually radiates from a centre, and is directed by a membrane investing each surface of the bone. Many of them possess numerous epiphyses. Ossification is completed in certain bones much earlier than in others, and at birth those which are required for support and progression are furthest advanced.

The bones of the cranial vault are developed, not from cartilage, but from membrane. In early fœtal life, the brain is covered by two membranes, closely united, viz., the pericranium and dura mater; between these, the bone laid down commencing by a radiating ossific centre. This is termed intra-membranous ossification, as opposed to intra cartilaginous.

It is interesting, while discussing ossification, to notice nature's

method of reuniting a fracture. An extravasation of blood takes place, followed by the pouring out of a thin semitransparent lymph round the fracture, which is changed into a substance resembling temporary cartilage. This is again converted into an ossuary-like material, called provisional callus, which acts as a bandage, keeping the parts *in situ*. A deposit of cartilage now takes place between the fractured ends, in the centre of which ossification originates, and the permanent callus is produced. When ossification is complete, and the bone reunited, the provisional callus is absorbed.

Cartilage is covered by a fibrous membrane, called the perichondrium, which afterwards becomes the periosteum, which is vascular; but until ossification begins, the cartilage is non-vascular.

The skeleton is composed of numerous individual bones, completely divested of soft parts, and collectively retained in relative position, so as to give the characteristic natural figure. A skeleton connected by ligaments is a natural, articulated by wires or screws an artificial, preparation.

It is described as the trunk or central part, which comprises the spinal or vertebral column, chest, and pelvis; the head, consisting of the cranium or vaulted arch, which covers the brain and face, and protects the principal organs of sense; and the extremities or locomotive organs, which, in quadrupeds, form two anterior and two posterior limbs or legs.

As it has two sides or halves, the majority of the bones exist in pairs. There is, however, a central chain, formed by vertebræ and mesial segments of the head, which consist of single bones. These extend the whole length of the trunk, and unite its lateral halves.

Anatomists differ as to the number of bones composing the skeleton. This depends on some enumerating all ossific bodies, as teeth and sesamoids, which others eliminate. Some, again, regard certain cranial bones, as the frontal in the horse, as single; others, as dual. It is better to enumerate as single bones all

naturally distinct pieces of developed osseous tissue, the teeth included.

The number of such separate bones in the horse are 97 pairs, and 58 single bones; in all, 252.

In speaking of the anatomical position of a bone, we do so with reference to its locality, keeping in view its relation to other structures. In order to render description of situation still more exact, continual reference is made to imaginary lines or planes. The skeleton of the quadruped, as well as man, is, in an anatomical sense, viewed from before; but man, being erect, with the long axis of his body in a vertical position, whilst that of quadrupeds occupies a horizontal plane, corresponding organs do not present themselves to observation from the same aspect. With reference to quadrupeds, these imaginary planes are supposed to lie as follows:—A longitudinal median vertical plane descends through the centre of the head, vertebral chain, and trunk, mid way between the extremities, to the ground, dividing the body into two exact halves; a right and left lateral vertical plane passes parallel to the former, but external to the body; an anterior vertical plane passes in front, a posterior vertical behind; a superior horizontal plane lies above the body, between the anterior and posterior vertical planes; while parallel with the superior is an inferior horizontal plane, running under the feet, between the anterior and posterior vertical. These apply to any region, as well as to the entire body. The external surface of an organ or region is that which faces the lateral plane on the side where the organ is situated. The internal faces the median plane of the body, the anterior surface the anterior vertical, the posterior surface the posterior vertical plane, the superior and inferior surfaces are those facing their respective superior and inferior planes.

Modifications of these terms are used when it is requisite to point out the precise situation, or even the position, of an organ itself. For example, take the fore-leg, and suppose it encompassed by the planes *ut supra*. If we wish to describe the situation of

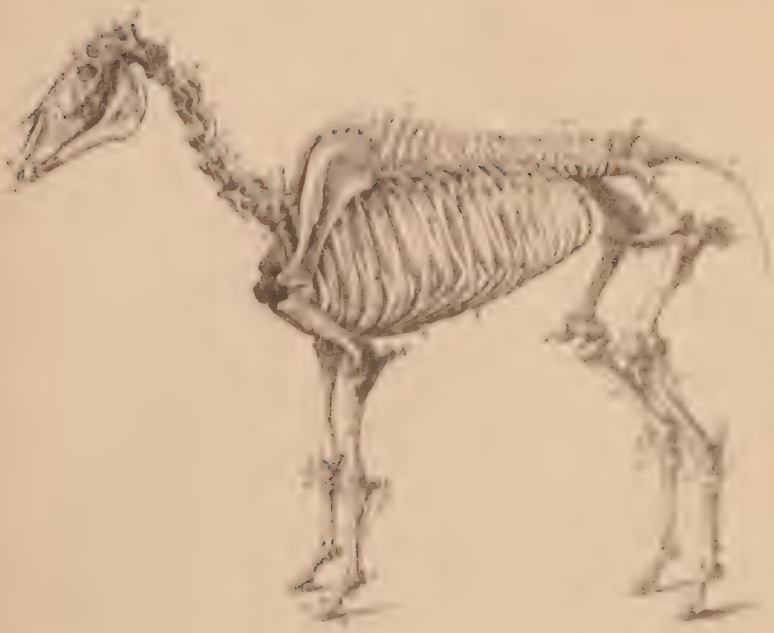

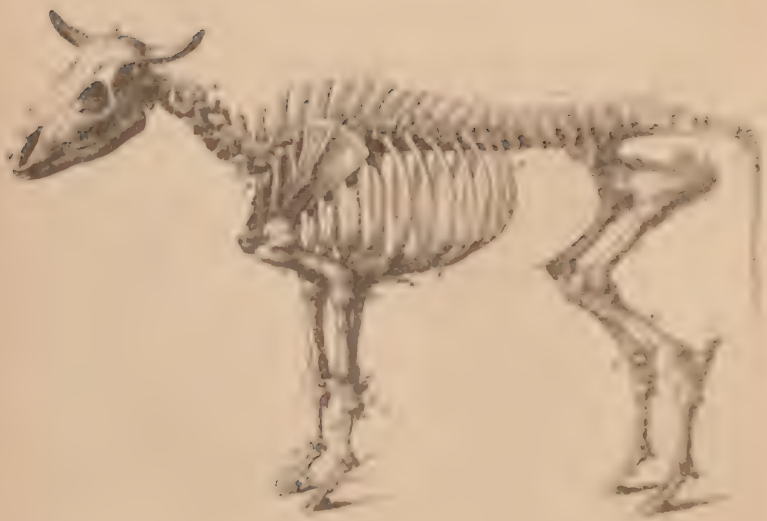

PLATE I.

FIG. 1.—SKELETON OF HORSE.

I. THE BONES OF THE HEAD ARE DIVIDED INTO THOSE OF THE CRANIUM AND FACE.

A. *Bones of the Cranium.*

	No.
Occipital bone, *a*,	1
Wormian bone, *b*,	1
Parietal bones, *c*,	2
Frontal bone, *d*,	2
Temporal bones, *e*,	2
Auditory ossicles—	
Malleus,	2
Incus,	2
Stapes,	2
Lenticular bone,	2
Sphenoid bone,	1
Ethmoid bone,	1

B. *Bones of the Face.*

Nasal bones, *h*,	2
Lachrymal bones, *g*,	2
Malar bone, *f*,	2
Superior maxillary bones, *i*,	2
Intermaxillary bones, *k*,	2
Palate bones,	2
Pterygoid bones,	2
Vomer,	1
Turbinated bones,	4
Inferior maxillary bone, *l*,	11
Hyoid bone,	1
Teeth—	
Incisor teeth, *m*,	12
Canine teeth, *n*,	4
Molar teeth, *o*,	24

II. BONES OF THE TRUNK.

A. *Bones of the Vertebral Column.*

Cervical vertebræ, *p*, *v*,	7
Dorsal vertebræ, *w*,	18
Lumbar vertebræ, *x*,	6
Sacrum, *y*,	1
Coccygeal vertebræ, *z*,	18

B. *Bones of the Chest.*

Ribs, *a'*-*a'*,	36
Sternum,*	1

C. *Bones of the Pelvis.*

Iliac bone, *b'*,	2
Pubic bone, *c'*,	2
Ischial bone, *d'*,	2

III. BONES OF THE LIMBS.

A. *Bones of the Fore Limb.*

Scapula, *e'*,	2
Humerus, *f'*,	2
Radius, *g'*,	2
Ulna, *h'*,	2
Carpal bones—	
Pisiform bone, *i'*,	2
Cuneiform bone, *k'*,	2
Semi-lunar bone, *l'*,	2
Scaphoid bone, *m'*,	2
Unciform bone, *n'*,	2
Os magnum, *o'*,	2
Trapezoid bone, *p'*,	2
Trapezium, *q'*,	2
Cannon and large metacarpal bone, *r'*,	2
Small metacarpal (splint) bones, *s'*,	4
Sesamoid bones, *t'*,	4
1st phalanx (pastern bone), *u'*,	2
2d phalanx (coronet bone), *v'*,	2
3d phalanx (coffin bone), *w'*,	2
Navicular (shuttle) bone, *x'*,	2

B. *Bones of Posterior Limb.*

Thigh bones, *y'*,	2
Patella, *z'*,	2
Tibia, *a''*,	2
Fibula, *b''*,	2
Tarsal bones—	
Os calcis, *c''*,	2
Astragalus, *d''*,	2
Cuboid bone, *e''*,	2
Large cuneiform bone, *f''*,	2
Middle cuneiform bone, *g''*,	2
Small cuneiform bone, *h''*,	2
Large metacarpal (cannon) bone,	2
Small metacarpal (splint) bone,	4
Sesamoid bones,	4
1st phalanx (pastern bone),	2
2d phalanx (coronet bone),	2
3d phalanx (coffin bone),	2
Navicular (shuttle) bone,	2

Entire number of Bones in Skeleton of Horse—252. 262

FIG. 2.—SKELETON OF OX.

I. BONES OF HEAD.

A. *Bones of Cranium.*

Occipital bone,	1
Parietal bone, *b*,	2
Frontal bones, *a*,	2
Temporal bones, *c*,	2

Bones of Cranium—cont.

Auditory ossicles—	
Malleus,	2
Incus,	2
Stapes,	2
Lenticular bone,	2
Sphenoid bone,	1
Ethmoid bone,	1

B. Bones of the Face.

	No.
Nasal bones, *h*,	2
Lachrymal bones, *e*,	2
Malar bones, *d*,	2
Superior maxillary bones, *f*,	2
Intermaxillary bones, *g*,	2
Palate bones,	2
Pterygoid bones,	2
Vomer,	1
Turbinated bones,	4
Inferior maxillary bone, *i*,	1
Hyoid bone,	1
Teeth—	
Incisor teeth,	8
Molar teeth,	24

II. BONES OF TRUNK.

A. Bones of Vertebral Column.

Cervical vertebræ, *k*,	7
Dorsal vertebræ, *l*,	13
Lumbar vertebræ, *m*,	6
Sacrum, *n*,	1
Caudal vertebræ, *o*,	20

The GOAT has only 9.

B. Bones of Chest.

Ribs, *p-p*,	26
Sternum,*	1

C. Bones of Pelvis.

Iliac bones, *q*,	2
Pubic bones, *r*,	2
Ischial bones, *s*,	2

III. BONES OF THE LIMBS.

A. Bones of the Fore Limb.

Scapula, *t*,	2
Humerus, *u*,	2
Radius, *v*,	2
Ulna, *w*,	2

Bones of the Fore Limb—cont.

	No.
Bones of carpus—	
Pisiform bones, *x*,	2
Cuneiform bones, *y*,	2
Semi-lunar bones, *z*,	2
Scaphoid bones, *a'*,	2
Uneiform bones, *b'*,	2
Trapezoid bones, *c'*,	2
Large metacarpal bones, *d'*,	2
Small metacarpal bones, *e'*,	2
Sesamoid bones, *f'*,	8
1st phalanx, *g'*,	4
2d phalanx, *h'*,	4
3d phalanx, *i'*,	4
Navicular (shuttle) bone, *k'*,	4

B. Bones of Hind Limb.

Femur, *l'*,	2
Patella, *m'*,	2
Tibia and fibula (united), *n'*,	2
Tarsal bones—	
Crown-formed bones, *o'*,	2
Os calcis, *p'*,	2
Astragalus, *q'*,	2
Navicular bone, *r'*,	2
Third cuneiform bone, *s'*,	2
First cuneiform bone, *t'*,	2
Metatarsal bones,	2
Upper sesamoid bones, *u'*,	2
Lower sesamoid bones,	4
1st phalanx (pastern bones),	2
2d phalanges,	4
3d phalanges,	4
Navicular (shuttle) bones,	4

IV. BONES WHICH ARE NOT CONNECTED WITH THE SKELETON.

Heart bones,	2

Entire number of Bones in Skeleton of Ox—246.

any object on the upper part of its lateral region, the term supero-lateral would be used; if the object were situated at the lower lateral part, then infero-lateral. The same combined modifications of terms is, of course, applicable to the anterior and posterior surfaces. Supero-anterior implies superior part of the anterior region; antero-superior implies anterior part of the superior region of the body. Vessels, bones, &c., are frequently divided into two or more parts. Thus we allude to the superior, middle, inferior, half or third of an object.

Vertebral Column.

The *vertebral* or *spinal column* may be considered the foundation of the skeleton, from which all other parts proceed. It consists of a series of single bones, termed vertebræ, united by an elastic substance, and always manifests a succession of arches; thus, in the horse, the neck, back, and rump are arched, though the loins are nearly straight.

Vertebræ may be divided into true and false: true vertebræ possessing certain typical parts, which they retain throughout the life of the animal, and never, in health, unite by ossification; while false vertebræ do not possess all the characters of true, and may become united by ossification. In the higher mammalia, the true vertebræ constitute the spine proper.

The vertebral chain may be divided into four regions:—the cervical, the dorsal, the lumbar, and the pelvic or sacro-coccygeal; and, while all possess certain points of conformation in common, special peculiarities prominently distinguish the bones of any one region from those of the others.

A *true vertebra* consists of a body, an arch, notches, and spinous, transverse and articular processes. The *body* is the solid block on which all the other parts are built, and which, in quadrupeds, lies below the spinal canal. Its anterior end is convex, and its posterior correspondingly concave, both being discs of compact bone roughened for the attachment of the soft

inter-vertebral substance. Its upper or spinal surface is flattened or slightly concave, its inferior surface being convex, and often terminating in a spinous process or prominent ridge.

The *arch* or *ring* rises from the superior lateral surfaces of the body by two processes of bone termed *pedicles*, from each of which a plate of bone, *the lamina*, expands and passes inwards. The union of the laminæ in the mesian line completes the arch which encloses the spinal foramen.

The *notches* are excavations in the anterior and posterior surfaces of each pedicle, so placed that when the vertebræ are *in situ* the notch in the posterior part of one pedicle corresponds with that in the anterior of the next, and forms a large opening, called the hole of conjugation or inter vertebral foramen, which leads to the spinal canal, and gives passage to the spinal nerves and blood vessels.

Each true vertebra, with the exception of the two anterior cervical, has four *oblique* or *articular processes* on the superior and lateral parts of the arch. The faces of the anterior of these processes look upwards and inwards, while those of the posterior look downwards and outwards. As their name implies, they articulate and form true joints with the corresponding processes of adjacent vertebræ.

The *transverse processes*, one on each side, spring from the sides of the body and pedicle, and consist of projections varying much in size and shape in different regions—their bulk being determined by the extent of their muscular relations.

The *spinous processes* are superior and inferior. The *superior*, arising from and surmounting the centres of the arches, are sometimes of great size and strength, but vary much in development in the different regions of the same animal. The *inferior* are for the most part rudimentary, and can scarcely be said to exist except in the cervical region, where they project from the inferior central line of the bodies.

The bodies of the vertebræ, placed in natural apposition, form a central bony column, to which arches and processes are attached; the arches, with their connecting ligaments, form a cavity, the

spinal canal, which extends from the head to the tail, and contains the spinal cord, with its membranes and blood-vessels; the articular processes strengthen the connections of the vertebræ and facilitate their motions; and the spinous and transverse processes are levers into which muscles are inserted in order to execute various movements of the trunk—their development having great influence on the physical conformation and capabilities of the animal.

The *false vertebræ* are found in the sacrum, which consists of vertebral segments united by the ossification of their spinous and transverse processes, and in the coccygeal bones, which are merely rudimentary or imperfectly developed vertebræ.

The Cervical Vertebræ (Pl. I. fig. 1, *p*, *v*).—These are seven in number in all mammalia, with the exceptions of the three-toed sloth, which has nine, and the sea-cow, which has six; they are named in order from the head, the first receiving the additional name of *atlas*, and the second of *axis* or *vertebra dentata*. These, with the seventh, differ from the other four which are essentially alike.

The *bodies* of the cervical vertebræ, larger and longer than those of any other true vertebræ, frequently measuring upwards of four inches in length, are quadrangular in shape, their anterior extremity or head being convex and heart-shaped, with the apex downwards, and projecting laterally and inferiorly. As the cervical vertebræ execute more extensive and a greater variety of motions, the ends of the opposing vertebræ form more perfect ball and socket joints than are found in other parts of the column. The *superior surface* is flattened, and presents, close to the pedicle on each side, a distinct furrow, which contains the spinal veins; these lateral furrows are united by means of a central transverse furrow, and partly covered by a thin bony plate, to which the superior common ligament is attached. The *inferior surface* presents a longitudinal process or ridge, the inferior spinous process, which, rising from a narrow ridge anteriorly, increases in size as it approaches the posterior end of

the bone, where it terminates in a large projecting tuberosity, which gives attachment to the longus colli muscle. The *lateral surfaces* of the body, above the spines, are flattened, and occasionally excavated for muscular attachment.

The *superior spinous processes* are merely rudimentary, and rise from the centre of the quadrilateral space between the oblique processes. They are bifid posteriorly, the ligamentum nuchæ and spinalis colli muscle being placed in the bifurcation.

The *transverse processes*, large, broad, short, very strong and irregular in shape, arise by plates of bone which, passing directly outwards, divide into two parts—one projecting anteriorly and inferiorly, and the other posteriorly and inferiorly. They increase in size as they extend backwards, and all of them, except the seventh, are pierced by the vertebral foramen, through which pass the vertebral artery and vein. These processes give attachment to the splenius, longus colli, transversalis colli, and rectus capitis anticus major muscles, and act partly as levers to raise the head and neck.

The *articular processes*, larger than in any other region, have flattened oval surfaces; the anterior two look upwards and inwards, while the posterior look downwards and outwards. They overlap each other, and form true synovial joints. The articular processes of the posterior five cervical vertebræ give attachment to the complexus major, trachelo mastoideus and spinalis colli muscles.

The *arches*, stronger than in any other region, enclose a spinal canal, which progressively increases in size in the direction of the dorsal vertebræ, its vertical diameter being greatest. The *notches* of the three posterior cervical vertebræ are also larger than any found elsewhere.

The first, second, sixth, and seventh cervical vertebræ having peculiar conformations, require special notice.

The *First* or *Atlas* (Pl. 1. fig. 1, *p*) (so called because in human anatomy it supports the head, in the domestic animals the head is suspended from it,) presents no well-defined body, but consists of a strong ring of bone, the superior surface of which is convex, with

a slight longitudinal elevation in the mesian line, from which the *alæ* slope downwards and backwards. These are large, flat transverse processes, wider than the transverse processes of any other cervical or dorsal vertebra, which terminate in rough convex margins, and may be plainly felt under the skin in the living animal. They act as levers for turning the head, giving insertion to portions of the levator humeri, splenius, trachelo mastoideus, and obliquus capitis inferior muscles, and are always largely developed in flesh-eating animals.

The *inferior surface* of the atlas is convex, and presents posteriorly a considerable short, thick obtuse eminence, which represents the inferior spine. This is the *tubercle* of the atlas to which the tendon of the longus colli muscle is attached. On each side of this central convexity, a large concave space occupies the whole of the inferior surface of each ala. The *anterior surface* looks towards the cranium, and presents two notches and two articular depressions. The notches are of great size, and contain the superior and inferior suspensory ligaments—one being above, and the other below, the spinal canal. The articular cavities receive the condyles of the occipital bone, and are constructed of two superior and two inferior smooth articular surfaces. The inferior, which take the place of the convex head of the other vertebræ, are concave, looking upwards and inwards; while the superior, nearly flat, look downwards, and represent the oblique processes of the other vertebræ. Prominent bony ridges, in which is inserted the inner layer of the capsular ligaments connecting the atlas and occipital condyles, separate these surfaces from the spinal canal. The *posterior surface*, which looks towards the axis, presents a somewhat triangular outline. Its inferior margin is excavated to receive the odontoid process of the second vertebra; while the superior is thin and roughened for ligamentous insertion, and, on each side, a broad slightly convex articular surface represents the posterior oblique processess, and articulates with the axis. This surface is bounded externally by a ridge, which gives insertion to the capsular liga-

ment; and internally it is separated by a similar ridge from the spinal canal.

The spinal foramen of the atlas is very large, in order that the spinal cord may be preserved from injury during the extensive motions which take place between the head and neck, and having, in addition to the cord and its ligaments, to transmit the odontoid ligaments to the occiput. Its floor is divided by a transverse ridge into two portions—the anterior of which is roughened for the implantation of ligaments; and the posterior, which represents the concavity in the posterior part of the bodies of other vertebræ, smooth and excavated for the articulation of the odontoid process. Its roof is smooth, and penetrated by two foramina for the passage of an artery and nerves, and its sides have each a deep excavation in which a venous sinus is lodged. A foramen from this excavation opens on the inferior surface of the ala, and transmits a vein from the sinus.

The atlas has three articular processes,—two for the occipital condyles, and one for the axis,—all of which form true synovial joints, the atlas being the only vertebra possessing none but synovial articulations.

Each ala is pierced by three foramina. The posterior, which is largest, and corresponds to the vertebral foramina of the others, gives passage to the vertebral artery and retrograde branch of the occipital. The two anterior are joined by a short, deep canal, which runs in a direction from before slightly backwards, the external giving passage to the occipital artery, vein, and nerve; and the internal, which leaves the canal and passes through the ring into the spinal foramen, taking the place of the intervertebral foramen. Through it the cerebro-spinal branch of the occipital, which goes to form the basilar artery, and the first pair of spinal nerves, find their way.

The *Second Vertebra*, called also the *Axis* (Pl. I. fig. 1, *q*), because the head turns freely upon it, and *vertebra dentata*, from a process which, in the human subject, resembles a tooth, possesses a longer body than any other true vertebra, and, instead of being rounded

anteriorly, has a peculiar projection, the odontoid process, which fits into the cavity in the ring of the atlas, and round which the head and atlas rotate. The under surface of this process is smooth and rounded, and the upper roughened and excavated, for the insertion of the odontoid ligaments. Laterally, it terminates in a broad, oval, somewhat convex surface, which represents the oblique processes, and articulates with the posterior surface of the atlas; these articular shoulders being bounded by a sharp ridge, into which the capsular ligament is inserted.

The *superior spinous process* of the axis springs from a very strong arch, and is nearly as long as the body. It is convex, and consists of lateral halves, united anteriorly into a strong rough crest, but divided posteriorly into distinct spines, which terminate in separate articular processes.

The *inferior spine* arises from a notch in the inferior part of the odontoid process; it is broad and rough anteriorly, and runs into a sharp spine, which terminates in a roughened tubercle posteriorly.

The *transverse processes*, the smallest in the cervical region, are single, and project outwards and backwards. They are pierced by very small vertebral foramina. The *spinal foramen* is nearly semicircular, and, instead of *notches*, there are two oval foramina anteriorly for the passage of the spinal nerves. The posterior parts of the body and arch do not differ from the other cervical vertebræ.

As the atlas and axis do not articulate above the spinal canal, there is a considerable space between the bones covered by ligament merely; it is one of the situations where the operation of pithing is performed.

The *Sixth vertebra* (Pl. I. fig. 1, *u*) has a shorter body than those anterior to it, and is destitute of an inferior spine. Its transverse processes consist of three lateral divisions, and its vertebral foramina, notches, and spinal foramen are of great size.

The *Seventh vertebra* (Pl. I. fig. 1, *v*), the shortest of the series, is very strong, and has an elevated superior spinous process,

pointing upwards and forwards, but scarcely the trace of an inferior one. Its oblique processes resemble the four preceding; its transverse processes are small, and not usually pierced by the vertebral foramina, and its notches and spinal foramen larger than in any other vertebra, except the first. On each side of its body, posteriorly, it presents a depression which, with a corresponding depression on the first dorsal, forms a cup for the articulation of the first rib. It possesses the usual number of articulations, and, altogether, closely approaches to the shape of the first dorsal.

Viewed *in situ*, it is seen that the transverse processes of the three central cervical vertebræ are largest and strongest, with the exception of the atlas, and can be plainly detected under the investing muscles in the living animal; and that the bodies progressively diminish in length, and increase in breadth and depth from the second downwards.

The Dorsal Vertebræ (Pl. I. fig. 1, *a*).—These vertebræ, generally eighteen, sometimes nineteen, in number, always corresponding in number with the ribs, are the principal agents in supporting weight, and extend over the whole region of the chest. Their *bodies*, the smallest of the true vertebræ, are short, thick, and somewhat semicircular in form, presenting a middle ridge along the under surface of each, to which the inferior common ligament is attached. Above this ridge are flattened spaces perforated by foramina, through which veins pass from the spinal canal to the vena azygos. The superior surface of the body, which forms the floor of the spinal canal, is a flattened quadrilateral space, presenting longitudinal furrows for the spinal veins, and a central transverse one, in general, partially covered by a bony plate. These transverse furrows receive the spinal veins which open into venous trunks in the bone, and subsequently pass out by the foramina on the sides. The *anterior extremity* presents a slightly convex head, on the superior and lateral aspect of which is a depression corresponding with another on the posterior extremity of the vertebra in front, so that together they form a

cup-shaped cavity for the articulation of a rib—each vertebra articulating with one-half of the head of the rib. The *posterior extremity* is concave, to articulate with the contiguous bone. The *transverse processes*, rising from the sides of the arches, are small, and pass upwards, outwards, and slightly forwards. Superiorly and anteriorly they are roughened for muscular attachment, and, at their posterior inferior part, present a flat, smooth surface for articulating with the tubercles of opposing ribs.

The *superior spinous processes*, larger than in any other region, vary much in size, shape, and direction; the first twelve being directed backwards, the next three nearly upright, and the last three forwards. Their length gradually increases to the fifth, which is largest, and then decreases to the fourteenth, which is generally shorter than those behind it. The first is small and sharp, and the second, which appears to be abruptly bent on the third, very strong, and terminating in a broad, rough superior extremity. The summits of the next six or seven are flattened, roughened, and expanded laterally, assuming a bifid appearance, to give greater surface for the attachment of muscles and the ligamentum nuchæ. Their lateral surfaces are convex and slightly roughened, the anterior borders being thin and serrated, and the posterior, of the higher spines especially, broad and concave, becoming cleft as they approach the oblique processes.

The *oblique processes* are small, being exceeded in height by the transverse; the anterior two, situated on the posterior part of the arch, look upwards, and the posterior two, placed somewhat within the spinal canal, underneath the spinous process, look downwards.

The *pedicles* are short and strong, and, with the exception of the anterior four or five, possess notches on their posterior surfaces only. Those at the posterior end have foramina in lieu of notches.

The *arch*, and consequently the spinal canal, is small, the laminæ passing nearly directly inwards from the pedicle.

An ordinary dorsal vertebra has twelve articular surfaces, viz., three anterior and three posterior, as in the cervical, and three

at each side. Of the latter, two are for the heads, and one for the tubercle of the ribs. The depressions for the heads of the ribs are deepest between the anterior vertebræ, and gradually grow shallower, in the two last becoming continuous with that for the costal tubercle. The eighteenth, having connections with but one rib on each side, has eight articulating surfaces only.

Viewing the dorsal vertebræ in connection, it is seen that the spines diminish from the fifth backwards, and the vertebræ themselves grow narrower. The first exhibits some of the characters of a cervical vertebra, and the second has a short body, with its transverse and anterior oblique processes formed on the same bony projection, and its spinous process, short and convex anteriorly, more bent than any other in the vertebral chain.

The first thirteen form the withers, and their height affording a larger surface for muscular attachment, is a great point in horses, such as hacks and hunters, where high action is a desideratum—a horse with low withers being always a low goer. High withers are not necessary, however, in horses used for carrying weights, such as cart-horses, or in those required for speed alone, since some of the best race-horses have low withers.

The Lumbar Vertebræ (Pl. I. fig. 1, *x*).—These, forming the region of the loins, are shorter in the horse, in proportion to his relative size, than in other animals. Their number is six usually, sometimes five, in the horse; six in the mule, and five in the ass. Their *bodies*, intermediate in length between the cervical and the dorsal, are thick and strong, the three anterior being flattened superiorly and laterally, and possessing a strongly-developed mesian ridge; and the three posterior convex laterally, and flattened above and below. More motion being required in the loins than in the back, the anterior extremities of the bodies of the lumbar vertebræ are more convex, and the posterior extremities more concave than those in the dorsal region. The *arches* enclose a large semicircular spinal canal, and with one or two exceptions possess both anterior and posterior notches.

The *spinous processes* are strong, broad, and flattened laterally.

They incline slightly forwards, are about the same length as the dorsal, and have sharp anterior and posterior edges and rough expanded extremities. They increase slightly in height, and diminish in strength as they proceed backwards. The transverse processes, longer than the corresponding processes in any other region, are broad and flat with rounded extremities, and extend nearly horizontally from the bodies. The central are the largest; the two first incline a little backwards, and the two last slightly backwards. The first three of these processes do not touch, but the last three articulate with each other, and sometimes, in advanced age, become united by ossification. In young animals, however, these articulating processes have no existence, and it is in adult and old animals accustomed to bear weight that their development is greatest.

The *oblique processes* project further from the arch than those of the dorsal region; the anterior, the articular surfaces of which are concave, and look inwards, being wider apart than the posterior, which are concave, and look downwards.

All the lumbar vertebræ have the six usual articulations, the fourth having in addition one on each posterior border of its transverse processes; and the fifth and sixth, one on each border of these processes, or ten in all.

The False Vertebræ.

The Sacrum (Pl. I. fig. 1, *y*) (sacred or rump-bone) is a single, irregular, triangular-shaped bone, consisting of five false vertebræ united in the young animal by fibro-cartilage, and in the adult by ossification, which contains the continuation of the spinal canal, and forms the roof of the pelvis. Its direction varies somewhat in horses of various breeds. In lightly made, highly-bred, and well-formed animals, its long axis is placed in a nearly horizontal line; while in heavier built and more coarsely bred horses its coccygeal extremity is often considerably lower than the other, thus giving a drooping appearance to the line of continuity be-

tween it and the coccyx. It presents for consideration superior and inferior surfaces, two lateral borders, and anterior and posterior extremities.

The *superior surface* is irregularly convex, with the flat-topped spines of the rudimentary vertebræ running along its centre decreasing in height, but increasing in breadth as they extend backwards. In a groove at their base, opposite the interspinous spaces, are the four superior sacral foramina which give exit to the superior branches of the sacral nerves. An irregularly elevated ridge, external to the grooves, marks the division between the superior and inferior surfaces of the bone.

The *inferior* or *pelvic surface* is smooth and rather concave; at its anterior end is a transverse elevation, the promontory of the sacrum, and crossing it are four slightly elevated lines, which show the connections between the original segments of the bone. Between these lines, close to the lateral borders, on each side, are the four foramina through which pass the inferior branches of the sacral nerves, and at the end two notches, which correspond with similar notches in the last lumbar and first sacral bones, and form the foramina, through which the last lumbar and the fifth sacral nerves find their way.

The *anterior extremity* or *base*, which is extremely irregular and almost entirely articular, is divided into a central and two lateral parts. The central part, oval and convex, articulates with the last lumbar. Above it is the triangular spinal canal, surmounted by the articular processes. The lateral parts are the thick expanded transverse processes which contain broad articular eminences, and terminate in sharpened extremities.

The *lateral borders* or *sides* are divided into anterior and posterior portions. The anterior portion is roughened for fibro-ligamentous attachment to the ilium under which it lies; the posterior, separated from the other by the notch through which the gluteal vessels and nerves pass, and roughened for the attachment of the sacro-sciatic ligaments, terminates in an expanded transverse process, the sacral cornu.

The *posterior extremity* or *apex* presents the small triangular sacral canal in its centre, with the last spinous process above it; the round, flat surface which articulates with the first bone of the coccyx below; and the notches, and, still further outwards, the sacral cornu on its sides.

The sacrum has five articular surfaces on its base, one on each side, and one on its apex. Its spinal canal is triangular in shape, and rapidly decreases in size from before backwards.

The Coccyx (Pl. I. fig. 1, *z*).—The *coccygeal*, or *caudal vertebræ*, are false vertebræ, varying in number between thirteen and twenty. In conformation, they are the most rudimentary of all the bones in the spinal column; their bodies are oblong, mostly constricted in the centre, and expanded where they articulate with one another. Those of the four or five anterior are slightly flattened above, hollowed longitudinally below, and possess incomplete arches and imperfectly developed processes. The remainder possess nothing but bodies which diminish in size as they extend backwards.

There is no perfectly complete spinal canal in the caudal region.

The Pelvis.

The *pelvis* is the incomplete bony basin composed of the sacrum, the coccyx and the ossa innominata. It is always much smaller proportionally in the lower animals than in man, where, especially in the female, it is large and well developed, and is destitute of that peculiar basin-like form so characteristic of the human body, and identified with an erect posture of body.

The Ossa innominata are two flat, but somewhat irregularly shaped bones, which form the sides, floor, and part of the roof of the pelvis. Above, they are connected with the sacrum, and below, united in the mesian line by fibro-cartilage in the young animal, and by ossification in the adult. In the young animal, and especially in the fœtus, the os innominatum consists of three parts, which retain their names of ilium, ischium, and pubis, even

after ossification is complete. They all three meet in the acetabulum.

The Ilium (Pl. I. fig. 1, *b'*), the largest and most symmetrical of the three, and situated partly upon the sacrum with which it articulates, is flat and triangular in shape, its extreme outer angle being one of the most prominent points of the animal, and forming the projection commonly called the "point of the hip." It presents for consideration two surfaces, three borders, and three angles or spinous processes.

The *external surface* is concave at its upper part, and marked by elevated lines for the attachment of the gluteus maximus. Lower down it becomes convex and narrow, forming the upper part of a strong three sided piece of bone called the shaft of the ilium. As it approaches the acetabulum the shaft again slightly expands, and becomes roughened for the attachment of the gluteus internus and outer head of the rectus muscles. This surface terminates in an obtuse angle, the outer side of which, waving and projecting, forms a strong anterior margin for the acetabulum; and the inner side, surmounting this cavity, becomes the line of junction between the ilium and the ischium.

The *internal surface* is slightly convex, its upper portion consisting of two parts—an external smooth one corresponding to the iliac fossa in man; and an inner, which rests on the sacrum, and gives attachment to the sacro-sciatic ligaments. The lower portion is divided by the ilio-pectineal line into an outer and an inner part. The psoas parvus and sartorius are inserted into a rough eminence near the middle of this line. The outer part, or false pelvis, is flat, and occupied by the iliacus. It contains the nutrient foramen at its upper part, and, in front of the acetabulum, a depression for the inner head of the rectus femoris. Below this depression is the ilio-pectineal eminence, which marks the junction of the ilium and the ischium. The inner part, or true pelvis, is smooth, concave, and grooved for the obturator vessels.

The *anterior border*, or *crest of the ilium*, lies above the

sacral transverse process. It is concave above, convex below, thin in its middle, and roughened for the insertion of the longissimus dorsi and other muscles. Internally, it terminates in a rounded eminence, the *posterior iliac spine*, which rises above the last lumbar and first sacral spines, and forms the highest part of the croup. Externally, or anteriorly, it terminates in four eminences supported on a thick, strong, projecting bony plate. The upper two form the *anterior superior iliac spine*, and the lower two the *anterior inferior spine*. These spinous processes give attachment to oblique and transverse abdominal muscles and others connected with the back, loins, and quarters. They are more developed in some horses than in others, and occasionally project so far as to constitute the condition termed "ragged hips."

The *inferior* or *internal border* extends from the posterior spine to the ischium. It is sharp and thin above, and becomes thicker, presenting, immediately above the acetabulum, a roughened ridge, the *sciatic* or *superior ischiatic spine* (half of it being on the ischium), to which a large part of the sacro-sciatic ligament is attached.

The Ischium (Pl. I. fig. 1, *d'*), intermediate in size between the ilium and the pubis, is a flat, irregularly quadrilateral bone, which extends from the acetabulum, and forms the posterior lateral and posterior inferior parts of the pelvis. It presents a body, a shaft, and a ramus.

The *shaft*, on which is the half of the sciatic spine, joins the lium in the cotyloid cavity. It is rounded, and below the spine has a polished surface, over which the obturator internus and pyriformis muscles pass. It forms the external lateral part of the boundary of the foramen ovale.

The *body*, placed nearly horizontal, is flat and smooth, and forms the posterior boundary of the foramen ovale. Internally, it is rough, and joins its fellow of the opposite side, forming the symphysis ischii; posteriorly, it is roughened for the attachment of muscles, and possesses on its external part a prominent pro-

jection, the *tuberosity of the ischium*, to which several muscles are attached. The thick ridge or spine, descending from the tuberosity, is the *inferior ischiatic spine*, which, in the male, supports the crura of the penis and its erector muscles.

The *ramus*, not well developed in the horse, is the small branch which joins the pubis, and forms part of the internal boundary of the foramen ovale.

The Pubis (Pl. I. fig. 1, *c'*), the smallest division of the os innominatum, is very irregular in shape, and forms the anterior inferior part of the pelvis. It possesses a body and a ramus.

The *body* descends from the acetabulum to the symphysis. Its superior surface is considerably excavated to receive the urinary bladder, and its inferior surface is convex, and obliquely crossed by a deep groove, which contains the pubio-femoral ligament. The *crest* occupies the anterior border, which terminates in the angle at the symphysis. The posterior border extends to the ramus, and forms the anterior margin of the foramen ovale; at its junction with the ischium it is crossed by a groove for the obturator vessels. The extremity, which joins the ilium and the ischium, is abruptly excavated to form the cotyloid notch.

The *ramus* is the flattened portion which projects posteriorly, joins the ramus of the ischium, and forms part of the boundary of the foramen ovale, and part of the symphysis pubis.

The *cotyloid cavity* or *acetabulum* is situated on the external lateral aspect of the pelvis, where the three pieces of the os innominatum unite. It receives the head of the thigh-bone, and is deeper than any other articular depression in the body, though, relatively, it is much less capacious in the horse and in quadrupeds generally than in man. It is semicircular in outline, and, except at its inferior median part, is surmounted by a prominent lip of bone, which becomes thin and slightly roughened at its free surface for muscular and ligamentous attachment. Its inferior border presents a large notch, the *cotyloid notch*, formed in the pubis alone. This notch, con-

tinued upwards nearly two-thirds across the vertical diameter of the articulation, gives secure attachment to the round ligament (ligamentum teres), which mainly occupies it, and passage to the transverse ligament. Although the cotyloid cavity is formed by the three segments of the os innominatum, the ilium and the ischium are generally the only parts which enter into its articular surface — the pubis, occupied by the notch, and giving attachment to the round ligament, having frequently no covering of articular cartilage.

The *obturator*, *thyroid*, or *foramen ovale*, the largest foramen in the body, is oval in outline, its long diameter being directed downwards, backwards, and inwards. It is formed entirely by the pubis and ischium, and possesses thick, smooth margins, except where they are formed by the pubis.

The *inlet*, or *brim of the true pelvis*, is bounded superiorly by the sacral promontory, laterally by the ilio-pectineal line, and inferiorly by the crest and symphysis of the pubis. The aperture thus enclosed inclines downwards and backwards, being somewhat ovoid in form, and compressed above by the projecting sacral promontory. The diameters of the inlet vary according to age, size, and sex of the animal. In young animals, and frequently also in the adult male, the vertical or sacro-pubic diameter exceeds the transverse; in the adult female, however, the transverse, taken midway between the symphysis pubis and sacral promontory, exceeds the vertical.

The *outlet*, or *posterior aperture*, is somewhat triangular in form as bounded above, at its apex, by the first coccygeal bone, laterally, by the sacro-sciatic ligaments, and inferiorly, at its base, by the ischiatic arch and tuberosities. Its vertical diameter, from the last sacral or first tail bone, to the centre of the ischiatic arch, is longer than the transverse, taken between the ischiatic tuberosities, which is the smallest of all the diameters. The long pelvic diameter, taken from the middle of the lateral part of the inlet to the ischiatic tuberosity, is usually about equal to the transverse diameter of the inlet.

The Thorax.

The *thorax* or *chest* is formed by the dorsal vertebræ superiorly, by the ribs and their cartilages laterally, and by the sternum inferiorly.

The Sternum (Pl. I. fig. 1, +), a comparatively small and short bone in the horse, is single and symmetrical in the adult, and placed in the inferior longitudinal line of the body at the anterior inferior part of the thorax. The form of the anterior portion particularly is said to resemble a ship's keel, being elongated and concave above, convex below, with its anterior part flattened laterally, and its posterior part flattened above and below. It is constructed of seven irregularly formed osseous pieces united by cartilage in the young animal, and by ossification in the adult; complete ossification, however, is longer in taking place in this than in any other bone. Its anterior end is surmounted by the cariniform cartilage, and its posterior extremity prolonged by the ensiform or xiphoid cartilage.

Its *superior surface* is triangular in outline and concave; the superior sternal ligaments traverse its lateral borders. Its inferior surface is narrow anteriorly and convex, the centre being raised into a prominent ridge coated with cartilage, which materially increases the depth of surface which gives origin to the pectoral muscles. Its *lateral* surfaces are flat and irregular, and present, between the segments of the bone, depressions in which the cartilages of the true ribs articulate and form joints. These depressions, eight in number,—one being in front of the first, and the other behind the last segment,—are oval in shape, and approach nearer to each other as they proceed backwards.

The *cariniform* or *keel-shaped cartilage* presents a convex border looking forwards and upwards, and elevated so as to surmount the articular depressions for the first pair of costal cartilages, to which it is attached by ligaments; laterally it is flattened to increase the surface for muscular attachment; and its inferior border, prolonged over the first pieces of the ster-

num, terminates in the cartilaginous ridge. The prominent convexity which this cartilage forms may be very plainly distinguished in a horse with sloping shoulders.

The *Ensiform cartilage* is somewhat heart-shaped, the apex being directed downwards and backwards. Its superior surface, broad and cup-shaped, occupies a space bounded by the cartilages of the false ribs, and supports part of the liver and intestines. Its inferior surface is convex, and roughened for muscular attachment; and its borders, except the anterior, thin and sharp.

The Ribs (Pl. I. fig. 1, *a'a'*).—In the horse, the ribs usually number eighteen on each side. They extend in a series of arches of varying curves from the dorsal vertebræ above to the sternum and sides of the abdomen below. Their shape, in a great measure, describes the conformation of the chest, and they are the framework which maintains its capacity, and passively determines its increase and diminution in size.

To each rib an elongated piece of cartilage is attached. These cartilages prolong the eight anterior, termed *sternal* or *true ribs*, so that they articulate with the sternum; the ten posterior ribs, not being connected with the sternum, are known as *asternal* or *false ribs*. The ribs, with their cartilages, do not proceed by uniform arches, and in the most direct manner from the vertebræ to the inferior part of the trunk, but pass first outwards and backwards, then in an arched direction downwards, and, towards their inferior extremities, inwards and forwards. They gradually lengthen from the first to the ninth, after which they progressively shorten; their curvature increases from the first, which is nearly straight, to the last, which is a large segment of a comparatively small circle. The greatest breadth is attained in the fifth, sixth, seventh, and eighth, which in their middle portions exhibit the more especial characters of flat bones.

Each rib presents for consideration superior and inferior extremities, and a shaft or body having anterior and posterior borders and external and internal surfaces.

The *superior extremity* is divided into head, neck, and tubercle. The head, which rests in a cavity in the vertebræ, is separated by a vertical furrow, into which the inter-articular ligament is inserted into two convex articular surfaces—one of which looks forwards and inwards, and the other backwards and inwards. The *neck* is the constricted portion supporting the head: it is strong and roughened for ligamentous attachment, and has a groove for the intercostal nerves and blood-vessels running across it in front. The *tubercle* is the prominent eminence at the posterior part of the neck; it has a flat, smooth surface, which articulates with the transverse process of the vertebra. External to the tubercle, is another eminence, *the angle*, where the rib is suddenly bent and twisted downwards. The distance between the angle and the head of the rib gradually increases from the third to the last—the first two scarcely possessing angles. In the third and fourth ribs, the angles and the tubercles are from one to two inches apart, which distance increases, in a well formed horse, to nearly five inches in the last. In properly shaped ribs, and consequently in horses possessing well rounded chests, the costal angles are plainly marked and separated from the vertebræ, so as to form large vertebral grooves for the dorsal muscles; in flat-sided animals, they are indistinct and close to the spinal column, the grooves being very small.

The *inferior* or *sternal extremity* is expanded and constructed of more elastic bone than the superior extremity, having to act both as a spring and as a support. It is quite porous, and joins the cartilage by digitation. The *anterior border* is rough, and excavated along its upper third to give attachment to the intercostal muscles; its lower portion is thin and sharp in the anterior, and rounded in the posterior ribs. The *posterior border* is grooved along its upper third for the intercostal muscles, nerves, and blood-vessels; its lower portion being thin and rough in the anterior, and more obtuse in the posterior ribs. The *external surface* is convex in every direction. Between the head

and the angle, it is roughened for muscular attachment, and below this point smooth, but containing a few eminences, the largest of which, a short distance below the angle, gives attachment to the costo-lumbalis muscle. The *internal surface*, concave from above below, and convex from side to side, is smooth, and for the greater part covered by the pleura.

With the exception of the last, and sometimes the last two on each side, each rib has its cartilage. These cartilages, which contain a large quantity of earthy or bony material, pass obliquely forwards and inwards; they diminish in thickness from before backwards, but increase in length to the eleventh or twelfth, after which they gradually grow shorter. Those attached to the true ribs are smallest at their costal ends, becoming expanded before they articulate with the sternum, while those of the false ribs are largest at their costal ends, and gradually taper to fine points below; they pass almost directly forwards and downwards, each being overlapped by the succeeding.

The peculiar ribs are the two first and the last four or five. The first is shorter and straighter than the others, with rough surfaces, rounded borders, and no well-defined posterior groove; its head is irregular in shape, and exceeded in size by the tubercle, and its inferior end flattened and expanded laterally to become connected with a short thick cartilage which contains much ossific matter. The second possesses the characters of the first in being straighter than any behind it, in the size of its tubercle, in its expanded inferior end, and in its possessing a short, thick cartilage. The last four or five are slender; the articular surfaces of their tubercles and the posterior divisions of their heads are continuous; their curve is very great; they are broadest immediately behind the tubercle; and their cartilages are remarkably slender and elongated.

Each true rib has four articular surfaces, viz., two on the head, one on the tubercle, and one at the sternum; the false ribs have no inferior articulations.

The bony framework of the chest bears some resemblance to a

truncated cone, with its apex or anterior extremity compressed laterally. The anterior aperture is a triangular space, having its apex directed downwards and slightly forwards, formed by the sternum, first ribs, and first dorsal vertebra. It gives passage to the œsophagus, trachea, and numerous important nerves and blood-vessels. The base or posterior aperture is oval in outline, and waves obliquely downwards and forwards from the vertebræ; it is formed by the last dorsal vertebra, the last ribs, the cartilages of the false ribs and the ensiform cartilage, and gives attachment to the diaphragm which closes the thoracic cavity behind.

The Locomotor Organs.

The extremities or locomotor organs, in all quadrupeds, form two anterior and two posterior limbs or legs.

The Fore Extremity.

The bones of the fore leg are the scapula, humerus, radius, and ulna; the bones of the carpus, viz., the cuneiform, lunar, and scaphoid in the upper row, and the unciform, magnum, trapezoid, and pisiform in the lower row; the large and two small metacarpal, two sesamoid, suffraginis, coronæ, pedis, and naviculare.

The Scapula (Pl. I. fig. 1, *c'*), a flat bone, occupying a direction obliquely downwards and forwards on the anterior lateral surface of the thorax, is triangular in shape, with its base turned upwards, its anterior angle opposed to the transverse process of the fourth dorsal vertebra, its posterior angle against the angle of the seventh rib, and its inferior angle or extremity opposite to the lower angle of the first rib. In the horse, the scapula is a strong but comparatively small bone, broad and thin superiorly, and narrower and thicker inferiorly; in the young animal, it is the shortest of all the bones proportionately to the size which it attains in the adult. It offers for consideration two surfaces, three borders, and three angles.

The *external surface*, or dorsum of the scapula, is divided into two unequal parts by the *spine*, which, at its broadest part, has a roughened *tubercle* to which the trapezius muscle is attached; the hollow part in front of the spine, the *antea spinatus fossa*, receives the ante spinatus muscle, and the *postea spinatus fossa*, by far the larger of the two, is occupied by the post spinatus, and gives attachment to the postea spinatus minor muscle. The nutrient foramen is in this fossa.

The *internal surface* is smooth, though uneven; its fossa, the fossa subscapularis, lodges the subscapularis muscle, and the rough triangular spaces at the upper angles give attachment to the serratus magnus and rhomboideus muscles.

The *superior border* is nearly straight, and has the cartilage of prolongation fixed to its roughened summit. The *anterior* border is, superiorly, convex and sharp; and inferiorly, concave and blunted, and terminates in a large, rough, hemispherical and somewhat hooked process, the *coracoid*, to which the coracohumeralis and coraco-radialis muscles are attached. The *posterior border* is blunt and rough, and affords attachment to several muscles.

The *anterior* or *cervical angle* is thin; the *posterior* or *dorsal angle* is thick and tuberous; and the *inferior* or *humeral angle* is expanded and separated from the rest of the bone by a constriction or *neck*. This angle is the strongest part of the bone, and contains a shallow, oval, articular depression, the *glenoid cavity*, surmounted by a rim of bone to which the capsular ligament is attached, and having, at its inner side, a notch for the blood-vessels which are continued through a groove at the posterior external part of the coracoid process. Between the anterior internal part of the cavity and the recurved portion of the process is a fissure through which the tendon of the subscapularis passes. The coracoid process is an epiphysis, having a separate point of ossification. The scapula has no bony connection with the trunk.

The HUMERUS (Pl. I. fig. 1, *f*) is a long bone which extends

from the scapula to the radius, in an oblique direction, down wards and backwards—a reverse direction to the scapula. I possesses a shaft, and superior and inferior extremities.

The *shaft* or *body* is an irregular prism twisted upon itself and has anterior, posterior, external, and internal surfaces. Th *anterior surface*, triangular in shape, with the point below, i roughened between its middle and inferior third, for the inser tion of the coraco-humeralis muscle. The *posterior surface*, roun and smooth, and having no well marked demarcation from th internal and external surfaces, terminates inferiorly in two pro minent ridges, the epitrochlea and epicondyle. The *external surface* contains the musculo-spiral groove, which winds obliquely downwards and forwards through the entire length o the shaft. This groove, which is occupied by the humeralis externus muscle, gives the twisted appearance to the bone; it is separated from the anterior surface by the *trochanteric ridge*, which extends from the outer part of the superior extremity of the shaft to the coronoid fossa in the anterior inferior part of the bone. A roughened prominence, the *external tuberosity*, on the upper third of this ridge, comes backwards over the spiral groove, and gives attachment to the levator humeri and other muscles. The *internal surface* has no distinct separation from the anterior and posterior surfaces: a rough prominence on its middle, the *internal tuberosity*, gives insertion to the tere major and latissimus dorsi muscles. The medullary foramen in its inferior third.

The *superior extremity* presents the head and the troch anters. The *head* is hemispherical, and considerably larg than the glenoid cavity in which it articulates, so as to allow greater freedom and variety of motion; it is surrounded by roughened border for the insertion of the capsular ligamen below which is the constricted neck of the bone. A rou depression on the front of the head contains several sm foramina for the blood-vessels which supply the cancellat tissue.

The *external trochanter* has two prominences, the anterior, or summit of the trochanter, which forms the external boundary of the bicipital groove, and gives insertion to the outer tendon of the antea spinatus muscle, and the posterior, or convexity of the trochanter, the more prominent of the two, which serves to keep the scapula in its place; it is covered with fibro-cartilage, over which glides the tendon of the postea spinatus, which is inserted into a rough surface below the convexity. The trochanteric ridge joins this trochanter to the external tuberosity.

The *internal trochanter* is divided into three roughened parts, anterior, posterior, and inferior. The anterior forms the internal boundary of the bicipital groove, and gives insertion to the inner tendon of the antea spinatus; the posterior gives attachment to the subscapularis, and the inferior to the pectoralis magnus muscles.

Between the anterior part of the internal and the summit of the external trochanters is the *bicipital groove*, divided by a middle prominence into two channels; these are covered with fibro-cartilage, and serve as a pulley over which the tendon of the flexor brachii muscle plays.

The *inferior extremity* is smaller than the superior, and smooth to articulate with the radius and ulna; its surface is convex, and wider in front than behind. A deep groove, which extends from the coronoid fossa to the condyloid or olecranon fossa, divides it into an internal condyle, and an external condyle or trochlea, the latter being the smaller, and having a shallow furrow running across it from before backwards. At the side of the external condyle is a deep pit into which the external lateral ligaments are inserted, and from which a prominent ridge, the epitrochlea, extends upwards, and gives origin to the extensor metacarpi magnus, extensor pedis, and flexor metacarpi externus muscles.

Running from the posterior part of the internal condyle is a large eminence, the epicondyle, from which the flexor metacarpi

internus, one head of the medius and flexor pedis, perforans and perforatus, arise, and behind its lateral side is a small eminence for the attachment of the internal lateral ligaments.

A deep ovoid fossa, the condyloid, which receives the olecranon during the extension of the fore-arm, separates the epicondyle from the epitrochlea posteriorly; and anteriorly, just above the groove in the articular surface, is the shallow coronoid fossa, for the coronid process of the radius during extreme flexion of the fore-arm.

The Bones of the fore arm are the radius and the ulna, which in the young animal are distinct, but in the adult become firmly united by ossification, and are sometimes described as one bone, the os brachii. We shall describe them separately.

The Radius (Pl. I. fig. I, *g'*) belongs to the class of long bones, and occupies a vertical position between the humerus and the bones of the carpus. It possesses a shaft and two extremities. The *shaft* is flattened and curved, with gradually expanding extremities. Its anterior surface is smooth, and clothed with the extensor muscles of the leg and foot; and its posterior surface, concave from above downwards, and clothed with the flexor muscles, presents towards its external border a rough triangular face, which commences in a slender point near the middle of the bone, and terminates at the lower part of its upper fourth. This face corresponds with the anterior surface of the ulna, to which it is attached by interosseous ligaments in the young animal, and by ossification in the adult. The shallow transverse groove above this face assists in the formation of the radio-ulnar arch, and the nutrient foramen of the bone is close to the groove. On the inferior third of the internal border of the shaft is a ridge to which the radius accessorius muscle is attached; the external and internal lateral borders are rounded, and have no distinct separation from the anterior and posterior surfaces.

The *superior extremity*, larger than the inferior, presents a concave articular surface, divided into two concavities (the

glenoid cavities) which receive the condyles of the humerus, the inner being the largest, and articulating with the internal condyle, the outer having a slight eminence on its centre which corresponds with the depression in the trochlea. A rough ridge round the articular surface gives attachment to the capsular ligament. The anterior part has a prominent lip, the coronoid process, in its centre, and near its internal border a rough eminence for the insertion of the tendon of the flexor brachii and part of the humeralis externus. On each side of the articular surface is a roughened surface for the lateral ligaments, the external, which is surmounted by a tuberosity for the extensor pedis and extensor suffraginis muscles, being the most prominent. Posteriorly, two concave facets articulate with the ulna.

The *inferior extremity*, like the superior, is widest from side to side. Its articular surface is divided into three facets, the internal of which, the largest, and quadrilateral in shape, articulates with the scaphoid; the middle, resembling the internal, but smaller, articulates with the lunar; and the external, the smallest, oval in shape and convex, articulates with the cuneiform and the trapezium. The whole articular surface is surmounted by a prominent ridge for the capsular ligaments. The anterior part of this extremity is irregular, and has two deep vertical grooves for the tendons of the extensor muscles, and a shallow oblique one in which the extensor metacarpi obliquus works. Laterally, two prominent processes, the internal being the largest, and in well-bred horses especially, forming one of the most conspicuous parts of the knee, give attachment to the lateral ligaments. The external of these processes is grooved for the passage of the extensor suffraginis.

The Ulna (Pl. I. fig. 1, *h'*), an irregular bone, triangular in form with the base uppermost, is placed on the superior posterior part of the radius. This bone, which scarcely grows after birth, is larger in the young animal, proportionately to its ultimate size, than any other bone in the body. It possesses a body and two extremities.

The *body* is triangular, and has three surfaces and three

borders. The *anterior surface* is the counterpart of the posterior surface of the radius against which it is applied, having superiorly two convex facets to articulate with the concave ones on the head of the radius; below these is a rough portion for the attachment of the interosseous ligaments, and still lower, a shallow transverse groove which assists in the formation of the radio-ulnar arch, inferior to which is a roughened surface for the attachment of the ligaments by which the bones are united, and where ossification takes place in the old animal. The *external surface* is flattened and covered by the extensor metacarpi externus muscle, and the excavated *internal surface* gives attachment to the ulnarius accessorius, and is covered by the flexor pedis muscles. The *lateral* borders are thin, and have the arciform ligaments attached, and the *posterior border*, concave and round, gives insertion to muscles. The *inferior* extremity is pointed, and extends as far as the middle of the radius, though sometimes, in the ass and mule particularly, it reaches to the inferior extremity of that bone. The *superior extremity* comprises that considerable portion of bone, corresponding to the elbow of man, which projects upwards and backwards from the articular surface of the radius, and is known as the *olecranon process*. It presents two surfaces, two borders, and a summit. The *external surface* is slightly convex, and roughened for muscular attachment; the *internal surface*, deeply excavated and smooth: the *posterior border*, concave, thin, and smooth; and the *anterior border*, thin superiorly, hollowed into a crescent-shaped surface, which articulates with, or rather behind and between, the condyles of the humerus, the prominent portion being known as the beak of the olecranon. The summit is the broad roughened protuberance, which gives insertion to the tendon of the triceps extensor brachii muscle.

The Carpus (wrist or knee, as it is termed in quadrupeds) is composed generally of seven and sometimes of eight small, irregular bones, arranged in two rows of three each, one above the other, the seventh being at the back of the three in the upper

row, and the eighth, when present, in a similar position in the lower row.

An examination of the knee shows how admirably it is adapted to obviate concussion, and, at the same time, to allow of great freedom of action. The joints pass completely through from front to back, and are so arranged that those of one row shall not be opposed to those of the other. The bones, at the same time, are embedded in elastic cartilage, which, in a still greater measure, contributes to the elasticity of the part.

A large, well-developed knee is indispensable in a horse required for fast work. The upper row of bones performs a greater amount of motion than the lower, which is comparatively stationary. "Broken knees" generally occur in the joint between the radius and the upper row, or in that between the two rows, and seldom or never between the lower row and the metacarpus.

The bones of the upper row are the scaphoid, lunar, and cuneiform in front, and the trapezium behind; and of the lower row, the trapezoid, magnum, and unciform, the eighth being the pisiform.

The Scaphoid (Pl. I. fig. 1, *m'*), the innermost and largest of the upper row, presents six surfaces, the *anterior* and *external* being continuous, convex, and roughened for ligamentous insertion; the *posterior*, rough and irregular; and the *internal*, excavated and roughened, and having three projections, with smooth articular facets, which articulate with corresponding facets on the os lunare. The *superior surface* is smooth, sigmoid or concavo-convex, and articulates with the internal division of the inferior extremity of the radius; the *inferior surface* is also smooth, with two articular facets, an anterior, slightly convex, for the os magnum below, and a posterior, concave, or cup-shaped, for the trapezoid.

The scaphoid articulates with four bones, viz., the radius above, the lunar internally, and the magnum and trapezoid below.

The Os lunare (Pl. I. fig. 1, *l'*), the middle bone in the upper

row, both in size and position, is somewhat wedge-shaped, and has four surfaces, a base, and an apex. The *superior surface* is triangular and smooth, with a concavity in its centre, which articulates with the middle division of the inferior extremity of the radius. The *inferior surface* is smooth, and presents two surfaces, divided by a ridge—one oblong, concavo-convex, occupying about five-sixths of the surface, and articulating with the magnum; the other also oblong, but flat, and situated at the anterior external border, where it articulates with the unciform. The *internal lateral surface* is excavated and roughened, and possesses three articular projections, which correspond with those on the scaphoid. The *external lateral surface* has two articular facets for the cuneiform. The *base* is broad and rough, and looks forwards; and the *apex*, also rough, looks backwards.

The lunare articulates with five bones, viz., the radius above, the scaphoid internally, the cuneiform externally, and the magnum and unciform below.

The Cuneiform (Pl. I. fig. 1, *k'*), the smallest and most external of the bones in the upper row, has five surfaces:—the *superior*, smooth and cup-shaped, articulates with the radius; and the *inferior*, smooth and concave, with the unciform. The *external surface* is convex and rough, and gives attachment to ligaments; the *internal lateral* has two facets, which articulate with corresponding ones on the lunar, and an intervening interosseous roughened portion; and the *posterior surface*, which slopes downwards and backwards, presents, on its inferior half, a cup-shaped articular facet for the trapezium behind.

The cuneiform articulates with four bones, viz., the radius above, the lunar internally, the unciform below, and the trapezium behind.

The Trapezium (Pl. I. fig. 1, *q'*), placed immediately behind the cuneiform, is broad and flattened, and presents two surfaces and four borders. Both its surfaces are rough, the *internal* being concave and the *external* convex, and having a deep groove for the

passage of one of the tendons of insertion of the flexor metacarpi externus. The *superior*, *posterior*, and *inferior borders* are roughened—the *superior* receiving the insertion of the tendon of the flexor metacarpi medius and the second tendon of the externus, the *posterior*, the insertion of the posterior annular ligament, and the *inferior* receiving a ligament also.

The trapezium is the lever bone of the knee, its prominence being a great point in a horse required for power. What is commonly called "tying in of the knee" is due to a bad development of it.

In the lower row, the TRAPEZOID (Pl. I. fig. 1, *p'*), the smallest of all the bones of the knee, excepting the pisiform, presents four surfaces, a base, and an apex. The *superior surface*, smooth and rounded from before backwards, narrow anteriorly, and broad posteriorly, articulates with the scaphoid. The *inferior surface* is smooth, and possesses two facets, one of which, large, flat, and semicircular, articulates with the inner splint, and the other small, square, and bevelled, rests on the cannon. The *external lateral surface* is convex and rough, and the *internal*, rough, with the exception of three projecting facets, which articulate with the magnum. The *apex* looks forwards, and the *base* backwards, both being roughened, with the exception of an occasional small, cup-shaped articulation for the pisiform on the inferior external part of the base.

The trapezoid articulates with five bones, viz., the scaphoid above, the magnum internally, the large and inner small metacarpal below, and the pisiform behind.

The MAGNUM (Pl. I. fig. 1, *o'*), the largest bone in the knee, and the central in the lower row, is somewhat triangular in shape, and presents four surfaces, a base, and an apex. The *superior surface* is smooth, and divided into two portions by a ridge, the inner one being square and concave, to articulate with the scaphoid, and the external, oblong and concavo-convex, to articulate with the unar. The *inferior surface*, smooth and flat, rests on, and articulates with, the large metacarpal bone, having also a very small

triangular bevelled portion near its inner surface, which articulates with the inner small splint. The *internal lateral surface* is rough and irregular, and possesses three facets, which articulate with the trapezoid. The *external lateral surface* joins the uneiform, and has two articulations, with a deep notch between. The *base* looks forwards, and the *apex* backwards, both being roughened for ligamentous insertions.

The magnum articulates with six bones, viz., the scaphoid and lunar above, the large and inner small metacarpal below, the trapezoid internally, and the uneiform externally.

The Uneiform (Pl. I. fig. 1, *u'*), the most external in the lower row, is very irregular in form, and resembles the trapezoid; it has four surfaces, a base, and an apex. The *superior surface* smooth, convex from side to side, and sloping towards the external surface, is divided into two facets, an internal for the lunar, and an external for the cuneiform. The *inferior surface* is smooth, and divided into three facets, two of which, the anterior and the posterior, articulate with the cannon bone, and the middle with the external small splint. The *internal lateral surface* presents two facets, which articulate with corresponding facets on the magnum, and an intervening roughened portion. The *external surface* is narrow, the *base* looks forwards, and the *apex* looks backwards, all the three being roughened for ligamentous attachment.

The uneiform articulates with five bones, viz., the lunar and cuneiform above, the magnum internally, and the large and external small metacarpals below.

The Pisiform (Pl. I. fig. 1, *i'*), a very small pea shaped bone, situated, when present, at the posterior internal part of the knee, in some cases articulating with the trapezoid and in others being imbedded in the internal lateral ligament. It is generally, perhaps always, present in old subjects, but sometimes overlooked owing to its small size.

The Metacarpal Bones, in solipedes, are three in number, a large one in the middle, and a small one at each side.

The Os METACARPI MAGNUM (Pl. I. fig. 1, *r'*), (large metacarpal, cannon, or splint bone), is a long cylindrical bone placed in a vertical direction, which presents a body, a shaft, and two extremities. The shaft of this bone possesses a greater thickness of compact bone, and is, therefore, thicker than any other long bone; it is flattened from side to side, and has two surfaces, anterior and posterior, the anterior being convex and smooth, and the posterior broad and flattened, and pierced about one-third down by the medullary or nutrient foramen. On each side of this surface is a vertical ridge, to which the small splints are attached.

The *superior extremity*, flattened from before backwards, presents a smooth superior surface, constituted of three articular facets, one large and flat, on which the os magnum rests; the second very small, towards the posterior part of the internal border, where it articulates with a portion of the trapezoid; and the third, which articulates with the unciform, and occupies the whole external border, being bevelled off from within outwards, and divided, by a deep furrow, into two portions. In front of the large articulation, towards the inner border, is a roughened prominence for the insertion of the extensor metacarpi magnus, and at the posterior part of the head a roughened surface, from which the suspensory and metacarpal ligaments spring. On each side of the latter, two facets, divided by furrows, articulate with corresponding facets on the small splint bones.

The *inferior extremity*, widest from side to side and convex from before backwards, presents an articulatory trochlea, which consists of two condyles separated by a prominent semicircular ridge, the whole of which fits into a corresponding depression on the head of the os suffraginis below, and articulates with that bone and the two sesamoids behind. Each of the condyles, the internal being slightly the larger of the two, presents a depression on its lateral side for the insertion of the lateral ligaments.

The large metacarpal bone articulates superiorly with the trapezoid, magnum, and unciform, laterally with the small splints, and inferiorly with the os suffraginis and the two sesamoids.

The Ossa metacarpi parvi (Pl. I. fig. 1, *s'*), or small splint bones, are attached to the large bone, one on each side of its posterior surface, by fibro cartilage in the young animal, and by ossification in most grown up and in all old animals. They vary somewhat in length in different animals, but usually extend two-thirds down the cannon, the external being generally the largest. They are divided into a base, a middle, and an apex.

The base, or head, of each bone is turned upwards, its superior surface being articulatory, and entering into the formation of the knee joint, the internal possessing two articular facets, one large and flat, on which the trapezoid rests, and the other small and bevelled towards its anterior surface, to articulate with a portion of the magnum. The external splint has but one articular facet, which gives support to the unciform. Below the articular surface, externally, the heads are roughened for the insertion of the tendon of the flexor metacarpi internus to the inner, and that of the flexor metacarpi externus to the outer. The internal lateral parts of the heads each present two articular facets, which correspond with those on the sides of the head of the cannon. The middle part or body tapers gradually downwards from the head, and is firmly attached to the cannon by its anterior surface. The apex is also tapering, and terminates in a round knob, which never, except in the case of disease, becomes attached to the parent bone. These knobs are very prominent in well-bred horses, and are sometimes mistaken for splints, which are exostoses between the large and small metacarpal bones.

In solipedes, where each of the extremities terminates in a single toe enclosed in a solid hoof of horn on which the animal rests, the digit is composed of three bones placed one immediately below the other, and having three supplementary or sesamoid bones added behind. The three principal bones represent the three phalanges of the human finger, the os suffraginis representing the first phalanx, the os coronæ the second, and the os pedis the third.

The joint which the large metacarpal forms with the os suffraginis and its two sesamoids is the fetlock; that between the os suffraginis and the os coronæ is the pastern; and that between the os corona and the os pedis, with their supplementary or navicular bone, is the coffin joint.

The Os SUFFRAGINIS (Pl. I. fig. 1, *u'*) (large pastern or first phalanx) occupies a direction obliquely downwards and forwards, and articulates with the cannon above and the small pastern below. It belongs to the class of long bones, and presents a body and two extremities.

The *body*, which is slightly flattened from before backwards, has an anterior surface convex and smooth, and a posterior surface somewhat flattened, and presenting two roughened ridges, in the form of a triangle, with its base upwards, into which the sesamoidean ligaments are inserted.

The *superior extremity*, the larger of the two, presents a smooth, semilunar-shaped surface, the convexity being in front, and consists of two lateral glenoid cavities for the condyles, and a deep central groove for the middle eminence of the cannon bone, and having behind, on each side, a roughened tuberosity for the attachment of the crucial ligaments. These projections, when well developed, give squareness to the fetlock, a great point in a horse, since nothing can be worse than a round fetlock, though they are very liable to fractures, especially in hunters and roadsters, where they are well developed.

The *inferior extremity*, much smaller than the superior, is divided into two condyles by a shallow groove, continuous with which, posteriorly, is a pit or depression into which fits a prominent lip on the posterior part of the os coronæ, and in the centre of the front a slight eminence, to which a slip of the tendon of the extensor pedis is attached. On each side is a roughened depression for the insertion of the lateral ligaments.

A horse in which the large pastern is very short and upright, is not only very liable to stumble, but is also, owing to its stilty gait, very bad to ride.

The two SESAMOID BONES (Pl. I. fig. 1, *t'*) are placed side by side at the posterior inferior part of the metacarpus and posterior superior part of the suffraginis; they are irregular or polyhedral in shape, having a smooth and concave *anterior surface* and bevelled inner borders, the two bevelled edges forming a groove into which the ridge at the inferior extremity of the cannon is received, the concave portions articulating with the condyles of that bone. The *posterior surfaces* are roughened, for the attachment of the suspensory ligaments, and when *in situ* form a channel, which is filled with fibro-cartilage for the easy passage of the flexor pedis muscle. The *superior extremity* or *apex* of each bone is roughened, as are also their lateral borders, which are grooved for the reception of slips of the suspensory ligament. The *inferior surface* or *base* is also roughened, so as to afford insertion to the inferior and crucial ligaments by which they are attached to the os suffraginis.

The Os CORONÆ (Pl. I. fig. 1, *v'*) (small pastern or second phalanx) has no medullary canal, and belongs to the class of irregular bones. It is situated, like the os suffraginis, in an oblique direction from above downwards and forwards, and is partly within and partly without the hoof. It presents four surfaces, superior, inferior, anterior, and posterior, and is remarkable for its great strength, being broader than long. The *superior surface* is smooth, and divided by a transverse eminence into two glenoid cavities for the condyles of the suffraginis; and having, in the centre, two slight eminences, which, by limiting its motion, make the joint more secure; a portion of the tendon of the extensor pedis is attached to the anterior, and a ligament to the posterior of these eminences. The *inferior surface* of the bone is smooth and convex, and divided by a central depression into two condyles, which articulate with the os pedis and os naviculare. The *anterior surface* is convex and very rough, widest superiorly; its inferior lateral parts presenting two depressions, into which the tendons of the flexor pedis perforatus is implanted, above these being the place of attachment of part of the tendon of the extensor pedis

The *posterior surface*, slightly excavated and not very rough, has, towards its upper part, a prominent eminence covered by fibro-cartilage, which forms a surface over which plays the tendon of the perforans.

This bone is not very liable to fracture, and when such an accident does occur, recovery seldom, if ever, takes place.

The Os PEDIS (Pl. I. fig. 1, *w'*) (coffin bone or third phalanx) is an irregular bone situated within, and, when in a healthy state, corresponding with the hoof in shape, being semi-lunar in form, the convexity being to the front. It is a very hard but porous bone, having several excavations and foramina for the transmission of arteries and veins. In this bone we require to notice the wall, the sole, the tendinous surface, the articular surface, and the alæ or wings.

The *wall*, or *anterior surface*, is the porous semicircular part in front which presents numerous perforations or holes, the larger being foramina for the passage of blood-vessels and nerves, and the smaller for the attachment of the horny lamina. Anteriorly it is surmounted by the *superior spinous*, *coronal*, or *pyramidal process*, which gives insertion to the tendon of the extensor pedis, and prevents the small pastern from slipping too far forwards, a ligament of the coffin joint being inserted into an excavation on each side of this process. The inferior edge of the wall is serrated or notched, the notches opening into different foramina; and its declivity increases in degree, but decreases in extent as it proceeds backwards. At each side is the *preplantar groove*, which terminates in a large foramen, and along which the lateral laminal artery passes.

The *sole*, or *inferior surface*, which lies on the sensitive or vascular sole, is slightly excavated and half-moon shaped, and, excepting the articular surface, is the smoothest part of the bone; it is bounded externally by the inferior edge of the wall, and at its posterior internal part by an uneven semicircular ridge, the *semi-lunar ridge*, which separates it from the tendinous surface.

The *tendinous surface* is semicircular, and placed immediately

behind the sole; it presents a triangular roughened depression on its middle and anterior part, where the tendon of the flexor pedis perforans becomes inserted, and on each side a groove, the *plantar groove*, which terminate in two large foramina (the *plantar foramina*), along which pass the arteries and nerves proceeding to the anterior of the bone. The posterior part of this surface is roughened for the insertion of the inferior navicular ligament.

The *articular surface* presents two glenoid cavities, separated by a transverse eminence which terminates in the coronal process; this part of the surface articulates with the inferior extremity of the os coronæ. Behind the cavities, a flattened triangular part articulates with the os naviculare.

The *alæ* or *wings* consist of the two protuberances on the posterior part of the wall; they are bifid, being divided by a fissure or notch, the *preplantar fissure*, which, in old animals, is converted into a foramen, through which the lateral laminal artery passes to gain the preplantar groove on the wall. The inferior and posterior portion of the ala, the most bulky of the two, is the *retrorsal process*; and the superior portion, thin and giving origin to the lateral cartilages, is the *basilar process*.

The wings sometimes grow above the hoof, forming side bones: ring bones being formed on the pastern bones.

The Os NAVICULARE (Pl. I. fig. 1, *x'*), navicular, or shuttle bone, the last of the fore extremity, is a long, irregular bone, situated transversely behind and below the os coronæ, and behind and above the os pedis, with both of which it articulates, the articulation of the three forming the coffin joint. This bone, which is of some importance to the veterinary surgeon, being the one principally involved in groggy lameness or navicular arthritis, presents two surfaces, two borders, and two extremities. The *superior surface* is smooth, with two concavities which articulate with the condyles of the os coronæ and a central eminence; the inferior surface is rough, and also has two concavities and a central eminence, which are covered with fibro-cartilage, and forms a pulley

over which plays the tendon of the perforans. The *anterior border* is divided into two portions, a superior, smooth and triangular, which articulates with the os pedis, and an inferior, elongated, rough, and porous, which gives insertion to the broad inferior navicular ligament by which it is attached to the coffin bone. The *posterior border* is triangular, rough, and porous, and gives insertion to the posterior ligament; the *extremities* are pointed, and attached to the coffin bone by lateral ligaments. The bursa, where the tendon passes over the inferior surface, is the seat of navicular lameness.

The Hind Extremity.

The bones of the hind extremity are the femur, tibia, patella, fibula; bones of the tarsus, viz., the astragalus, calcis, three cuneiform, and cuboid; one large and two small metatarsal; suffraginis; two sesamoid; coronæ, pedis, and naviculare.

The Os femoris (Pl. I. fig. 1, *y'*) (femur, haunch, or round bone), the largest, thickest, and strongest bone in the body, belongs to the class of long or cylindrical bones, and is placed in a direction obliquely downwards and forwards, between the cotyloid cavity of the os innominata and the tibia, fibula, and patella. It offers for consideration a body or shaft and two extremities.

The *shaft* is irregularly cylindrical, and has two surfaces and two borders. The *anterior surface* is smooth, prominent, and marked by a few muscular imprints. The *posterior surface* is flattened and expanded at its upper part, and presents, towards the external part of its upper third, a circular roughened surface for the insertion of one of the heads of the triceps abductor muscle; towards the inner border of its superior third, a slight ridge, which runs obliquely upwards and outwards to join the upper part of the internal trochanter, and to which the ischio-femoralis is inserted; and in its middle third, a roughened four-sided, oblique surface, for the attachment of the adductor magnus; and, still lower, a large groove which passes obliquely

outwards and downwards for the popliteal blood-vessels. The *external border*, which separates the anterior from the posterior surface externally, presents a prominent ridge, on the upper third of which is a sharp, flat protuberance, the *trochanter minor externus*, recurved forwards, and affording attachment to the tendons of the gluteus externus, vastus externus, and triceps abductor muscles. At the lower third of this border is a deep, oval, roughened pit or fossa, the *supra condyloid*, from which the gastrocnemii muscles arise. The *internal border*, dividing the anterior from the posterior surface, internally, presents, near its upper third, a blunt roughened prominence, the *trochanter internus*, from which a ridge extends upwards to the head, and to which the psoas magnus, iliacus, and vastus internus muscles are inserted. From this trochanter another ridge, into which the pectineus muscle is inserted, runs downwards, the nutrient foramen being at its lower part.

The *superior extremity* is divided into the head and the trochanter major. The *head* is the smooth articular portion which looks upwards and inwards, and is received into the cotyloid cavity. It is separated from the body by a constricted portion—the neck, not well marked in solipedes, and between the head and neck there is a ridge for the insertion of the capsular ligament. The deep notch at the inner part of the head is for the insertion of the pubio-femoral and round ligaments. The trochanter major is a very large eminence, which looks outwards and upwards, and presents, posteriorly, a prominent part, termed the *summit*, which stands a little higher than the articular head, and gives attachment to one of the heads of the gluteus maximus, and, anteriorly, the *convexity*, which is rounded and covered externally by cartilage of incrustation, which forms a bursa, over which plays the other tendon of the gluteus maximus, which becomes inserted into the ridge just below. Behind the trochanter, and between it and the head, is the *trochanteric* or *digital fossa*, around and into which several small muscles are inserted; bounding this fossa externally is a very sharp

crest or ridge, which is continuous with the posterior part of the summit of the trochanter, and gives insertion to a tendon of the obturator muscle.

The *inferior extremity* possesses two condyles and a trochlea; the condyles, which articulate with the head of the tibia, are placed side by side, being separated by a deep *intercondyloid groove*, from which the interosseous crucial ligaments of the articulation spring, and into which the spine of the tibia projects. The external condyle has two fossæ, an inferior for the insertion of the popliteus, and a posterior for the external lateral ligament; the internal condyle has a roughened prominence on its lateral surface, for the insertion of the internal lateral ligament.

The *trochlea* is the pulley-shaped part on the front of the condyles, which articulates with the patella: it consists of two prominences divided by a groove, which is continuous with the intercondyloid fossa. The internal prominence is the thickest and most prominent; and between the external prominence and the external condyle is a deep pit, into which the tendons of origin of the peroneus, extensor pedis, and flexor metatarsi muscles are inserted.

The Patella (Pl. I. fig. 1, *z'*), or stifle bone, corresponding to the knee-cap of man, is placed in front of the trochlea of the femur. It is somewhat diamond-shaped and very compact, its *anterior surface* being irregularly convex and very much roughened, for ligamentous attachment, and its *posterior surface* smooth, to articulate with the trochlea of the femur, and presenting two concavities divided by a ridge, the innermost being the larger. The *superior surface* of this bone is broad, uneven, and roughened, giving insertion to the tendons of the rectus femoris and vasti muscles; the *inferior surface* is sharp, and gives insertion to the three inferior straight ligaments of the patella; and the *lateral surfaces* are sharp and pointed, and have the lateral ligaments attached.

The patella may be regarded as a sesamoid bone developed in the extensor muscles so as to increase their leverage, by enabling

them to act at a greater angle. It is liable to fracture by muscular contraction, and to luxation, in which case the internal lateral ligament is ruptured.

The Tibia (Pl. I. fig. 1, *a''*), or thigh bone, is a long bone, larger at its upper than its lower end, situated between the femur and the astragalus in an oblique direction from above downwards and backwards. It presents a body and two extremities.

The *body* or *shaft* is three-sided, possessing outer, inner, and posterior surfaces, all of which are wider above than below. The *outer surface*, concave superiorly and convex inferiorly, is smooth, and lodges the extensor pedis muscle; the *inner surface*, slightly convex from side to side, is smooth, excepting at its superior part, where it gives attachment to one tendon of the biceps, rotator tibialis, and the sartorius and gracilis muscles, and covered almost entirely by skin and fascia and a strong periosteum; and *the posterior surface*—the broadest of the three, and almost flat—presents on its superior third a triangular, almost smooth portion, to which the popliteus is attached, the remaining two-thirds being strongly marked by a number of longitudinal ridges, which give attachment to the body of the flexor pedis perforans. The nutrient foramen is in the upper third of this surface.

The *anterior border* is rounded, and very indistinctly marked in its lower part, but presenting in its upper third a prominent ridge, the *tibial ridge*, which is curved outwards, and joins the anterior tuberosity of the superior extremity. The *external border* is thick and concave above, so that, with the fibula, it forms the tibial arch. The internal border is also thick, and, at its upper part, has a small tubercle, to which the popliteus is attached.

The *superior extremity* is much more expanded than the inferior, and presents two large smooth, somewhat undulated, articular surfaces, divided by a roughened conical process—the *tibial spine*—on the outer side of which is an irregular excavation for the insertion of the crucial ligaments. The semi-lunar cartilages are interposed between these surfaces and the extremity of the femur. Anteriorly, a tuberosity, concave externally and convex

internally, joins the tibial ridge, and presents a vertical notch in front for the middle straight ligament of the patella. At the sides are two lateral processes, to which the lateral ligaments are attached, the external being the largest, and presenting a semi-circular articular facet for the head of the fibula. Between this process and the anterior tuberosity is a deep groove, for the passage of the tendon of the extensor pedis.

The *inferior extremity*, much smaller than the superior, and flattened from before backwards, presents two smooth deep grooves, which run obliquely from before backwards, and from without inwards, the internal being the deepest, and the external the widest, and three projections, the middle one, which forms a division between the grooves, being smooth, and the others, which form the lateral processes or malleoli, roughened for the reception of ligaments. The middle projection terminates in a prominent lip of bone; the internal malleolus is the most prominent, and the external the widest, and grooved for the passage of the tendon of the peroneus. A large development of the external malleolus is sometimes mistaken for disease.

The Fibula (Pl. I. fig. 1, *b''*), a long slender bone, is an appendage to the tibia, being attached to the outer side of that bone, and extending from its head to its lower third, to which it is affixed by a ligamentous cartilage. It presents a body and a head.

The *head*, or *superior part*, is bulky, flattened from side to side, and roughened externally for the attachment of the peroneus muscle and the lateral ligaments; internally, it articulates with the external lateral part of the head of the tibia. The *body* is slender, and tapers to a point, from which a ligament is continued the whole length of the bone.

The Tarsus or Hock, corresponding to the ankle of man, is composed of six irregular compact bones, placed between the lower end of the tibia and the superior extremities of the metatarsal bones, and arranged in two rows of three each, the anterior, viz., the astragalus, the cuneiforme magnum, and cuneiforme medium, being the weight-carriers; and the posterior, viz., the

os calcis, the cuboid, and the cuneiforme parvum, being for ligamentous attachment. These bones are thickly covered or embedded in cartilage, which acts as a cushion to meet and obviate concussions.

The Astragalus (Pl. I. fig. 1, *d″*) (os tali, ankle, or knuckle bone) is a pulley like bone, the strongest in the hock, and placed immediately below the tibia, with which it articulates. It presents five surfaces, viz., superior, inferior, posterior, and two lateral.

The *superior*, or *superior anterior surface*, is smooth, and presents two oblique pulley like prominences, separated by a deep groove, into which fits the middle projection on the lower end of the tibia, the prominences fitting into the corresponding oblique grooves on the lower end of that bone. The *inferior surface* is concavo-convex, and smooth; the whole of it, except a small oval external portion, which rests on part of the cuboid, and a roughened excavated posterior portion into which the interosseous ligament is attached, articulating with the superior surface of the cuneiforme magnum. The *posterior surface* is very irregular, and has four smooth surfaces or facets, which articulate with the os calcis, the intervening portion being excavated and roughened. The *lateral surfaces*, the internal of which presents a small tubercle inferiorly, are roughened for the insertion of ligaments.

The astragalus articulates with the tibia, calcis, cuboid, and cuneiforme magnum; the true hock joint being that between it and the tibia.

The Os calcis (Pl. I. fig. 1, *c″*), which forms the prominent part, termed the point of the hock, and corresponds with the heel-bone of man, is situated immediately behind the astragalus, and presents a body and a tuberosity. The *body* is the inferior portion, which is flattened from before backwards, slightly convex externally, and unevenly concave internally, both surfaces being roughened. Anteriorly, it has four articular facets, which correspond with those on the astragalus, the interspaces being roughened for ligamentous attachment; posteriorly, it is convex

and smooth, for the passage of the flexor pedis tendon; inferiorly, it has two facets, which articulate with the cuboid; and superiorly, it is roughened and uneven.

The *tuberosity* is oblong, and flattened from side to side; its external surface being flat and rough; its internal, which forms the *tarsal arch*, smooth, to give passage to the extensor pedis tendon; its posterior border straight and rough, and its anterior border, shorter than the preceding, concave and rough. The superior extremity is expanded and rough above, to give insertion to the tendon of the gastrocnemius externus; posteriorly, it is covered with cartilage of incrustation, which forms a smooth surface, over which the tendon of the gastrocnemius internus glides; and anteriorly, is another small portion, covered with cartilage for the gastrocnemius externus to glide over during extreme flexion of the foot. A well-defined calcis, which acts as a lever, is a great point in a horse; it articulates with the astragalus and the cuboid.

The Os CUBOIDES (Pl. I, fig. 1, *c''*) is a small, very irregularly shaped bone, which occupies the outer part of the hock between the os calcis and the large and outer small metatarsal bones; it presents four surfaces—external, internal, superior, and inferior.

The *external surface* is convex, very rough and irregular, and gives attachment to ligaments; the *internal surface* has four articular facets, the two superior of which articulate with the large cuneiform, and the two inferior with the cuneiforme medium, the grooves between the upper and lower facets giving passage to blood-vessels. The *superior surface* is smooth, and possesses two articular facets, one large and irregular, to articulate with the os calcis, and the other, small and pear-shaped, to articulate with the astragalus; and the *inferior surface*, also smooth, has two articular facets, separated by a ridge, one flat, to articulate with the large metatarsal, and the other bevelled, to articulate with the outer small metatarsal.

The cuboid articulates with six bones, viz., the calcis and astragalus above, the cuneiforme magnum and medium anteriorly, and the large and external small metatarsals below.

The Os CUNEIFORME MAGNUM (Pl. I. fig. 1, *f''*), the bone on which the astragalus rests, is flattened from above below, and presents two surfaces and four borders. The *superior surface* is smooth, concave, and entirely articulatory, with the exception of a groove which runs from its outer surface to its middle, and gives insertion to a ligament. This surface articulates with the astragalus. The *inferior surface*, smooth and slightly convex, presents three articular facets, two of them, divided by a central groove, articulating with the medium, and the third, the most external, and separated from the others by a ridge, articulating with the parvum. The *anterior* and *internal lateral borders* are rough, for ligamentous attachment; the *external lateral border* has two facets, which articulate with the cuboid, the intervening portion being roughened for ligaments. The *posterior border*—the smallest—is irregular, and gives attachment to ligaments.

The large cuneiform articulates with four bones, viz., the astragalus, cuboid, and middle and small cuneiforms.

The Os CUNEIFORME MEDIUM (Pl. I. fig. 1, *g''*) is a somewhat triangular bone, a little less than the magnum underneath which it is placed; it is flattened from above below, and presents two surfaces and three borders.

The *superior surface* is concave, and presents two articular surfaces for the magnum, with a roughened transverse space between. The *inferior surface* is convex, and rests on, and articulates with, the large metatarsal. The *anterior border* is rough, for ligaments; the *external lateral border* has two facets, for articulation with the cuboid, and a roughened depression between; and the *internal lateral border* has one small facet, which articulates with the parvum, the remaining portion being excavated and roughened.

The middle cuneiform articulates with four bones, viz., the large and small cuneiform, the cuboid, and the large metatarsal.

The Os CUNEIFORME PARVUM (Pl. I. fig. 1, *h''*) is a very irregular bone, and the smallest in the hock, at the posterior internal part of which it is situated. It is sometimes divided into two parts,

and presents four surfaces and two extremities. Its *superior surface* is smooth and concave, to articulate with the magnum; and its inferior surface has two facets,—one very irregular, which articulates with the inner small metatarsal, and the other, the most anterior, square and bevelled, to articulate with the large metatarsal. Its *anterior surface* is roughened, as is the *posterior extremity*, and the *anterior extremity* presents a small semicircular articular facet for the medium, the remainder being roughened for ligaments.

The small cuneiform articulates with four bones, viz., the large and middle cuneiform, and the large and inner small metatarsal.

The Os METATARSI MAGNUM presents the same general appearances as the large metacarpal, from which it differs in being about one-sixth longer, and in being flattened from side to side, and rounded and more prominent anteriorly. It has three articular facets on its superior surface, a large one in the middle for the middle cuneiform, one on the inner side for the small cuneiform, and one on the outer side for the cuboid; this surface also presents a deep rough fossa of insertion in its centre. The deep groove which passes obliquely backwards and downwards on the external side of this bone is for the transit of an artery. The inferior extremity is larger and thicker than the superior.

The Ossa METATARSI PARVI also present the same general form as the small metacarpal bones; the external is the longest and largest, and has the largest head, and two facets which articulate with the cuboid; the inner has also two articular facets, one for the small, and the other for the middle cuneiform.

The remaining bones of the hind extremity, viz., the three phalanges, and with their three small accessory bones, so closely resemble the corresponding bones of the fore extremity, that it is difficult to distinguish the one from the other; the only differences being, that the first phalanx of the hind extremity is longer, its superior extremity larger, and its inferior extremity smaller, than that of the fore extremity. The second is longer, but not so broad transversely, and the third is more triangular

and more concave on its under surface, all these differences being very trifling in degree. The sesamoids and the navicular bone are almost identical.

The Skull.

The head of the horse, the most anterior part of the skeleton, is of an oblong shape, and articulates with the first cervical vertebra, from which it is suspended by its superior extremity, its inferior extremity being free. Its position varies according to the attitudes or movements of the animal; but, for the sake of description, we will suppose it to be placed in a horizontal position.

In the young animal, the skull is composed of a number of bones, all of which, with the exception of the lower jaw, become joined together by ossification in the adult; these bones, excluding the bones of the internal ear, and the teeth, which will be considered in another place, are thirty two in number, six of them being single bones, and the rest in pairs.

The head is divisible into two parts, viz., the cranium and the face, the division being marked by the transverse suture which runs from the lower angle of one orbital socket to the other.

The Cranium.

The *cranium*, which is very small in the horse when compared with the size of the body, forms the superior posterior part of the head; it is prominent and convex superiorly, flattened and irregular inferiorly, and hollow and vaulted within: the central cavity (cranial), which communicates posteriorly with the spinal canal, containing and affording protection to the brain. The bones of the cranium are—one occipital, two parietal, two frontal, two squamous temporal, two petrous temporal, one sphenoid, and one ethmoid.

The Occipital bone (Pl. I. fig. 1, *a*) which occupies the

superior posterior part of the head, is, in the young animal, at first divisible into four pieces, and afterwards into two, which, in the end, unite to form one bone; it is very irregular, and presents an external and an internal surface and four borders. The *external surface* is divided by a transverse mark into two portions, a super-occipital and a sub-occipital, which were originally two distinct pieces. The super-occipital portion, being very much exposed, is thick and strong; it terminates superiorly in a prominent crest, the *crest of the occiput*, which is convex anteriorly, and gives attachment to the forelock and complexus major, and descending from it, posterior inferiorly, is a sharp ridge, the *occipital tuberosity*, on each side of which there is a roughened depression, into which the ligamentum nuchæ is inserted. The *occipital* or *mastoid ridges*, continuous with the squamous temporal, descend from the crest on each side, and give attachment to the obliquus capitis superior muscles. The sub-occipital portion presents, immediately below the tuberosity, a large oval hole, through which pass the spinal cord to join the brain, the sub-occipital nerves, and the basilar artery. The sides of this foramen, the transverse diameter of which is the largest, are roughened for the attachment of the long odontoid ligaments, and on each side is a large rounded prominence, the *condyle*, which is smooth, to articulate with the atlas. A large process, the *basilar process*, passes forwards from the lower part of the condyles, and forms the floor of the foramen magnum; it is flattened above, rounded below, articulates with the sphenoid in front, gives attachment to the rectus capitis anticus muscles, and has a fissure, the *basilar fissure*, running along its under surface, to terminate posteriorly in the foramen magnum. Two flattened processes, the *styloid* or *coracoid*, extend downwards from the sides of the bone, and give attachment to the obliquus capitis anticus, stylo-maxillaris, and stylo-hyoideus muscles; and between these processes and the condyles is a deep notch, the *condyloid* or *stylo-condyloid notch*, at the bottom of which, and just in front of the condyles, are the *condyloid foramina*, which give passage to the lingual nerves.

The *internal*, or *cerebral surface*, has, in the super-occipital portion, a vaulted concavity, termed the *occipital cupola*, which covers the cerebellum and the superior anterior surface of the basilar process presents a pit, the *basilar fossa*, in which the pons varolii lies in the anterior part, and the medulla oblongata in the posterior part. The small foramina which enter the basilar process from within the foramina magnum are for the passage of nutrient blood-vessels.

The superior border is serrated, and articulates with the parietal bone; the anterior border articulates with the parietal, and the lateral borders with the petrous temporal bones.

The Parietal bones (Pl. I. fig. 1, *c*) are situated at the superior posterior and lateral parts of the cranium, of which they form the walls and part of the roof. The parietal is a large thin bone, possessed of an external and an internal surface, and four borders.

The *external surface* is convex and smooth. On each side of the sagittal suture, formed by the junction of the two bones, there is a curved ridge, to which the temporalis muscle is attached; these ridges, together, form a triangle, the apex of which joins the occipital crest. The lateral parts of this surface are roughened, to articulate with the squamous temporal bone.

The *internal surface* is concave, and marked by numerous vascular grooves and indentations, which correspond with the convolutions of the brain. A crest, forming a groove, sometimes replaced by a groove, termed the *longitudinal groove*, runs along the junction of the two bones, and gives lodgment to the longitudinal sinus of the dura mater; this crest terminates posteriorly in a three-sided process, the *parietal protuberance* or *ossific tentorium*, to which, as well as to the crest, is attached the falciform process of the dura mater. In front of this process, the longitudinal groove ends in two transverse grooves, which lodge the transverse sinuses of the dura mater, and are continued down to the parieto-temporal conduit.

The *posterior border* of this bone is thick and denticulated, and articulates with the occipital; the *anterior border* is slightly

concave and strongly serrated, and articulates with the frontal; the *internal border* is denticulated, and united to its fellow of the opposite side; and the *external border* is divided by a prominent angle into two parts, the anterior one being thin, and articulating with the squamous temporal, and the posterior thicker, and articulating with the petrous temporal—the prominent angle or crest meeting with the sphenoid.

Sometimes the sagittal suture, formed by the union of the two bones, is interrupted or rendered bifid posteriorly by the insertion of a small bone, generally triangular in shape, and hence called the *os triquetra*, or *os Wormiana* (Pl. I. fig. 1, *b*). The ossific tentorium springs from this bone when present.

The FRONTAL BONES (Pl. I. fig. 1, *d*) are situated at the anterior superior part of the cranium, and constitute the broad, flat part called the forehead; their union in the centre of the forehead forms the *frontal suture*.

The frontal bone is irregular in shape, flat externally, smooth and concave internally, and presents external and internal surfaces and four borders.

The *external surface* is somewhat prominent above, and slightly depressed below, and has a lateral process, the *external orbital*, which projects downwards and slightly backwards, is convex externally and concave internally, and forms part of the orbital socket, its articulation with the zygomatic process of the squamous temporal forming the frontal arch. The foramen, piercing the superior part of this process, is the supra-orbital which transmits the artery, vein, and nerve of the same name. The thin plate which extends downwards and backwards from the external lateral border of the bone, is the *internal orbital late* or *process*, divided by a large triangular notch, the *incisura ethmoidalis*, into which the wing of the ethmoid is received; and the small notch in front of the large one enters, with the sphenoid, into the formation of the orbital foramen. The pit or hollow above the larger notch lodges the lachrymal gland; and the small depression at the base of the external

orbital process is for the insertion of the greater oblique musc of the eye. The slightly depressed part behind the orbit process forms the anterior part of the temporal fossa.

The *internal surface* is concave, and divided into two unequa parts by a bony septum, which meets the cribriform plates the ethmoid. The posterior of these parts is smooth, and marke by ridges, which correspond with the convolutions of the brai the anterior lobe of which it covers, and furrows for the anterio meningeal artery. The continuation of the longitudinal groov of the parietal runs along the mesian line; and at each side separating the bone from the inner surface of the orbital plat is a circular groove, into which the wing of the sphenoid i received. The anterior concavities form the frontal sinus which is separated from its fellow by a prominence termed th nasal spine, on the posterior part of which is a rounded surfac on which the crista galli of the ethmoid rests. These sinuses which contain air, and are larger in the adult than in the youn animal, are partially divided by imperfect septa, which ru across their interior; they are lined with mucous membran and have connection with the nostrils.

The *posterior border* is divided into two parts, both of whic are denticulated, the superior part articulating with the parieta and the inferior or descending part being overlapped by th squamous temporal. The *anterior border* is pointed in it middle, and articulates partly with the nasal and partly wit the lachrymal bones. The *internal border* is straight an triangular, the widest part being at the septum; it joins it fellow. The *outer* and *inferior border* is very irregular, an articulates with the sphenoid and lachrymal.

The Temporal bones (Pl. I. fig. 1, *c*), situated at the sid of the cranium, are divided in the horse into two distinct piece named the *squamous temporal* and the *petrous temporal*.

The Squamous temporal (scale-like) is oval, flattened fro side to side, and slightly curved. It has an external, or auricula and an internal, or cerebral, surface, and a circumferent border

The *external surface* is convex and rough, presenting numerous small foramina, which penetrate into the parieto-temporal conduit. Projecting outwards and forwards from its middle is a long, twisted process, the *zygomatic*, which unites with a similar process of the malar, the two forming the *zygomatic arch*, on which the frontal arch abuts superiorly. Posterior to this abutment is a broad concave surface, which forms the inferior part of the temporal fossa; and projecting upwards from the posterior part of the fossa is the sharp *zygomatic* spine. The shallow transverse concavity on the inferior face of the zygomatic process is the *glenoid cavity*, into which the condyle of the lower jaw fits and articulates; and bounding this cavity, anteriorly, is an articular ridge, the condyle, which forms part of the temporo-maxillary articulation, and, posteriorly, the *anterior mastoid process*, which limits the motion of the articulation, and gives attachment to one of the tendons of the levator humeri. The *mastoid foramen* is at the base of the process. Posteriorly, the bone diverges, the inferior portion being beaked, and clasping the external auditory meatus of the petrous temporal, and the other extending backwards, to articulate with the occipital, and complete the occipital ridge.

The *internal surface* is divided into two portions by a deep channel, which forms, with the parietal and petrous temporal, the *temporal* or *parieto-temporal conduit*. The posterior portion articulates with the petrous temporal; and the anterior and larger portion, the centre of which forms part of the wall of the cerebral cavity, is marked with imprints similar to the internal surface of the parietal and frontal bones, the remainder of this portion being denticulated, to articulate with the parietal and sphenoid bones.

The circumference is denticulated, and articulates with the petrous portion, and with the parietal, occipital, frontal, sphenoid, malar, and lower jaw.

The PETROUS TEMPORAL is the hardest bone in the skeleton, and is interesting as containing the internal and essential organs

of hearing. It is a very irregular bone, somewhat pyramidal i shape, the base being turned upwards and a little backward and is placed at the posterior lateral part of the cranium, b tween the anterior portion of the occipital, the lateral border the parietal, and the internal surface of the squamous. I presents anterior, posterior, external, and internal surfaces, summit, and a base.

The *anterior surface* is divided into two portions, the superio being roughened, and articulating, by harmony, with the parie tal, and the inferior and lesser portion smooth, and forming th posterior part of the concavity for the posterior lobes of th cerebrum. The *posterior surface* is triangular and rough, an articulates, by harmony, with the occipital. The *external sur face*, also triangular, is divided into two parts, the inner articulat ing with the squamous temporal, and the outer being interpose between the occipital ridge and the styloid process of the occ pital. The *internal surface*, which forms the lateral boundar of the cavity of the cerebellum, is slightly concave, and present several depressions, and, anteriorly, a large orifice or conduit the *internal auditory meatus* – a short canal through which th auditory and facial nerves have passage, and which is divide by a thin plate into two portions, one of them leading, by smal foramina, to the vestibule and cochlea, the other being the origi of the *aqueduct of Fallopius*, which, after taking a spiral cours through the bone, terminates externally at the stylo-mastoi foramen. A narrow slit, the *aqueduct of the vestibule*, close t the meatus, transmits a small vein and artery, and lodges process of dura mater.

The four surfaces are separated by four borders or angles, tw of which deserve notice, – the first, separating the external fro the posterior surface, which is thick and rough, and forms th *mastoid ridge*, which is continuous, backward, with the occipit ridge, and has the *anterior mastoid process* in front ; the *mastoi fissure*, which terminates in the foramen lacerum basis crani runs across this angle. The second, separating the anterior fro

the internal surface, marks the division between the cavities of the cerebrum and cerebellum, and has a process of dura mater attached.

The *summit* of the bone is pointed and articulates with the occipital; the *base* is very irregular in outline, and presents a large opening, the *external auditory meatus*, which penetrates to the middle ear, and is surrounded by an oval rim of bone, the *external auditory process*, which is notched in the middle, and gives attachment to the cartilages of the ear. Below this opening, is the *hyoid process*, which articulates with the hyoid bone, between which and the mastoid process is the *stylo-mastoid foramen*, the external opening of the aqueduct of Fallopius. The rounded part immediately below the hyoid process is the *mastoid protuberance*, containing the mastoid cells, at the base of which, projecting forwards, is the long and slender *styloid process*, which gives attachment to muscles, the *styloid foramen* for the chorda tympani being above it, and the opening of the Eustachian tube below.

The SPHENOID, or wedge-bone, is a single bone situated in the middle and anterior parts of the base of the cranium, between the occipital, ethmoid, palatine, vomer, pterygoid, frontal and temporal, with all of which it articulates. Its shape is generally likened to a bird in flight with its legs and wings extended; it presents for consideration a body, two wings, and two legs or pterygoid processes.

The *body* is cylindroid in form, convex inferiorly, and roughened for muscular attachments. At each side, anteriorly, is the Vidian fissure, which the palate bone converts into a small canal—the Vidian, through which the nerve of that name passes to join the spheno-palatine ganglion. Above this fissure, and passing through the base of the pterygoid processes, is the large *pterygoid foramen*, which gives passage to the internal maxillary artery; and, in front of the processes, a large irregular opening, the *external orbital hiatus*, into which the superior post orbital, the inferior post orbital, and pterygoid foramina open. Still

more anteriorly, is the external opening of the optic foramen and, at the anterior border of the body, a notch, which enter into the formation of the internal orbital foramen, and give passage to the nasal branches of the superior maxillary arter and of the fifth pair of nerves.

The *internal*, or *superior*, *surface* of the body is smooth, an presents, in the centre, a shallow fossa, the *pituitary fossa* o *sella turcica*, in which the pituitary gland is lodged; in front c the sella turcica is a slight elevation, the *olivary process*, whic supports the commissures of the optic nerve, and behind it a fla place for the pons Varolii. On each side of the superior part c the body are two shallow grooves, the internal being the *cavern ous fossa*, along which pass the ophthalmic artery, vein, an nerve, and the third and sixth nerves; and external, which is th larger and deeper, being the *sphenoidal fossa*, which transmit the superior maxillary division of the fifth nerve. In front c these lateral grooves, two foramina open into the external orbit hiatus, the innermost being the *foramen lacerum orbitale*, whic outwardly forms the superior post orbital, for the ophthalmi artery, vein, and nerve, and the third and sixth nerves; th inferior being divided into two imperfect foramina, of which th internal is the *foramen rotundum* for the passage of the superic maxillary division of the fifth, and forming, outwardly, th inferior post orbital foramen. Above these the *foramen patheti* gives passage to the fourth nerve.

Immediately in front of the olivary process is the *optic hiatu* which leads to the two optic foramina for the optic nerves an the arteria centralis retinæ; and in the anterior part of the boc is a sharp process which articulates with crista galli of the ethmoi A concavity on each of the sides of the anterior part of the boc contains the olfactory bulb.

The *wings* project outwards and upwards; their internal su faces are smooth, and enter into the formation of the later walls of the cranium, the posterior part being hollowed for th mastoid lobes of the cerebrum. The external surfaces of th

wings are convex anteriorly, where they join the frontal to form the orbital sockets, and rough posteriorly, where they articulate with the squamous temporal. The *pterygoid processes* project downwards and forwards, are broad and flat, and articulate with the vomer and palatine bones.

The *posterior border* of the body articulates with the basilar process of the occipital. The irregular portion above the body enters into the formation of the foramen lacerum basis cranii; in this there are two grooves—an internal, the *carotid notch*, which gives passage to the internal carotid artery, and is continued under the body of the bone, and an external, which transmits the inferior maxillary nerve.

The *anterior face* of the body of the bone presents two deep cavities separated by a thin bony plate, sometimes perforated, which is continuous with the perpendicular plate of the ethmoid; these cavities are the *sphenoidal cells* or *sinuses*.

The ETHMOID, or sieve bone, is placed between the frontal, sphenoid, vomer, palatine, and superior maxillary bones, and divides the face from the cranium; it presents a perpendicular plate and two lateral portions.

The perpendicular plate (lamella), continuous with the cartilaginous septum of the nose, is covered with pituitary membrane, and divides the frontal and sphenoidal sinuses, and joins the vomer below. Posteriorly, it forms the *crista galli process*, which projects upwards in front of the cranial cavity, is narrow inferiorly, where it joins the sphenoid, and broad superiorly, where it supports the frontal bone.

The *ethmoid cells* constitute the lateral parts of the ethmoid. These are numerous and very fragile plates of bone rolled up into conchæ, and attached to transverse plates. The *cribriform plates*, which are perforated for the passage of nerves, separate the cranial from the nasal cavities. The concave posterior parts form the *ethmoidal fossæ*.

The Face.

The face is the elongated, inferior, and anterior part of the head, much larger than the cranium in most of the domestic animals, and in the horse constituting four-fifths of the entire skull. It consists of two parts, the superior maxilla or upper jaw (syncranium), and the inferior maxilla or lower jaw (diacranium), each of which is an apparatus for the support of the passive organs of mastication, the teeth. The upper jaw is traversed by the nasal cavities, which, in the living animal, contain the organs of smell, and is formed of nineteen distinct bones, one only of which, the vomer, is single, the remainder, viz., the nasal, superior maxillary, inter-maxillary, malar, lachrymal, palatine, pterygoid, superior turbinated, and inferior turbinated, being in pairs. The lower jaw contains a single bone, the inferior maxillary.

The Nasal bones (Pl. I. fig. 1, *h*) are situated at the superior anterior part of the face, immediately below the frontal, and between it and the lachrymal and superior maxillary. They are long slender bones, flattened from above downwards, somewhat triangular in form, and heart-shaped when together. A nasal bone presents two surfaces, two borders, a base, and an apex.

The *superior* or *external surface* is smooth, convex from one side to the other, and larger above than below. The *internal surface* is concave, and forms the nasal fossa; a vertical ridge to which the superior turbinated bone is attached, runs along its external border; posteriorly this ridge bifurcates, and behind and between the bifurcations is a concave surface, which forms the *nasal* or anterior portion of the frontal sinus. Above this ridge the surface is smooth, and forms a gutter, the *superior nasal meatus*, and along the inner border is a slight ridge, which combines with that of the opposite bone to form a groove for the septum nasi.

The *internal border* is straight and dentated, and articulates

with its fellow. The *external border* is very thin and waving, dentated in its upper two-thirds to articulate with the lachrymal, superior maxillary, and posterior part of inter-maxillary bones, the remaining part being free, so as to leave an angular opening, the *nares*, between it and the inter-maxillary bone. The *base* or *superior border* is rounded, serrated, and unites with the frontal; the *apex* is sharp and pointed, the two forming the nasal peak.

The nasal bone articulates with the frontal, superior maxillary, inter-maxillary, lachrymal, and opposing nasal bones, and has the superior turbinated bone attached to its inner surface.

The SUPERIOR MAXILLARY BONE (Pl. I. fig. 1, *i*), situated at the side of the face, is the largest bone of the syncranium, very irregular in form, and elongated from before backwards. It presents three surfaces, three borders, and two extremities.

The *external* or *facial surface*, concavo-convex in the adult, and nearly convex in the young animal, is nearly smooth, with an elongated horizontal ridge, the *maxillary spine*, continuous with the zygomatic spine of the malar, which commences opposite the third molar tooth, and runs along the middle line of the posterior part of the surface. Near the middle of the upper surface is the infra orbital foramen, through which the facial division of the fifth nerve and a branch of the lateral nasal artery pass. The *inferior* or *palatine* surface, slightly hollowed from side to side, consists of a bony plate, the *palatine process*, which forms the partition between the nose and the mouth; it contains numerous small grooves and foramina, and one deep groove, the *palatine*, bounded by the alveolar processes of the molar teeth, which runs the whole length of the surface, near its outer edge, and gives passage to the palatine artery. The *internal* or *nasal surface* forms the sides and floor of the nasal cavity; it is irregularly concave, smooth, and divided into two incavities by a longitudinal ridge, the *internal maxillary spine*, which the inferior turbinated bone is attached. At the posterior part of this surface is a large, deep excavation, the *maxil-*

lary sinus, below which is a serrated surface, articulating wit the palatine bone, in which is a fissure, which, with a co responding fissure in the palatine bone, forms the *palatin foramen*. A little anterior to the sinus is the opening of th lachrymal conduit, which is continued by a shallow fissure t the anterior extremity of the bone; along this conduit and fissu passes the lachrymal duct which conveys the tears from the eye to the nasal chambers.

The *superior border* is thin, convex, and divided into tw parts: an anterior, grooved and serrated for the insertion of th external border of nasal, and inferior part of the inter-maxillary bones, and a posterior, which is sloped to articulate with th lachrymal and malar bones. The *inferior border* is very thick and divided into six quadrilateral cavities, termed *alveoli*, int which the molar teeth are implanted. At the back of the las alveolus is a rough eminence, the *alveolar tuberosity*, and in fron of the first the border becomes thin and sharp, and forms portion of the *interdental space* which separates the molar fro the incisor teeth. The *internal border* is serrated to articulat with its fellow of the opposite side, and notched anteriorly t form the incisive opening, and posteriorly to articulate with th palatine.

The *posterior extremity* is round and prominent, forming th *maxillary tuberosity*, in the interior of which the maxillar sinus is prolonged. At the inner side of this eminence is large deep excavation, which the palatine bone assists to for into the *maxillary hiatus*. This hiatus is situated directl opposite to the external orbital hiatus, and contains three for mina, viz.—1*st*, the *anterior palatine* or *palato-maxillary*, whic leads to the palatine conduit, for the passage of the palatin artery; 2*d*, the *posterior maxillary* or *dental*, which enters th maxillary sinus, is continued along the roots of the molar teeth and terminates in two branches—a large short one, which oper at the infra orbital foramen, and another continued through th whole length of the bone; the 3*d* is the *posterior palatine*

spheno-palatine, which enters the nasal cavity, and gives passage to the spheno-palatine artery, vein, and nerve. The *anterior extremity* presents a cavity which, with a similar cavity in the inter-maxillary with which it articulates, forms the socket of the tusk.

The superior maxillary articulates with its fellow, and with the inter-maxillary, nasal, palatine, frontal, malar, lachrymal, and squamous temporal bones.

The INTER or ANTERIOR MAXILLARY BONE (Pl. I. fig. 1, *k*) is situated at the anterior extremity of the face, and consists of a broad thick part, and two processes which spring from it. The thick part or *base* presents three surfaces—an *external* or *labial*, which is smooth and convex; an *internal*, which is denticulated to articulate with its fellow, and has a groove running down it, which, with that of the opposing bone, forms the foramen incisivum for the passage of the palatine artery; and an *inferior* or *buccal*, which is smooth and slightly concave, and presents a continuation of the palatine groove, which terminates in the foramen incisivum. Between the external and inferior surfaces is a very thick curved border, which presents anteriorly three alveoli for the incisor teeth, behind which is a sharp portion which completes the interdental space. At the posterior part of the border is a cavity which, with that on the anterior extremity of the superior maxillary bone, completes the socket for the tusk.

The *processes* are distinguished as external and internal. The *external*, the largest and longest, is continuous with the base, and flattened from side to side. Its outer surface is convex and smooth, and its inner rounded and covered by the mucous membrane of the nose; inferiorly it is dentated to articulate with the superior maxillary; and its posterior extremity is thin, and inserted between the superior maxillary and nasal bones. The *internal* or *palatine processes* are thin flexible plates of bone, which join each other internally by dentated borders; they partly fill up the interdental opening; their superior surface forms part of the nasal floor, and their inferior part, which is smooth, enters into the formation of the hard palate.

The inter maxillary bones are joined by fibro-cartilage in the young animal and by ossification in the old, the junction forming the *symphysis*. Each inter maxillary articulates with its fellow and with the superior maxillary and nasal bones.

The Malar, Zygomatic, or Jugal bone (Pl. I. fig. 1, *f*) situated at the inferior and posterior part of the orbital fossa, is flattened from side to side, and irregularly triangular in shape with a broad triangular anterior part, which ends in a sharpened posterior point. It presents for consideration three surfaces, a base, and a summit.

The *external* or *facial surface* is smooth and convex, and has inferiorly, a sharp ridge, the *zygomatic ridge*, and, posteriorly, a process, the *zygomatic process*, which meets the process of the same name of the squamous temporal, the two forming the zygomatic arch. The *internal* or *maxillary surface* is irregularly concave, the centre entering into the formation of the maxillary sinus, the other portion being denticulated to articulate with the superior maxillary. The *superior* or *orbital surface* is concave and forms the posterior inferior part of the orbital socket, the border which separates it from the external surface being the orbital ridge. The *base* is thin, and articulates with the superior maxillary, and above the base is a serrated border, which articulates with the lachrymal. The *summit* is pointed, and unites with the zygomatic process of the squamous temporal.

The malar articulates with the superior maxillary, lachrymal and squamous temporal bones.

The Lachrymal bone (os unguis) (Pl. I. fig. 1, *g*), situated at the anterior inferior part of the orbital fossa, of which it forms a part, is an irregular bone, very thin and very light, and presents three surfaces and a circumference.

The *external* or *facial surface* is triangular, slightly convex and bounded, superiorly, by the orbital ridge, in the middle of which is an eminence, the *lachrymal tubercle*, to which the orbicularis palpebrarum is attached. The *superior* or *orbital surface* also triangular, is concave and smooth; it presents, near its

centre, a funnel-shaped cavity, the *lachrymal fossa*, which leads to the lachrymal canal, and gives lodgment to the lachrymal sac. The lesser oblique muscle of the eye is inserted in a slight depression at the inner side of this cavity. The *internal surface* is divided by the prominent walls of the lachrymal canal into two concavities, which form part of the roof of the maxillary sinus. The circumference is very rough, and denticulated for articulating with the frontal, nasal, superior maxillary, and malar bones.

The PALATINE BONE is situated at the superior part of the palate, between the posterior parts of the superior maxillary, and forms the anterior and lateral boundaries of the posterior nares. It is a long narrow bone, flattened from side to side, and curved inwards anteriorly, to meet the opposite palate bone, where it becomes flattened from above downwards. It presents four surfaces and two extremities.

The *external* or *orbital surface* is smooth posteriorly, where it forms part of the orbital fossa, and aids in the formation of the maxillary hiatus, denticulated anteriorly, where it articulates with the superior maxillary. Superior-posteriorly, it presents a shallow groove, running obliquely downwards and forwards, and terminating in the palatine surface, which, with a small groove in the alveolar tuberosity of the superior maxillary, forms the *staphyline foramen* for the passage of the staphyline artery, vein, and nerve to the palatine arch. In the centre, also running obliquely downwards and forwards, is a deep groove, which, with a similar groove in the superior maxillary, forms the palatine canal, which terminates in the palatine foramen. The spheno-palatine foramen is in its superior middle. The *inferior* or *palatine surface* is smooth, very narrow, and concave, and enters into the formation of the palatine arch. The *internal* or *nasal surface* is smooth and concave, the anterior portion being narrow, and hooked to meet its fellow, and the posterior part broad, and presenting a roughened line, which runs obliquely from above downwards for the attachment of the pterygoid. The *superior* or *ethmoidal surface* is deeply excavated, and con-

stitutes the floor of the ethmoidal sinuses. The sharp ridge between this and the nasal surface is the *palatine crest*, on which the vomer rests.

The *anterior extremity* is flat, and recurved inwards to meet the opposing palatine bone and palatine process of the superior maxillary. The *base* is very thin and sharp, and presents a groove, in which the pterygoid process of the sphenoid articulates.

The space between these bones forms the opening between the nose and the palate, the borders of the opening giving attachment to the velum pendulum palati.

The palatine articulates with its fellow, and with the superior maxillary, vomer, pterygoid, sphenoid, ethmoid, and inferior turbinated bones.

The PTERYGOID is a very small elongated bone, flattened from side to side and slightly twisted, situated on the inner side of the pterygoid processes of the sphenoid and posterior part of the nasal surface of the palatine, and below the posterior part of the vomer. It presents two surfaces and two extremities.

The *external surface* articulates with the palatine bone and pterygoid processes of the sphenoid; the *internal surface* is smooth, and covered by the pharyngeal mucous membrane; the *posterior extremity* is very slender, and assists in forming the Vidian conduit; the *anterior extremity* possesses a blunt process; the *summit*, which is free, is directed downwards and backwards, and has a groove forming a pulley at its extremity through which the tendon of the tensor palati muscle plays.

The VOMER, or coulter, the only single bone in the superior maxilla, is a long bone constructed of two thin plates, with a deep groove between, and extends along the middle line of the floor of the nasal chambers from the sphenoid to the inter-maxillary bone. It presents two surfaces, two borders, and two extremities.

The two *surfaces*, lateral, narrow anteriorly and wider posteriorly, are smooth, and covered by mucous membrane. The *superior border* is deeply grooved for the reception of the carti-

aginous septum of the nose; the *inferior border* is sharp and smooth in its posterior half, where it forms the division between the posterior nares; the remaining portion is broad, flat, and slightly dentated to articulate with the maxillary bones. The *posterior extremity* is broad from side to side, convex below, and concave above, where it opens out into a crescentic border, which embraces the sphenoid, and forms an irregular hiatus between the two bones for the passage of the nerves and blood-vessels which supply the septum. The *anterior extremity* is flat, and rests on the palatine process of the inter-maxillary bones.

The vomer articulates with the sphenoid, ethmoid, palatine, pterygoid, and superior and inter-maxillary bones.

The TURBINATED BONES, four in number, two superior and two inferior on each side, are found in the nasal chambers, and form the irregular bony columns, larger posteriorly than anteriorly, flattened from side to side, and hollowed within, and divide the nasal passages into superior, middle, and inferior meati.

The *superior* or *ethmoidal turbinated bones* are attached to the ridge on the nasal bone and to the ethmoid; and the *inferior* or *maxillary turbinated bones* to the ridge on the superior maxillary bone. They are constructed of delicate, reticulated shells, are oval in shape, convoluted in the manner of a turban, and cavernous within. The *superior* is the larger of the two, and extends from the ethmoid to near the external opening of the nose: a transverse plate divides its anterior into two portions, of which the posterior is continuous with the frontal sinus, and the anterior with the nose. The convolutions of this bone are from below upwards. The *inferior* bone is convoluted from above downwards, and its interior connected with the inferior maxillary sinus.

The use of the turbinated bones is to augment the surface of the nasal chambers over which the olfactory nerves are distributed, and, by their lightness, not add materially to the weight. The *superior meatus* of the nasal fossa is between the upper bone and the roof of the nose; the *middle meatus* is

between the two bones, and the *inferior meatus* between th lower bone and the floor of the nose.

The Inferior maxillary (Pl. I. fig. I, *l*), or lower jaw, is large, irregular, somewhat V-shaped bone, situated below th upper jaw, and articulating, by means of a true joint, with th glenoid fossæ of the squamous temporal. It is constructed b two symmetrical branches, flattened from one side to the othe and wider posteriorly than anteriorly, the posterior portion bein recurved upwards and opened out, and the anterior extremitie united, and leaving a triangular space (maxillary) between These branches, united in the adult, constitute two distinc pieces in the fœtus, each of which presents for consideration tw surfaces, two borders, and two extremities.

The *external surface* is smooth and rounded anteriorly, an grows gradually deeper as it proceeds backwards; the posterio part or recurved portion is roughened and excavated for th attachment of the masseter muscle. The *internal surface* i roughened and hollowed posteriorly, for the attachment of th pterygoid muscle, and presents a large foramen (dental or pos terior maxillary) leading to the dental canal which passes through the bone below the roots of the molar teeth. The anterior par of this surface is smooth and flat, and presents a groove for th attachment of the buccal membrane; below the groove, th muscles of the glosso-hyoid region are attached.

The *superior border* presents a straight portion anteriorly, and a concave portion posteriorly; the first is divided into six alveoli for the lower molars, and the second, which terminates in the coronoid process, is thin, and roughened for muscular insertion. The *inferior border* is also divided into two portions, a straight and a convex one, separated by a part termed the *angle of the jaw*. The anterior portion is rounded in the young animal, but grows gradually thinner as it increases in age, owing to the outward growth of the teeth; the posterior half is thin, and terminates in the condyles.

The *posterior extremity* presents two eminences, a flat, thin,

pointed one, the *coronoid process*, anteriorly, and a transversely double convex one, the *condyle*, posteriorly, the two being separated by a deep notch, the *sigmoid* or *corono-condyloid*. The *anterior extremities*, joined at the symphysis maxillare, form the *body* of the bone. The *external* or *labial surface* of the body is convex, and gives attachment to the gums and levator menti muscles, and has a line down its middle, which marks the division of the fœtal bone. The *internal* or *buccal surface*, less than the external, is smooth and concave; the frænum of the tongue is attached to its superior part. The *superior surface* is divided in the centre by bony septa into alveolar cavities for the incisor teeth; and on each side, near the neck, it presents a cavity for the tushes. The *neck* is the constricted portion which joins the body to the ramus; it has a sharp ridge, the *interdental space*, superiorly, which gradually disappears as the animal is used. On the outer side of the neck, is the *anterior maxillary, mental*, or *labial foramen*, the termination of the dental canal which transmits the facial branches of the dental artery and of the inferior maxillary division of the fifth pair of nerves.

The Os HYOIDES (os linguæ, or tongue bone, the bone which supports the tongue, the pharynx and the larynx) is suspended from the base of the cranium in an oblique direction downwards and forwards between the branches of the lower jaw, its connection being by means of fibro-cartilage with the hyoid process of the temporal bone. It is very irregular in form, is constructed of five distinct pieces, and, for the convenience of description, divided into a body and two cornua or horns, two greater and two lesser.

The body bears a striking resemblance to a spur or two-pronged fork, and presents a rounded portion from which spring two lateral processes, the heels, directed backwards and upwards, their three extremities articulating with the thyroid cartilage of the larynx. The two convex articular facets, where these processes join the middle rounded portion, are for the lesser cornua.

Springing from the middle portion, anteriorly, is a long, flat sharpened process, the *appendix* or *spur process*, which is buried in the substance of the tongue. The *inferior* or *lesser* cornua are two short cylindrical pieces, articular at both extremities, the inferior (concave) for the body, and the superior for the greater cornua.

The greater cornua consist of two long, thin, flattened bones, which extend obliquely backwards and upwards. The anterior extremity of each cornu presents an articulation for the corresponding lesser cornu, while the posterior extremity terminates in a blunt surface of a triangular shape, the inferior angle of which is sharp and rounded, and the superior round. This blunt surface on the posterior extremity of the cornu is united to the petrous temporal bone by a cylinder of fibro-cartilage. Several small muscles are attached to the flattened lateral surfaces of this bone.

Occasionally, rudimentary third cornua are found in the cartilage which joins the greater and lesser cornua.

The Skull as a Whole.

The bones of the head are united to each other by means of sutures, the chief varieties of which are the serrated, squamous, and harmonia.

The *serrated suture* is formed by the union of two borders with serrated edges, the *squamous* by the bevelled edge of one bone overlapping that of another, and the *harmonia* by the simple apposition of contiguous surfaces. In the serrated sutures the serrations are formed only on the external plate of the bone, the internal plate, as a rule, lying merely in apposition.

The principal sutures of the head are the *longitudinal*, which extends from the occipital bone to the nasal peak, and divides the head into two lateral halves. This suture is subdivided into the *nasal*, which is open at the apex, the *frontal*, and the *inter-parietal* or *saggital*. Between the nasal and lachryma

bones and the frontal is the *transverse* or *fronto-nasal* suture, which divides the face from the cranium; the *coronal suture* extends obliquely upwards and backwards from the orbital process to the vertex between the frontal and parietal bones; and the *lambdoidal suture* runs upwards from the superior angle of the temporal bone to the saggital suture between the parietal and occipital bones.

The union of the bones of the head and face forms a quadrangular pyramid, hollowed out into several cavities or chambers, and divisible, externally, into anterior, posterior, and lateral surfaces, a base, and an apex.

The *anterior surface* is formed by the parietal, frontal, and nasal bones; superiorly, it inclines backwards, and, at each side of the parietal edges, bulges into swollen surfaces which bound the temporal fossa. The remainder of this surface is flat, and forms the forehead, its greatest width being at the middle of the frontal bone, after which it gradually decreases to the nasal peak.

The *posterior surface* is very irregular, and presents, at its upper part, the basilar process, the foramen lacerum basis cranii, and the base of the petrous temporal bone. In the front of the basilar process is the intermaxillary space, in which are the sphenoid, the Vidian fissure, the superior orifice of the sub-sphenoidal foramen, the process of the same name, the palatine ridges, the pterygoids, the posterior nares, divided by the posterior border of the vomer, the arch of the palate, the interdental space, and the foramen incisivum.

The *lateral surfaces* exhibit, posteriorly, the external face of the rami of the submaxillary bone, and, anteriorly, a triangular space more or less convex, sometimes hollowed in old animals, presenting the infra orbital foramen in its centre, and forming the base of the lateral parts of the forehead. Above these, are the crest of the zygomatic arch, the orbit, and the temporal fossa.

The *orbit* is a conical cavity, the oval entrance of which is circumscribed by the orbital protuberance of the frontal, the

lachrymal, the malar, and the upper part of the zygomatic process of the temporal; the cavity being formed by, in addition to these, the superior maxillary, the palatine, and the wing of the sphenoid. At its further end are the maxillary hiatus, which leads to the lateral nasal, the palatine, and the superior dental foramina, and the orbital hiatus, containing the optic, pathetic, lacerated, and round foramina. This cavity, designed for the globe of the eye and the muscles by which it is moved, gives lodgment also to the lachrymal gland and the membrana nictitans, accessories to the organ of vision, and a quantity of adipose tissue, besides vascular and nervous trunks.

The *temporal fossa* surmounts the orbit, from which it is incompletely separated by the orbital process, complete separation of these cavities by a wall of bone being only found in man and the quadrumana. It is oval in shape, situated on the side of the head in an oblique direction, from above downwards and from within outwards, and is bounded internally by the parietal crest, and externally by the anterior edge of the longitudinal root of the zygomatic process. It lodges the temporal muscle and contains many foramina which penetrate the parieto-temporal canal.

The *base* or *superior part of the head* presents the occipital process, the cervical tuberosity, the foramen magnum, the mastoid crests and fissures, the styloid processes of the occipital, the condyloid notches, the condyles, and, lower and further back, the curved portion of the borders of the lower jaw.

The *apex*, formed by the anterior and body of the inferior maxillary bones, supports the incisor teeth, and is more or less rounded, according to the age of the animal. In front, it is surmounted by the external opening of the nasal cavities; this opening, included between the external process of the anterior maxillary and the nasal spine, is divided, in the recent subject, into two orifices, which constitute the anterior nares.

The skull contains internally the *cranial cavity*, the *nasal fossæ*, and the *sinuses*, which are appendages to the latter.

The Cranial cavity is an extremely irregular ovoid box, the walls of which are formed of the frontal, the parietal, the occipital, and the temporal bones. For the purpose of description, it may be regarded as being divisible into a roof, a base or inferior plane, two lateral planes, and two ends.

The *roof* presents, towards its posterior third, in the median line, the occipital protuberance, which, with the two lateral crests (parieto-temporal) which spring from it, assists in dividing the cranial cavity into two compartments,—a posterior, for the cerebellum, and an anterior, considerably larger, for the cerebrum. Along the median line, from the falciform eminence to the crista galli process, runs a groove for the longitudinal sinus, the roughened elevated borders of which form a rudimentary crest, which supports the falx cerebri, and divides the compartment into two lateral sections, one for each hemisphere. Folds of dura mater attached to the protuberance, and lateral crests, also help to render the partitioning of the cavity more perfect.

The *lateral planes* are concave, and, like the roof, marked with numerous vascular grooves and digital impressions. They assist in the division into cerebral and cerebellar compartments by means of the lateral crests of the falciform process, which are prolonged obliquely as far as the sphenoid, the first section being formed by the occipital and internal face of the petrous temporal, and the second by the squamous temporal, the frontal, and the greater wing of the sphenoid.

The *base* or *inferior plane* is very irregular, and presents, from behind forwards, in the mesian line, the basilar channel, in which a great part of the encephalic isthmus is received; the sella turcica, which lodges the pituitary gland; and the processus olivaris, on which the optic commissure rests. At the sides are the foramen lacerum basis cranii; the cavernous fissures and the maxillary fissures, behind which is a large and deep digital impression, which receives the mastoid lobule or inferior lobe of the brain.

The *posterior end* presents the foramen magnum, by means o which the cavity communicates with the spinal canal.

The *anterior end* presents the crista galli process, in th median line, on each side of which are the ethmoidal fossæ fo the olfactory lobes, the cribriform lamella of the ethmoid form ing the floor of the fossæ.

The NASAL FOSSÆ are two cavities, separated by a cartilagi nous septum, which extend from the front of the palatine arch to the cribriform plate of the ethmoid, their length being an exact measurement of that of the face. The bony framework o these fossæ is formed of the nasal, the superior maxillary, the frontal, and the palatine bones—the whole forming a spacious irregular tube, the further extremity of which is blocked by the ethmoid, the turbinated bones being applied against the lateral walls and the vomer, in the median line, forming a point of attachment for the cartilaginous septum.

The SINUSES are winding cavities excavated in the bones of the head and face. They communicate freely with each other and with the nasal fossæ, of which they may be regarded as prolongations. Ordinarily, they number three on each side, viz. the frontal, the maxillary, and the sphenoidal.

The *frontal sinus* is formed at the inner side of the orbit, its extremely irregular walls being formed by the frontal, nasal, lachrymal, ethmoid, and superior turbinated bones. It commu nicates with the maxillary sinus by means of a large opening cut through the delicate bony partition between them. A thick vertical plate, often placed more to one side than the other, and always imperforate, separates this sinus from that of the opposite side.

The *maxillary sinus*, formed below the orbit in the superior maxillary, malar, ethmoid, lachrymal, and inferior turbinated bones, is the largest of the three sinuses. A ridge, which contains the superior dental canal, divides it into two chief compartments—an internal, which constitutes a shallow recess continuous with the sphenoidal sinus, and communicating with

PLATE II.

Fig. 1.—SKELETON OF CAT.

I. Bones of the Head.

A. *Bones of the Cranium.*	No.
Occipital bone, *a*,	1
Wormian bones,	2
Parietal bone, *b*,	2
Frontal bone, *c*,	2
Temporal bones, *k*,	2
Auditory ossicles—Malleus,	2
Incus,	2
Stapes,	2
Lenticular bone,	2
Sphenoid bone,	1
Ethmoid bone,	1

B. *Bones of the Face.*	
Nasal bones, *f*,	2
Lachrymal bones, *e*,	2
Malar bones, *d*,	2
Superior maxillary bones, *h*,	2
Intermaxillary bones, *g*,	2
Palate bones,	2
Pterygoid bones,	2
Vomer,	1
Turbinated bones,	4
Lower maxilla, *i*,	1
Hyoid bone,	1
Teeth—Incisor teeth,	12
Canine teeth,	4
Molar teeth,	14

II. Bones of the Trunk.

A. *Bones of Vertebral Column.*	
Cervical vertebræ, *l-l*,	7
Dorsal vertebræ, *m-m*,	13
Lumbar vertebræ, *n-n*,	7
Sacrum, *o*,	1
Caudal vertebræ, *p-p*,	20

B. *Bones of the Chest.*	
Ribs, *t-t*,	26
Sternum,*	1

C. *Bones of the Pelvis.*	
Iliac bones, *q*,	2
Pubic bones, *r*,	2
Ischial bones, *s*,	2

III. Bones of the Limbs.

A. *Bones of Fore Limb.*	No.
Scapula, *u*,	2
Humerus, *v*,	2
Radius, *w*,	2
Ulna, *x*,	2
Carpal bones—Pisiform bone, *y*,	2
Cuneiform bone, *z*,	2
Scaphoid bone, *a'*,	2
Unciform bone, *b'*,	2
Os magnum, *c'*,	2
Trapezoid, *d'*,	2
Trapezium, *e'*,	2
Metacarpal bones, *f'*,	10
Posterior sesamoid bones, *g'*,	20
Anterior sesamoid bones, *h'*,	10
1st phalanges, *i'*,	10
2d phalanges, *k'*,	8
3d phalanges, *l'*,	10

B. *Bones of Posterior Limb.*	
Femur, *m'*,	2
Patella, *n'*,	2
Sesamoid bones, *o'*,	4
Tibia, *q'*,	2
Fibula, *r'*,	2
Sesamoid bones, *p'*,	2
Tarsal bones—Os calcis, *s'*,	2
Astragalus, *t'*,	2
Cuboid bone, *u'*,	2
Navicular bone, *v'*,	2
3d cuneiform bone, *w'*,	2
Small cuneiform bone, *x'*,	2
Large cuneiform bone, *y'*,	2
Great metatarsal bones,	8
Small metatarsal bones, *z'*,	2
Posterior sesamoid bones,	16
Anterior sesamoid bones,	8
1st phalanges,	8
2d phalanges,	8
3d phalanges,	8

IV. Bones which are not connected with the Skeleton.

Collar bones,	2
Bone of penis,	1

Entire number of bones in the skeleton of the Cat—329.

Fig. 2.—SKELETON OF DOG.

I. Bones of the Head.

A. *Bones of the Cranium.*	
Occipital bone, *a*,	1
Parietal bones, *b*,	2
Frontal bones, *c*,	2
Temporal bones, *k*,	2
Auditory ossicles—Malleus,	2
Incus,	2
Stapes,	2
Lenticular bone,	2
Sphenoid bone,	1
Ethmoid bone,	1

B. *Bones of the Face.*	
Nasal bones, *f*,	2
Lachrymal bones, *e*,	2
Malar bones, *d*,	2
Palate bones,	2
Pterygoid bones,	2
Vomer,	1
Bones of the Face—cont.	
Superior maxillary bones, *h*,	2
Intermaxillary bones, *g*,	2
Hyoid bone,	1
Turbinated bones,	4
Inferior maxilla, *i*,	1
Teeth—Incisor teeth,	12
Canine teeth,	4
Molar teeth,	26

II. Bones of the Trunk.

A. *Bones of the Vertebral Column.*	
Cervical vertebræ, *l-l*,	7
Dorsal vertebræ, *m-m*,	13
Lumbar vertebræ, *n-n*,	7
Sacrum, *o*,	1
Caudal Vertebræ, *p-p*,	20

B. *Bones of the Chest.*	
Ribs, *t-t*,	26
Sternum,*	1

PLATE II.—Fig. 2.—SKELETON OF DOG—*continued*.

	No.
C. Bones of the Pelvis.	
Iliac bones, *q*,	2
Pubic bones, *r*,	2
Ischial bones, *s*,	2
III. Bones of the Limbs.	
A. Bones of the Fore Limb.	
Scapula, *u*,	2
Humerus, *v*,	2
Radius, *w*,	2
Ulna, *x*,	2
Carpal bones—Pisiform bone, *y*,	2
Cuneiform bone, *z*,	2
Scaphoid bone, *a'*,	2
Uniform bone, *b'*,	2
Os magnum, *c'*,	2
Trapezoid bone, *d'*,	2
Trapezium, *e'*,	2
Metacarpal bones, *f'*,	10
Anterior sesamoid bones, *h'*,	10
Posterior sesamoid bones, *g'*,	10
1st phalanges, *i'*,	10
2d phalanges, *k'*	8
3d phalanges, *l'*,	10
B. Bones of the Hind Limb.	
Femur, *m'*,	2
Patella, *n*,	2

	No.
Bones of the Hind Limb—cont.	
Sesamoid bones, *o'*,	4
Tibia, *q'*,	2
Tibula, *r'*,	2
Sesamoid bones, *p'*,	2
Tarsal bones—Os calcis, *s'*,	2
Astragalus, *t'*,	2
Cuboid bone, *u'*,	2
Navicular bone, *v'*,	2
3d cuneiform bone, *w'*,	2
Small cuneiform bone, *x'*,	2
Large cuneiform bone, *y'*,	2
Large metatarsal bones,	8
Small metatarsal bones, *z'*,	2
Posterior sesamoid bones,	16
Anterior sesamoid bones,	8
1st phalanges,	8
2d phalanges,	8
3d phalanges,	8
IV. Bones which are not connected with the Skeleton.	
Collar bones,	2
Bone of Penis,	1
Entire number of bones in Skeleton of Dog—340.	

Fig. 3.—SKELETON OF PIG.

	No.
I. Bones of the Head.	
A. Bones of the Cranium.	
Occipital bone, *a*,	1
Parietal bones, *b*,	2
Frontal bones, *d*,	2
Temporal bones, *c*,	2
Auditory ossicles—Malleus,	2
Incus,	2
Stapes,	2
Lenticular bone,	2
Sphenoid bone,	1
Ethmoid bone,	1
B. Bones of the Face.	
Nasal bones, *g*,	2
Os rostri, *h*,	1
Lachrymal bones, *f*,	2
Malar bones, *e*,	2
Superior maxillary bones, *i*,	2
Intermaxillary bones, *k*,	2
Palate bones,	2
Pterygoid bones,	2
Vomer,	1
Turbinated bones,	4
Inferior maxillary bone, *l*,	1
Hyoid bone,	1
Teeth—Incisor teeth,	12
Canine teeth,	4
Molar teeth,	28
II. Bones of the Trunk.	
A. Bones of the Vertebral Column.	
Cervical vertebræ, *m*,	7
Dorsal vertebræ, *n*,	14
Lumbar vertebræ, *o*,	7
Sacrum, *p*,	1
Caudal vertebræ, *q*,	18
B. Bones of the Chest.	
Ribs, *r-r*,	26
Sternum, *,	1
C. Bones of the Pelvis.	
Iliac bones, *s*,	2
Pubic bones, *t*,	2
Ischial bones, *u*,	2

	No.
III. Bones of the Limbs.	
A. Bones of Fore Limb.	
Scapula, *v*,	2
Humerus *w*,	2
Radius, *x*,	2
Ulna, *y*,	2
Carpal bones—Pisiform bone, *z*,	2
Cuneiform bone, *a'*,	2
Semi-lunar bone, *b'*,	2
Scaphoid bone, *c'*,	2
Uniform bone, *d'*,	2
Os magnum, *e'*,	2
Trapezoid bone, *f'*,	2
Trapezium, *g'*,	2
Metacarpal bone, *h'*,	8
Sesamoid bones,	16
1st phalanges, *i'*,	8
2d phalanges, *k*,	8
Navicular (shuttle) bone,	8
3d phalanges, *l'*,	8
B. Bones of Hind Limb.	
Femur, *m'*,	2
Patella, *n*,	2
Tibia, *o'*,	2
Fibula, *p'*,	2
Tarsal bones—Os calcis, *q'*,	2
Astragalus, *r'*,	2
Cuboid, *s'*,	2
Navicular bone, *t'*,	2
3d cuneiform bone, *u'*,	2
Small cuneiform bone, *v'*,	2
Large cuneiform bone, *w'*,	2
Metatarsal bones,	8
Upper sesamoid bones, *x'*,	2
Lower sesamoid bones,	16
1st phalanges,	8
2d phalanges,	8
3d phalanges,	8
Navicular (shuttle) bone,	8
Entire number of bones in Skeleton of Pig—325.	

the ethmoidal cell; and an external, divided into two chambers by a transverse plate, which frequently remains perfect through life, and completely isolates the inferior chamber. The superior of these chambers is prolonged backwards to the maxillary protuberance, and has the roots of the two last molar teeth jutting into its upper part. The inferior chamber is subdivided into two parts, the internal of which is prolonged into the inferior turbinate bone; the external, which is the smallest, having an elevation on its floor, caused by the roots of the fourth molar.

The *sphenoidal sinus*, the smallest of all, is an irregular cavity formed in the sphenoid and palatine bones. It is subdivided by incomplete partitions into several compartments, especially into an anterior—included between the plates of the palatine—and a posterior, excavated in the body of the sphenoid. It is separated from its fellow of the opposite side by a lamella, which is perforated, even in young animals.

COMPARATIVE OSTEOLOGY.

There are marked differences between the bones of the horse and other domestic animals like it. The ox and sheep are herbivorous, the pig omnivorous, the dog and cat carnivorous: or, to classify by digits, the horse and its allies are solipedes or monodactyles, with but one toe; the ox and sheep, with two, are didactyles; the pig, with four, is tetradactyle; while the cat and dog, with five anterior and four posterior toes, are irregularly tetradactyle.

In the cranial bones of the Ox the greatest difference is the development of the frontal bone, which is single, and extends from below the eyes to the crest forming the entire forehead, in the middle of which is the frontal tuberosity, which is very large in hornless animals, so as to resist shock (Pl. I. fig. 2, *a*). Springing from the crest on either side are two processes, varying in size and curve, but corresponding to the shape of the horn which they support. These are the flints or horn core, which are porous in their nature, especially at the roots. They are very rough, and

covered by thick periosteum, and present in their interior sinuses large canals and foramina, through which travel arteries and veins, which are continuous with the largely developed frontal sinuses, extending from the orbit to the tips of the flint, and nearly as far backwards and downwards as the foramen magnum. These not only materially lighten, but strengthen the bone. The anterior surface of the frontal is flat and broad superiorly, especially in the male, a broad forehead being an essential point in a bull: a cow, with too broad a forehead, is a bad milker—an ox, a bad feeder. The supra orbital foramina are double, and continued by a groove. The orbital process abuts on the zygomatic, with which it articulates.

The parietal (Pl. I. fig. 2, *b*), also a single bone, is transversely elongated, and recurved at its extremities. It is placed below the frontal crest, extending under and supporting the flints, and ascending into the temporal fossa to articulate with the sphenoid.

The occipital is single, much wider from side to side, but smaller than in the horse. It has neither crest nor tuberosities, which are replaced by two curved lines or ridges, and a concavity. The condyles are less prominent, but wider; the styloid processes are shorter, but broader and recurved. The basilar process is large, short, and thick, with a large basilar groove. The condyloid foramina are double, sometimes triple.

The squamous and petrous temporals are united, as in man. The tempero-maxillary articulation, zygomatic process, temporal conduit, the mastoid process, mastoid protuberance, and styloid processes, are large. The external auditory process is small, and turned downwards.

The sphenoid has large and thin pterygoid processes, a deep sella turcica, and prominent olivary processes. The pterygoid foramen is awanting, but the large foramen ovale, for the passage of the inferior maxillary nerve, persists; the other foramina open out in the anterior part of the bone.

The ethmoid and its cells are well developed. It has a large

volute, prolonged between the superior and inferior, forming a third turbinated bone, called the olfactory cave.

The nasal bones are only about one-third the length of, but broader and not so firmly fixed to the neighbouring bones, as those of the horse. The superior extremity is sunk in a groove in the inferior border of the frontal; the inferior extremity presents two points with a notch between them, the pair joining to form one. Along the internal part, or crown, of the nasal arch is a channel or groove, terminating in a blind sac.

The superior maxillary (Pl. I. fig. 2, *f*) is shorter but broader, the zygomatic spine being represented by a rough protuberance, concave behind. The infra orbital foramen is opposite the first molar tooth. The maxillary sinus is large, and is prolonged between the two plates of the palatine, and has no tusk socket.

The inter-maxillary (Pl. I. fig. 2, *g*) is broader; its inferior surface is flat from before backwards, and destitute of alveolar cavities. There is no incisive foramen, but a very large inter-dental opening. The inter-maxillaries are rarely united by suture.

The lachrymal (Pl. I. fig. 2, *e*) is much more extensive, forming at the bottom of the orbit a large protuberance crossed by the maxillary sinus. The orbital plate is thin and fragile.

The malar (Pl. I. fig. 2, *d*) is well developed. Its summit is bifid; the anterior branch meets the orbital process of the frontal; the posterior joins the zygomatic process of the temporal, behind the orbital fossa.

The palatine bones are large, the part entering into the formation of the palate being extensive. The palatine crest is thin and elevated, being formed by the union of the posterior borders of the palatine pterygoid and legs of the sphenoid. The posterior nares is much narrower; the septum dividing the nostrils is imperfect; the posterior nostrils are behind, not between, the superior maxillary; the pterygoids are very large, and enclose an opening which is left between the sphenoid and palatine.

The superior turbinated is small, while the inferior one is largely developed.

The vomer is very large and thin, resting on the inferior ha of the supra-maxillary suture.

The inferior maxillary (Pl. I. fig. 2, *i*) is longer but less vol minous; the neck is more constricted, and the symphysis seldo completely joins. There are eight small alveoli in front for th incisors; the condyles are small and convex in their short, bu slightly concave in their long, diameter, and permit more later motion. The coronoid processes are long, and the sigmoid note very deep.

The os hyoides has 7 pieces: 3 cornua on each side—inferio middle, and superior; the latter do not articulate with the tem poral bone. The spur process is small and blunt.

In the Pig, the occipital (Pl. II. fig. 3, *a*) forms the cres which is crescentoid; the foramen magnum and condyles ar small, the styloid processes long, passing backwards.

The parietal (Pl. II. fig. 3, *b*) is single, its superior surfac being contracted in the middle, with a sharp spine on each sid for temporal muscles.

The frontals (Pl. II. fig. 3, *d*) are very thick and straight, th orbital process short or awanting, the orbital socket being com pleted by ligament; in the centre of the bone, about a third fro its anterior border, is a foramen, and from it a groove, in whic a plexus of nerves run to be distributed over the face. Th frontal sinus is prolonged into the parietal; it does not articulat with the palatine by its lateral borders.

The temporal (Pl. II. fig. 3, *c*) is a single bone on each sid the petrous portion is small, the zygomatic process large, formin the zygomatic arch. A ridge connects the external auditor meatus, which is very high up, with the mastoid protuberanc replacing the mastoid process. The protuberance is very larg the styloid process short.

The ethmoid does not differ.

The maxillary articulation is not supported behind by a con dyloid process, and is smallest transversely.

The sphenoid is short, with large flat legs; the wings do no

project, but articulate with the frontal suture. The sella turcica is deep, and the olivary process large.

The nasal bones (Pl. II. fig. 3, *g*) are long, straight, and strong, firmly connected to the frontal and superior maxillary; they do not articulate with the lachrymal. The nasal peak projects nearly to the anterior maxillary.

The lachrymal (Pl. II. fig. 3, *f*) are small, with lachrymal fossæ on the supero-external part of the bone instead of in the orbit, as in the horse and ox, and are pierced by two conduits, which afterwards unite in one.

The malar (Pl. II. fig. 3, *e*) is very strong, and the zygomatic spine large, with its summit flat. It is divided into two branches, between which rests the zygomatic process of the temporal; the anterior branch is short, and not united to the orbital process of the frontal.

The superior maxilla (Pl. II. fig. 3, *i*) is very short, and its surface concave, for the reception of large facial muscles; the spine presents a large lateral protuberance anteriorly, whence spring the tusks; the intermediate space is short, the sinus small, projecting into the malar, the palatine foramen being in its palatine plate, not in the palatine bone.

The inter-maxillary (Pl. II. fig. 3, *k*) is large and strong; it is not joined at the symphysis, and consequently has no foramen incisivum. The external process is very long, and articulates with two-thirds of the nasal. Projecting upwards from a concavity on the superior surface of the body are two strong cartilages, which form a tube round the nasal opening; these are ossified in old animals, forming the spade or snout bone.

The nasal openings are small and round.

The palatine bones form a large portion of the hard palate. The orbital portion is very small. The palatine crest is replaced by a tuberosity, against which externally abut the pterygoid processes of the sphenoid and pterygoid. The union of these three parts at the posterior part of the head constitute a large rifid tubercle.

The turbinated bones do not differ materially, but are longe and less fragile.

The inferior maxillary (Pl. II. fig. 3, *l*) is very strong, havin no well-defined neck, and small interdental spaces. The coronoi process is short, but strong. The condyles, somewhat triangular are compressed laterally. The dental canal terminates anteriorly by numerous small mental foramina. The alveoli, for incisors are widely separated.

The os hyoides has a large body, but no appendix. The lesse cornua short, and united to body; the greater are thin, twisted like the letter S, and united to the lesser and to the tempora bone by yellow elastic ligaments.

The occipital bone of the Dog (Pl. II. fig. 2, *a*) is very strong and triangular behind, terminating in the crest, which forms a sharp point. The tuberosity is not well marked; the styloid processes are short; and the condyles large. The foramen lacerum basis cranii is divided into two portions by the mastoid protuberance. The basilar process is large, long, and thick, being crossed by a veinous canal. The anterior angles form a prominent ridge, which unites with the parietal.

The parietal bones (Pl. II. fig. 2, *b*) are very convex, meeting in a sharp ridge, which presents a protuberance laterally, and unites with the occipital to form a ridge carried back to the summit of the petrous temporal, under the sides of the occipital.

The frontals (Pl. II. fig. 2, *c*) are triangular, and present along their middle a hollow more or less marked, according to breed. The orbital process is simply a sharp peak. Over the incomplete orbital socket there is no supra orbital foramen. The frontal, in the dog, does not articulate with the temporal, but does with the superior maxilla.

The temporals (Pl. II. fig. 2, *k*) are not divisible into distinct pieces, as in the horse. The zygomatic processes are large, and project very far, affording capacious temporal fossæ. The temporo-maxillary articulation has glenoid cavities for the condyles of inferior maxilla. The external auditory meati and

mastoid protuberances are large, owing to the sense of hearing being acute. There are no hyoid, and diminutive mastoid, and styloid processes. There are two canals, of which there exists no trace in other domestic animals, viz.: the carotid, which traverses the mastoid portion to join the veinous canal between the basilar process and temporal; and another which pierces the petrous portion at the upper part of the carotid canal, and gives passage to the fifth pair of nerves.

The sphenoid resembles that of man. Its posterior part is short, and presents two large wings, which mount to the temporal fossæ. The anterior part is straight, and prolonged by small wings. The pterygoid processes are very short. The pituitary fossa shallow, and limited by the clinoid processes, which are four eminences detached from the base of the posterior wings.

The ethmoid presents very deep fossæ and well-developed volutes.

The nasals (Pl. II. fig. 2, *f*) are small and narrow, wide in front, presenting a semicircular concavity, instead of a peak.

The superior maxilla (Pl. II. fig. 2, *h*) is short, but strong, differing, as all facial bones do, with the breed. It articulates by a long process with the frontal, furnishes the socket for the tusk, and is spineless.

The inter-maxillary (Pl. II. fig. 2, *g*) is short, and presents a foramen incisivum, with alveoli for incisors, an oval interdental opening, and small interdental space.

The lachrymal (Pl. II. fig. 2, *e*) is small, and confined to the orbit.

The malar (Pl. II. fig. 2, *d*) only articulates with the superior maxilla. Its zygomatic process is large, and curved outwards, and its summit bifid. The inferior branch articulates with the zygomatic process of the temporal; while the superior forms a small tubercle, to which is attached the ligament from the orbital process of the frontal, completing the orbit.

The palatine bones form about a third of the palate; do not

assist in the formation of the sphenoidal, but furnish a smal portion of the maxillary, sinuses.

The pterygoids are strong and quadrilateral, and the nasa openings are the turbinated bones. They are remarkable for th number of their convolutions, assisting in the formation o frontal and maxillary sinuses.

The inferior maxilla (Pl. II. fig. 2, *i*) is strong, its rami broad and large, presenting a deep depression on the external posterio sides, into which is inserted the temporalis muscle. The con dyles are ovoid transversely, and the coronoids long and broad the sigmoid notch very deep, the labial foramen double or triple and the interdental spaces very small.

The hyoid bone is trifid in the young, but single in the adult The larger cornua are united to the temporal bone by fibro cartilage.

The vertebral column of the Ox and Sheep is made up of 26 vertebræ—7 cervical, 13 dorsal, and 6 lumbar.

The bodies of the *cervical* (Pl. I. fig. 2, *k*), shorter than those of the horse, are longer than the dorsal. The transverse processes consist of a superior, small, and an inferior large portion, pierced by vertebral foramina. The superior spinous processes are large, and increase from before backwards. The inferior spines are small articular processes fully developed, the anterior and posterior ones being united by a roughened plate.

The atlas, smaller than that of the horse, has its alæ more horizontal and slightly turned up at its external borders. The spinal foramen is large, the posterior lateral one awanting. The condyloid articulations are wide—that for the dentata small and flat.

The axis is short, the odontoid process being broad, bounded below by a prominent articular ridge, which is not excavated in the inferior mesian line. The superior spinous process is single and slender throughout, and connected with the posterior articular process. The pedicles on either side are perforated by a circular foramen.

The sixth cervical has long superior spinous and transverse processes, but no inferior spine.

The seventh superior spine is the largest, and passes backwards and upwards. The transverse processes are single, and terminating in rough tuberosities. There is no inferior spine, and seldom a vertebral foramen.

The bodies of the *dorsal* vertebræ (Pl. I. fig. 2, *l*) are longer than in the horse, but have the same general form, with the exception of the anterior one, whose pedicles have large anterior and small posterior notches. The transverse processes are large, decreasing in size, and assuming an arched form from before backwards; all but the last, or last two, present distinct articular surfaces for the costal tubercles. The spinous processes are broad, long, and smooth. The 5 or 6 anterior pass backwards, upwards, and forwards—the remainder backwards. The fourth is the longest.

The *lumbar* vertebræ (Pl. I. fig. 2, *m*) in the ox and sheep are longer and thicker than in the horse, their bodies being more convex on the lateral and inferior surfaces. The transverse processes are long, and almost at right angles to the body, concave anteriorly, convex posteriorly—the first four being inclined backwards. They never articulate with each other, nor does the last with the sacrum. The fourth is the longest. The articular processes are small — the posterior being over-lapped by the anterior ones.

The sacrum (Pl. I. fig. 2, *n*) is large and more arched than in the horse, and the superior surface more convex. The spinous processes are united by complete ossification constituting a prominence on the pelvis of the ox. The superior groove is narrow and uneven, the superior sacral foramina not so constant or regular, the under surface more concave, and the inferior sacral foramina larger. The sacral cornua are large, and expanded for ligamentous attachment. The spinal canal oval, and the convex articular portions of the body large. The articular processes are widely separated by a triangular opening leading into the canal.

The transverse processes are short, thick, and non-articular ante riorly; their external extremities are bounded by a vertica border, the inferior angle of which is directed downwards, giving a deeper surface for articulation with the ilium.

The coccygeal bones (Pl. I. fig. 2, *o*), usually 15, are stronge and more tuberous. Articular processes only exist in the anterio ones.

The Ox and Sheep have 13 ribs on each side, of which 8 are true and 5 false (Pl. I. fig. 2, *p p*). They are straight, broad long, and more uniform than those of the horse. The superio extremity is large and smooth, the neck of the anterior ones shor and thick, the tubercles large; the neck of the posterior one long and thin, and smaller than in the horse. The angles are not well marked, — the inferior extremities expanded to articulate with their cartilages by true joints. The ribs of the ox sloping backward, render the chest circular.

The sternum (Pl. I. fig. 2 **)* is larger, and flattened through out, consisting of 7 pieces, which, the anterior pair excepted unite by ossification. Between these there is a true synovia joint, which allows lateral motion, modifying the awkward gai necessitated by the breadth of bone. The superior surface i concave, forming the floor of the chest; the inferior convex, bu slightly concave from side to side. The borders are deep, and present between each two segments articular depressions for the costal cartilages. The cariniform cartilage is small and conical the ensiform, large and circular.

The os innominatum is larger, but presents the same genera appearance as in the horse.

The ilium (Pl. I. fig. 2, *q*) is thick, and presents a prominen line running from the antero-inferior spine to the superior ischiatic ridge. The internal surface is very convex; the ridge between that part resting on and that without the sacrum is well marked. The ilio-pectineal eminence is prominent, and sometimes pierced by a foramen leading into the articulation The crest and spinous processes are very strong. The ischium

(Pl. I. fig. 2, *s*) equals the ilium. The anterior extremity has a thick projecting external portion, which forms part of the cotyloid cavity, and is surmounted by the large superior ischiatic spine, whence a slight ridge is continued backwards over the thick concave body into the tuberosity. The inferior ischiatic spine is conical, pointing outwards and downwards. The pubis (Pl. I. fig. 2, *r*) is larger, and the internal surface more concave; the symphysis is never completely joined by ossification. The anterior border presents a deep groove extending the whole length of the bone; it affords attachment to the abdominal muscles and fascia. The internal surface has a ridge and tubercle, absent in the horse. The condyloid cavity is deeper, and its margin surmounted by a rim of cartilage. The notch is narrow and deep, looking into the large foramen ovale. The inlet of the pelvic cavity is oval; its sacro-pubic diameter great, its transverse less; while the sacro-ischiatic diameter of the outlet is less, and the transverse great.

The femur (Pl. I. fig. 2, *l'*) is cylindrical, the trochanter externus awanting. The trochanter internus is a round tubercle near the posterior surface; the head is small, but projecting; the trochanteric fossa deep, but small; the trochanter major has only one eminence, which is not prominent, but united to the internal trochanter by a ridge. The condyles and trochlea are smaller, and the condyloid fossa not so deep.

The tibia (Pl. I. fig. 2, *n'*) has no vertical fossa under the anterior tuberosity. The inferior extremity has its external tuberosity detached, forming a small bone which articulates with the tibia, calcis, and astragalus; the tibia also articulates with the latter.

The fibula (Pl. I. fig. 2, *n'*) is replaced by a long ligament stretching from the superior to the inferior extremity of tibia.

The patella is smaller (Pl. I. fig. 2, *m'*).

The tarsus consists of 6 bones. The cuboid is awanting, the astragalus is deeper, but narrower. The calcis longer, but not thick; its posterior surface is grooved for the tendon. The

cuneiforme magnum and cuboid are united into the cubo-cunei form. The cuneiforme medium is the same, while the parvum becomes a pisiform bone. The extra bone is the external tibia malcolus already noticed (Pl. I. fig. 2, *o'*, *p'*, *q'*, *r'*, *s'*, *t'*.)

The large metatarsal has its inferior extremity divided into two equal parts by a deep fissure, with a vascular groove postero superiorly. The small metatarsal, when present, are rudi mentary.

The scapula (Pl. I. fig. 2, *l*) is larger and more triangular The spine does not, as in the horse, terminate imperceptibly in the neck, but by an abrupt angle, prolonged to a point—the acromion process; the neck is more distinct, and the humera angle more detached. The coracoid process not so prominent the glenoid cavity more limited.

The extremities of the humerus (Pl. I. fig. 2, *u*) are mor expanded; bicipital groove single; external trochanter ver large, with its summit recurved over the bicipital groove. Th head is larger; tuberosity scarcely visible; body less twisted and inferior extremity smaller.

The radius (Pl. I. fig. 2, *v*) is short; the ulna (Pl. I. fig 2 *w*) longer and stronger, extending to inferior extremity of th radius and articulating with one of the carpal bones. It is cu obliquely from without, inwards, presenting two radio-ulna arches, united behind by a deep fissure.

The carpus consists of 6 bones—4 above, 2 below. Th upper are scaphoid and lunar, which articulate with the radius cuneiform, articulating with the radius and ulna; and trapezium behind, which is small, and grooved externally. The lower a the os magnum and unciform, which articulate with the large m tacarpal. The trapezoid and pisiform are awanting. The met carpus magnus presents a vascular groove down its anteri middle, marking the original separation of the bone into tw which terminates inferiorly in a foramen. The inferior e tremity is divided by a deep fissure into two articulation resembling the single one of the horse. The external being alwa

the smallest, a rudimentary metacarpus is placed postero-externally, as ruminants are cloven footed. All the bones below this joint in either limb are double; they are small and narrow, the coffin bone resembling that of the horse, mesially divided (Pl. I. fig. 2, *x*, *y*, *z*, *a'* to *k'*).

The vertebral column in the Pig consists of 28 vertebræ —7 cervical, 14 dorsal, and 7 lumbar. The cervical (Pl. II. fig. 3, *m*) have short bodies, producing the stumpy neck of this animal. They are convex below, and devoid of inferior spines. The transverse processes, No. 7 excepted, are bifid, and in the posterior part of the cervix are large and overlapping. The articular processes are strong, the anterior being pierced by a foramen entering the spinal canal. The two terminal spines are large. There are exposed oval spaces between the laminæ occupied by ligaments.

The atlas is strong, rough, and irregular, presenting a large tuberosity on its superior surface. The inferior tuberosity passes along the inferior part of the axis. The wings are strong, particularly at their posterior borders.

The axis is broad anteriorly, with small conical odontoid processes, and extended articular surfaces; small transverse processes, pierced by large foramina, which on each side communicate with two others, one entering the spinal canal, the other opening directly upwards.

The seventh cervical vertebra has a large superior spine, and small transverse processes, generally pierced by vertebral foramina.

The Pig has usually 14 dorsal vertebræ (Pl. II. fig. 3, *n*), with short bodies, increasing in length from before backwards. The spinous processes are broad, long anteriorly, decreasing posteriorly; the anterior and posterior pass forwards, the central ones backwards, and from their middle appear suddenly bent forwards.

The lumbar vertebræ (Pl. II. fig. 3, *o*) are 7, sometimes 6. The bodies are longer than in any other region, and the only ones

which possess inferior ridges. These are compressed laterally and expanded at their extremities. The spinous processes are strong-pointed, directed upwards, and bifid at the posterior borders, diverging to connect with the posterior articular processes. The transverse processes are long, and nearly horizontal.

The sacrum (Pl. II. fig. 3, *p*) is triangular, and usually made up of 5 segments. It is peculiar in some breeds, being concave above and convex below, the apex pointing upwards. The spinous processes are very short, and do not form an elevated ridge. The articular processes are large, and overlap those of the last lumbar.

The rudimentary coccygeal bones vary from 8 to 20 (Pl. II. fig. 3, *q*).

The Pig has 14 pairs of ribs—7 true and 7 false (Pl. II. fig. 3, *r*–*r*). They are thin and flat, the last 3 having their tubercle articulations and posterior head united. The cartilages of the true ribs are large and flat.

The sternum (Pl. II. fig. 3, *s*) is very long, and consists of 6 pieces. The anterior cartilage forms a long eminence, terminating in a blunt point.

The scapula (Pl. II. fig. 3, *t*) is large, without the acromion, but has a prominent spine, prolonged in its centre by a triangular eminence, which inclines backwards over the postea spinatus.

The humerus (Pl. II. fig. 3, *u*) is short, and compressed laterally, the head inclining backwards. The entire bone is sigmoid, the bicipital groove single, and near the inner lateral border. The internal trochanter is very large, with its summit recurved over the bicipital groove, as in the ox. The external tuberosity small; the internal replaced by muscular imprints.

The radius (Pl. II. fig. 3, *x*) is small, and much curved. The ulna (Pl. II. fig. 3, *y*) is a true long bone, having a medullary canal, extending to the knee, with which it articulates. They are united by interwoven ligaments, which never become ossified. The ulna is flat from before backwards, and lies on the

posterior face of the radius, so as to clasp it completely. The olecranon is prominent.

The carpus consists of 8 bones—4 in the upper and 4 in the lower row. The bones of the upper row are similar to those in the horse—the cuneiform articulating above with the ulna and a small portion of the radius; the semi-lunar and scaphoid with the radius; the trapezium with neither of the bones of the fore-arms. The bones of the lower row decrease from without inwards, and are the unciform, articulating with the two external metacarpal, the magnum with the large internal, and the trapezoid with the two external; the fourth, terminating bluntly, also articulates with the metacarpals (Pl. II. fig. 3, *z* and *a'* to *g'*).

The metacarpals are 4. The middle are large, the side pair small. The large articulate with each other, and with their relative small ones superiorly. Each terminates inferiorly, as the single one of the horse. The middle pair are the sole weight-carriers in progression. The lateral ones, with a condyle in front and trochlea behind, do not reach the ground below the metacarpals. On each of the four digits there are three phalanges, with their accessory bones (Pl. II. fig. 3, *h'*, *i'*, *k'*, *l'*).

The os innominatum of the Pig presents the same general character as in ruminants; it is, however, distinguished by the form of the ilium, which is very convex on its anterior border, by its small tuberosity, spine, and ischial ridges, and by the absence of the protuberance on the inferior part of its symphysis (Pl. II. fig. 3, *s*, *t*, *u*).

The femur differs little from that of the ox, except in its contracted neck, which is situated within and in front of the trochanter major.

The vertebral column of the Dog consists of 27 true vertebræ —7 cervical, 13 dorsal, and 7 lumbar. In carnivora, the cervical vertebræ are proportionally large, approaching those of the horse.

The atlas possesses large and expanded alæ, which are pierced

near their centre by a large foramen opening into the spinal canal, where the anterior border joins the wings: a groove or notch exists instead of a vertebral foramen; the posterior articulation, instead of being flat, has glenoid cavities, that in the inside of the ring for odontoid process being united to the anterior ones.

The axis is long, superior spine single and prominent, extending well forwards, leaving no space, as in the horse; the odontoid process is long, convex on all its surfaces, pointed anteriorly, more nearly resembling that of man than any other domestic animal; it serves as a pivot, on which the head and atlas freely rotate; the large transverse processes present true condyles articulating in the glenoid cavities of the atlas.

The remaining cervical vertebræ diminish as they proceed backwards, and in most breeds have large superior spines, which gradually increase from 3 to 7 (Pl. II. fig. 2, *l–l*).

The dorsal, usually 13, vary with the breed: the pedicles contain large posterior notches, not foramina, as in the horse and cow. The spinous processes are strong, those of the 4 or 5 anterior are equal, and nearly upright, the succeeding ones decrease, and incline backwards. The last 3 or 4, especially in dogs adapted for speed, are sharply levelled, and incline forwards. Two or three of the terminal transverse processes are small, the heads of the corresponding ribs resting in articular depressions on the vertebral sides (Pl. II. fig. 2, *m–m*)

The Dog has 7 strong lumbar vertebræ (Pl. II. fig. 2, *n–n'*), sometimes 6; the bodies are compressed, and ridged inferolaterally. The posterior notches are large, the spinous processes inclined forwards or backwards, leaving a triangular space between first lumbar and last dorsal. The transverse processes are bent downwards and forwards; the anterior articular processes expand laterally, receiving between them the posterior ones of opposing vertebræ.

The sacrum (Pl. II. fig. 2, *o*) usually consists of 5 segments, and is frequently as broad behind as in front—the first segment

resembles the last lumbar, and is often incompletely united by ossification to the segment behind it. The spinous process is single, thin, and serrated superiorly; the transverse processes are bifid, consisting of upper and lower portions, the upper resembling those of the lumbar.

The rudimentary coccygeal bones vary from 8 to 20 (Pl. II. fig. 3, *p–p*).

The Dog possesses 13 ribs (Pl. II. fig. 2, *t–t*) on each side, 9 true and 4 false; their size and curve vary with the breed, but they are usually thick and straight.

The sternum (Pl. II. fig. 2*) consists of 8 elongated cylindrical bones, which resemble the coccygeal of the horse, and are joined by fibro-cartilage.

The scapula (Pl. II. fig. 2, *u*) is very large, the spine being almost central, and terminating inferiorly in an acromion process, which descends close to the glenoid cavity, where it recurves. A rudimentary clavicle is buried in the muscles between the scapula and the sternum; in the cat this is better developed, and connected to the acromion process of scapula and sternum by ligamentous cords.

The humerus (Pl. II. fig. 2, *v*) is long, slender, considerably curved, but not much twisted; the external trochanter well developed, the internal awanting; the bicipital groove single. The condyles are large, and the coronoid and inter-condyloid fossæ united by a canal which penetrates the bone.

The radius and ulna (Pl. II. fig. 2, *wx*) are about equal in volume—the ulna, if anything, the largest. The bones articulate solely by their extremities—above by an articular concave facet on the ulna, and a convex one on the radius; below by a concave facet on the radius and a convex one on the ulna; the two, as it were, cross each other—the upper extremity of the ulna articulating behind and to the inner side, the lower extremity to the outer side.

The bones of the carpus are 7–3 above and 4 below. The upper are scaphoid and lunar united, cuneiform, and trapezius;

the lower row, diminishing from without inwards, are the same as in the pig (Pl. II. fig. 2, *y*, *z*, *a'*, *b'*, *c'*, *d'*, *e'*).

The Dog has 5 metacarpal bones—4 large and 1 small. The former are the largest, and have 3 phalanges each, homologues of the 4 fingers of man, and 2 sesamoids, the small navicular bone being replaced by a ridge on the third phalanx. The fifth and most internal metacarpal has only 2 phalanges—the third and second—and corresponds to the human thumb. It has a small sesamoid similar to the navicular of the horse (Pl. II. fig. 2, *f'*, *g'*, *h'*, *i'*, *k'*, *l'*).

The os innominatum and pelvis are long and narrow. The ilium concave posteriorly, the ischiatic spine and tuberosity becoming one tubercle. The ischium is also narrow and long; the cotyloid cavity, surrounded by a prominent border, slightly cut within (Pl. II. fig. 2, *q*, *r*, *s*),

The femur (Pl. II. fig. 2, *m'*) is straight and long, presenting a prominent neck and a muscular line posteriorly, equivalent to the linea aspera of man.

The tibia and fibula (Pl. II. fig. 2, *q'*, *r'*) are long, and united in the inferior half of their middle by ligaments—at either extremity by diarthrosis. The fibula also articulates with the astragalus.

The tarsus or hock consists of 6 bones, as in pig; of 7, when the small cuneiform is bifid, viz., calcis, astragalus, cuboid, and 4 cuneiform. The astragalus presents a distinct head, separated by a neck which articulates with the cuneiforme magnum (Pl. II. fig. 2, *s'* to *y'*).

The metatarsal bones are 4 large and 1 rudimentary, the large having each 3 phalanges, with their accessory sesamoids; the fifth, or small rudimentary metatarsal, is only a ligamentous cord, in which is found a short bone, which represents a phalanx (Pl. II. fig. 2, *z'*).

SYNDESMOLOGY.

The several bones which form the skeleton are united together by means of a structure differing from either, the result being termed an articulation or joint, the study of which is syndesmology.

Articulations are divided into three classes –first, *immovable*, or those where the two parts are so united as to admit of a slight degree of motion, if any, as in the bones of the head, where a thin layer of fibrous membrane only is interposed; second, *movable*, where there is evident motion, the articular surface of each bone being covered by laminæ of an elastic structure, called cartilage, the bones being held together by strong bands or capsules, called ligaments, passing from one bone to another, the whole being lined by a serous membrane, termed synovial membrane, from which exudes a fluid, synovia, for lubricating the joint; the third class are *mixed* joints, where there is a certain degree of motion without joint oil, the surfaces of the bones being joined together by broad laminæ, or discs, of fibro-cartilage adhering to the ends of both bones, and also to the external ligaments, as in the vertebral column.

Before considering the different forms of joints, we will examine the various structures which enter into, and contribute towards, their mechanism. These are bone cartilage, fibro-cartilage, ligaments, synnovial membranes, and fat.

Bones form the fundamental portion of all joints. Long bones articulate by their extremities, which are more or less expanded, and present surfaces adapted to corresponding ones on contiguous bones. These articular surfaces consist of cancellated tissue, covered by thin laminæ of white compact tissue, having neither blood-vessels or nerves, and constitute the articular lamella, or now vascular layer. Flat bones, when they enter into the formation of a joint, become expanded. In health, one bone never comes directly in contact with another.

Cartilage is a firm, bluish white, elastic substance, somewha transparent, resilient, and flexible, possessing great cohesiv powers. There are two kinds. That which forms the origina basis of the bony framework is *temporary*, and that which per sists in the adult *permanent* cartilage. Of the latter, there ar four varieties—

First, *Articular*, which incrusts the ends of bones entering int the formation of true joints, forming a thick springy cushion which breaks concussion, and eases motion.

Second, *Costal*, which enters into the formation of th thoracic walls, and imparts elasticity to them.

Third, *Membraniform*, which exists as plates of greater o lesser thickness, entering into the formation of tubes that requir to be kept open without being rigid, as the external ear, nose eyelids, Eustachian tube, and larynx.

Fourth, *Reticular*, which is yellow, spongy, and flexible, existing in the epiglottis and small cartilages of the larynx.

All cartilage, except what enters into the formation of joints is covered by a fibrous membrane, called the perichondrium.

Cartilage consists of corpuscles or cells, and an intercellula substance or matrix. The latter is homogeneous, or slightly granular. The cells contained in lacunæ in the matrix are oval round, fusiform, and nucleated, the nuclei containing nucleoli Cartilage grows by multiplication or division of these nuclei.

In articular, or cartilage of incrustation, the matrix is abund ant, and the cells differ in form, those near the surface being flatter and most numerous. It is always thickest in the young becoming thinner as the animal ages, owing to ossification of th non-vascular layer. It is thickest in the centre of convexities thinnest in the centre of cavities.

In the adult, it is non-vascular, being nourished by a narrow vascular zone called the circulus articuli vasculosus, which circle the free edge of the synovial membrane, from which the liquo sanguinis is conveyed by imbibition.

Articular cartilage, when ruptured, is always repaired by

fibrous tissue or bone, and when once abraded is never reformed. The bone comes into wear, and gets polished, being sometimes accompanied by porcellanous deposit. This porcellanous change is produced by an absorption of animal matter, the hard earthy part being renewed by the blood-vessels of the cancellated tissue. When articular cartilage is abraded, there is an increased demand for lubricative synovia, and there is inflammation and distension of the capsule.

In the majority of close-fitting joints, there is a part devoid of articular cartilage, where we have a sulcus or cavity for storing synovia. In these sulci, neither cartilage nor the non-vascular osseous layer exists, but simply a thin plate of bone over the cancellated tissue. They have been mistaken for ulceration. Their surfaces are smooth, which would not be the case if ulceration existed.

Articular cartilage, when ulcerated, does not suppurate. Where pus is found in a joint, it originates in the cancellated tissue or synovial membrane.

Fibro-cartilage exists chiefly in mixed, but also in certain synovial, joints, as the stifle and hock. It consists of cartilage and white fibrous tissue, being firm and elastic like cartilage, tough and flexible like fibrous tissue. It is arranged into four classes—

First, *Inter-articular*, in movable joints, as between condyle of lower jaw and temporal bone.

Second, *Circumferential*, where it deepens the cavity, as in the hip joint.

Third, *Connecting*, where it is interposed between bones, as in the vertebræ.

Fourth, *Stratiform*, found in grooves on bones where the tendons of muscles play, sometimes existing in tendons themselves, as in flexor brachii.

Fibro-cartilage is dullish white, opaque, and devoid of perichondrium, more vascular than cartilage, its blood-vessels being few, and confined to the fibrous tissue. It consists of interwoven bundles of fibres, with cartilage cells interspersed amongst them.

In the variety connecting bones, it consists of concentric ring of fibrous tissue, with a soft elastic centre made up of cartilag cells. Its force of cohesion is very great, surpassing that o bone, the vertebræ giving way before the intervertebral discs.

Whenever fibro cartilage exists in a movable joint it increase play, and gives security.

Ligaments are dense fibrous substances connecting bones. The exist in all movable, and the majority of mixed, articulations, an are made up principally of white fibrous tissue. There are tw kinds—*capsular* or *bursal*, and *funicular*, *connecting* or *binding*

Capsular ligaments consist of a thin layer of white fibrou tissue, surrounding the adjacent heads of articulated bones, an consist of a dense interlacement of fibres running into the per osteum. Some regard them as a continuation of it. They neve bind bones together, and are always loose and baggy, their us being to protect the synovial membrane, and form cavities roun joints for storing the synovia.

Funicular or *binding* ligaments vary in form, consisting o round or flattened cords or bands of white fibrous tissue, passin in straight lines from one bone to another. In joints movin only in one direction, there are lateral connecting ligaments, an in all the true joints of the horse, excepting the shoulder an hip, they exist. They sometimes pass between bones wher there is no joint. These are the interosseous ligaments.

White fibrous tissue, of which these ligaments are made, strong, pliable, tough, and elastic, consisting of fine silvery fil ments, which are collected into coherent bundles, varying i thickness, but usually running parallel. Muscular tendons als consist of parallel white fibrous tissue; in aponeuroses, the intersect.

Some ligaments are composed almost entirely *of yellow elast tissue*, such as ligamentum nuchæ and those connecting th vertebral arches. It differs from the white in being yellow an elastic, although neither so tough or strong. The fibres run sid by side, dividing into anastomosing branches, which reticulat

with each other. A characteristic of yellow tissue is that its broken ends curl up.

Yellow tissue also enters into the formation of the vocal cords, abdominal fascia, and the coats of blood-vessels.

Synovial membranes are exceedingly dilated membranes, arranged in the form of short tubes attached by their open ends to the margins of the articular surfaces of bones, and lining the capsular ligament, or are interposed between structures which move one over another. They are smooth, and resemble serous membranes in structure and in forming close sacs, but differ in the nature of their secretions, which in the latter is a peculiar viscid, glairy fluid. They are intended to lessen friction and facilitate motion, and are divided into three classes—

First, *Synovial membranes* or *capsules*, which line the capsular ligaments of all diarthrodial articulations.

Second, *Bursal synovial* membranes, found where one surface moves upon another, as when a tendon plays over a bone,—these are *synovial bursæ*,—or where the integument glides over a bone, when they reside in the sub-cutaneous tissue, and are known as *bursæ mucosæ*.

Third, *Vaginal synovial membranes* or sheaths, which exist where one tendon forms a sheath for another, or in canals through which tendons glide.

On opening a capsular ligament, you find its interior smooth and polished, which is due to the synovial membrane, which consists of dense areolar tissue, and affords a medium for supporting the blood-vessels. It is called the *limiting* or *basement membrane*, and covered on the free side by several layers of daly epithelium.

The synovial membrane, on reaching the articular cartilage, asses over its margin a short distance, where it is raised into peculiar vascular folds, which are cleft at their edges, forming the *synovial fringes*, from which the synovia is secreted; the very ramifies as a plexus of capillaries underneath the cells, being most abundant towards the articular cartilage, where they

form a vascular zone, the *circulus articuli vasculosus*, in which the capillaries terminate by dilated loops.

Where one cartilage rubs on another, their free surface is covered with these fringes, which act as an oil brush.

When a joint is opened, it looses the character of a serous membrane, and discharges pus, never again recovering itself.

Synovia is a viscid, transparent fluid, resembling the white of egg; it fills the cavity between the cartilage and its membrane, and consists of liquid fibrin, albumen, salts, and water, being secreted from the epithelial scales, which, as they grow, burst, and yield the synovia.

When an animal is in active exertion, there is an increased secretion of synovia, the capsules bulging. In synovitis, the synovia is diminished, the inflammation being in the synovial membrane.

Fat is invariably found in connection with all large joints, and is remarkable for lightness, elasticity, and insensibility: it is admirably fitted for acting as a cushion, lying usually between the capsular ligament and synovial membrane, or in the fringes. It consists of many minute cells charged with oily matter, and lodged in meshes of areolar tissue: these cells are round or oval, and generally collected into groups.

Articulations are divided into 3 classes—*immovable*, *movable*, and *mixed*.

Immovable or *synarthrosis*.—These joints exist where the parts are continuous bony surfaces, being almost in direct contact, and not separated by a synovial cavity. There are three varieties—*sutura*, *schindylesis*, and *gomphosis*.

Sutura is divided into *vera* and *notha*. In the *vera* or *true* the contiguous margins are united by a series of interlocking processes and indentations, a thin cartilaginous layer being interposed, which is connected externally with the pericranium, and internally with the dura mater. Variety of shape has led to its division into three kinds,—*sutura dentata*, where the processes are larger and tooth like, as in parietal; *sutura serrata*

where they are small and fine, like the teeth of a saw, as in frontal; and *sutura limbosa*, where there is an overlapping of one bone with another, as in occipito-parietal. In the *false*, or *sutura notha*, the bones are joined by plain, rough surfaces, of which there are two varieties—*sutura squamosa*, where the adjacent borders are bevelled off, the edge of one bone resting on and overlapping the other, as in the tempora-parietal; and *sutura harmonia*, where the surfaces of two bones simply contact, as the nasal and inter-maxillaries.

Schindylesis is that form of immovable articulation, where a ridge or plate of one bone is received into a slit or fissure in the plate of another, as the wing of sphenoid into the incisura sphenoidale of the internal orbital plate of frontal.

Gomphosis, where the conical surface of one bone is inserted or impacted into a cavity or socket of another, as the teeth into alveoli.

The *diarthrodial* or true joints possess evident mobility, and are formed by the approximation of two bony surfaces, each covered by a layer of cartilage, and connected by ligaments and membranes, with an interposed synovial sac. They are divided into four varieties—

Arthrodia, in which the motion is simply gliding, the bony surfaces being either plain or slightly undulating, and the motion limited by ligaments or processes of bone, as in the metacarpus.

Enarthrosis, or ball-and-socket joints, capable of moving in any direction. The extremity of one bone is globular, and fits into a cup-shaped concavity in another, as the hip and shoulder.

Ginglymus, or hinge joints, in which, although the motion is extensive, it is limited to one direction, the articular surfaces of the opposing bones being marked with elevations and depressions, which fit exactly into each other, as the elbow, *rotatory* joints, *diarthrosis rotatorius*, or *commissura trochoides*. Here motion is limited to rotation. They are formed by a pivot on the bone fitting into a ring on another, as the axis and atlas.

The last kind is the *mixed or amphiarthrosis*, where two

surfaces of bone are connected together by intervening fibro cartilaginous discs and external ligamentous bands. There is degree of limited motion, but no synovial sac, as in the vertebra and symphysis pubis.

The movements of joints are *gliding*, common to all; *angular*, where we have flexion or extension; *abduction*, and *adduction*, as in elbow; *circumduction*, where the bone forms a cone the joint being the apex, as in hip; *rotation*, where a bone turns on itself, as the axis.

Joints are divided into those of the trunk and extremities.

Articulations of the Trunk.

Common Vertebral Articulation.—These are formed by the bodies, arches, and processes. The ligaments of the bodies are three. They are united by elliptical or *intervertebral discs* o fibro-cartilage, convex in front, and concave behind, fixed to the articular surfaces of the vertebræ. These consist of an external laminal and a central pulpy portion. The lamine are arranged concentrically, fibres and fibro-cartilage alternating, the fibres, curving from one bone to another, cross, and become attached to the articular surfaces. The central yellowish portion is fibro-cartilage, presenting nearly the character of true cartilage. On section, it appears conical. The discs do not exist between first and second cervical joints; are thickest in the neck and thinnest in the back, where they assist in forming socket for the ribs. The last lumbar is very thick, especially in the cow.

The *superior common* ligament is a shining ribbon, extending from the sacrum to the axis in the spinal canal on the superior part of the bodies of the vertebræ, to which, as well as the intervertebral substance, it is attached; it is broadest on the intervertebral substance. The spinal cord lies on it.

The *inferior common* ligament, situated below the vertebral bodies, stretches from the sacrum to the sixth dorsal vertebra. It is strongest in the posterior part of the dorsal and lumbar regions, and also broadest on the intervertebral substance.

Plate III

LIGAMENTS OF TRUNK

PLATE III.

HORSE.—LIGAMENTS OF TRUNK.

Fig. 1.—Ligaments of Atlo-Axoidal Joint, as well as of the other Cervical Vertebræ (the three first Cervical Vertebræ seen from below).

a. Inferior ligament of odontoid process. *b.* Intervertebral ligament.

Fig. 2.—Ligamentum Nuchæ.

a. Cord-like bands. *b.* The flattened bands. *c c c c.* Portions attached to the spinous processes. *d d d d.* Spaces filled up by cellular and elastic tissue. *e.* Opening above the spinous processes of first and second dorsal vertebræ. *f.* Continuation of the ligamentum nuchæ.

Fig. 3.—Ligaments of the Ribs.

a. The round ligament in position. *b b.* Its processes. (The spinal canal is opened).

Fig. 4.—Ligaments of Dorsal Vertebræ and Ribs, seen from below.

a. Anterior-internal ligament of head of rib. *b.* Posterior-internal ligament of head of rib. *c.* The intervertebral ligament. *d d.* Part of the anterior common ligament.

Fig. 5.—Ligaments of Dorsal Vertebræ and of the Ribs.

a. External-anterior ligament of tubercle of rib. *b.* External-posterior ligament of tubercle of rib. *c.* Intercrural ligament. *d.* Interspinous ligament. *e.* A part of the ligamentum nuchæ.

Fig. 6.—Ligaments of the Lumbar Vertebræ, Sacrum, and Pelvic Bones, seen from below.

a. Intertransverse ligament of lumbar vertebræ. *b.* Capsular ligament of the transverse processes of fifth and sixth lumbar vertebræ. *c.* Lumbo-sacral ligament. *d.* Inferior sacro-iliac ligament. *e.* Obturator membrane. *f f.* Transverse ischio-pubic ligament.

Fig. 7.—Ligaments of the Sacrum and Pelvic Bones.

a. Superior sacro-iliac ligament. *b.* Ligamentum sacrum. *c.* Lateral sacro-iliac ligament. *d.* Great sciatic ligament.

The *Ligaments of the Arches* are the *ligamenta subflava* which lie between the vertebral arches. They are highly developed in the Cow, filling up the spaces between contiguous bones. They are composed of two layers of yellow elastic tissue in the cervical, but of white fibrous tissue in other regions.

The *Ligaments of the Processes* are five in number. (1.) The *supra-spinous*, a white fibrous cord, extending from the spine of the sacrum, along the upper margin of superior spinous processes to the first dorsal vertebra, where it becomes continuous with the ligamentum nuchæ. (2.) The *inter-spinous* are placed between the superior vertebral spines, and consist of yellow elastic tissue in the cervical, and a double layer of white fibrous tissue in the posterior regions. (3.) The *inter-transverse*, which lie between the transverse vertebral processes. (4.) The *ligamentum nuchæ* or *colli* (Pl. III. fig. 2, see description of plate) consists of yellow elastic tissue, remarkable for its strength, elasticity, and insensibility. It is described as funicular and lamellar. The former, called also the cord of the ligament, extends from the first, second, or third dorsal spine to the tuberosity of the occiput, blending posteriorly with the superior spinous ligament, and may be traced to the lumbar region. The right and left ligaments meet in the mesian line, and are covered by fat. From the postero-inferior aspect spring the lamellar or true ligamentum nuchæ, which is flat and triangular, separating the muscles of the right from those of the left neck. It consists of two plates, joined by cellular tissue. The fibres descending from the cord or spinous process of the first four dorsal vertebræ, run obliquely forwards, to be inserted into the superior spines of the six posterior cervical vertebræ, blending with the interspinous. The two terminal slips, although widely separate, are connected by anastomosing branches, which form a large network. It is strongest at the bifurcated spine of the axis, and supports the weight of the head and neck. (5.) The *capsular ligaments* clothe the oblique or articular processes, forming true

synovial joints. (For Ligaments of vertebræ, see Pl. III. figs 4, 5, 6, and description of plate.)

Occipito-atloidean Articulation.—This joint is formed by the occipital condyles and articulatory atloid processes, and possesses seven ligaments—*two lateral capsular*, *two lateral styloid*, *superior suspensory*, *inferior suspensory*, and *inferior spinous*. The articulations are true synovial ones, having *two capsular ligaments*—one for each condyle. The *lateral styloid* passes from the styloid process of the occipital bone to the transverse process of atlas. The *superior suspensory* or *occipito-atloidean* is very broad, and consists of fibres, which cross each other, extending from the superior margin of foramen magnum to a notch on the upper part of the anterior border of the ring of atlas, along with the styloid. It blends with the capsular ligament. The *inferior suspensory* or *occipito-atloidean* stretches from a notch on the antero-inferior part of atlas to the inferior margin of foramen magnum. It is thin and membranous. The centre is strengthened by fibrous bands, which pass from the inferior spine of atlas to the basilar process of occipital.

Axo-atloid articulation.—This articulation is formed by the adjacent articulatory surfaces of atlas and axis. The ligaments are the *capsular*, the *superior* and *inferior spinous*, and *two short odontoids*. The *capsular* is broad, and attached around the posterior border of the atlas and the anterior border, and odontoid process of the axis. The *superior spinous* or *atloidean* passes from the supra-posterior part of the ring of atlas to the superior spine of vertebra dentata. The *inferior spinous* or *axo-atloidean* runs from the inferior spine of atlas to the inferior spine of axis. The pair of *short odontoids* spring from the anterior part of odontoid process, and pass to the inner and rough portions of the wing of atlas. (Pl. III. fig. 1. See description of plate.)

The *Occipito-axoidean ligaments* are the *long odontoid* and *occipito-axoidean*. The *long odontoid* springs from the odontoid process, and is inserted on the inner and lateral aspect of occipital

condyles. The *occipito-axoidean* stretches from the body of vertebra dentata to the basilar groove of occiput, blending with the inferior common ligament. The occipito-atloidean articulation performs lateral motion, elevation or extension, depression or flexion, and extensive circumduction; the axo-atloidean, rotatory motion only.

Temporo-maxillary Articulation.—The ligaments are *two capsular*, *postero-lateral*, and *inter-articular cartilage.* The joint is formed by the condyle of the inferior maxilla and the glenoid cavity of the squamous temporal. The *fibro-cartilaginous pad* is irregular, flattened from above downwards, broader at its sides than centre. The superior surface is concavo-convex, for adaptation with the condyles and glenoid cavities of squamous temporal bone. Its inferior surface presents an oblong fossa for the reception of the condyle of lower jaw. The *capsular* are on either side of the fibro-cartilage. The *lateral pair* run from the mastoid process and zygomatic arch of the temporal to the inferior maxilla, and are mere thickenings of the capsular ligaments. This joint possesses lateral motion, elevation, extension, flexion, and gliding.

Sacro-lumbar Articulation.—This joint is formed by the last lumbar and first sacral vertebræ, four capsular ligaments, and *inter-articular fibro-cartilage.* The latter is very large in the cow. *Two* of the *capsular* are for the *oblique* and *two* for the *transverse processes.* The *superior* and *inferior common ligamenta subflava* and *intertransverse* persist.

Thoracic or *Costo-vertebral Articulation* (Pl. III. figs. 3, 4, 5, and description of plate).—The joints are formed by the head and tubercle of a rib, and the facets on the body, and transverse processes of a dorsal vertebra. The ligaments are seven in number. The *stellate* or *inferior radiating* consists of strong fibres, divided into three fasciculi—one uniting the head of a rib to the vertebra in front, a second to the inter-vertebral substance, while the third passes to the vertebra behind. The *inter-articular* passes from the ridge on the head of the rib on

one side across the body of the vertebra, and joins the follov rib on the opposite side, dividing the head of the rib into tw distinct articulations. The *two capsular* are as follows:—on for the anterior half of the head of the rib and the vertebra i front, the other for the posterior half and vertebra behind. Th *anterior costo-transverse* unites the neck of the rib to the infero anterior part of transverse process of vertebra. The *posterio costo transverse* passes from the supero posterior part of tuberc to superior part of the transverse process. One *capsular ligamen* unites the tubercle and transverse process.

Costo-sternal Articulation.—This joint is formed by the ste num and true costal cartilages. The ligaments are three. Th *capsular*, for the articulation of the rib cartilages with the alveol on the side of sternum. The *superior* and *inferior costo-sterna* stretch from the costal cartilages to the sternum above and below blending with the capsular.

In the Ox there is a true synovial joint, and capsular ligamen between the rib and its cartilage. In the Horse it is a fixe gomphosis.

Sternal Articulation.—This joint binds together the sterna segments. The ligaments in the Horse are the *superior sternal* extending along the upper surface of the bones, and the inte vening *fibro-cartilage* which speedily ossifies.

The Ox has a superior, inferior, and two lateral ligaments and a capsular ligament between the first sternal bones.

Chondro-costal Articulations.—These are fixed joints betwee the ribs and cartilages; each rib is cupped on its lower extr mity, the convexity of the cartilage resting in it, and the join is clothed around with strong fibrous tissue.

Sacro-iliac Articulation. (See Pl. III. figs. 6 and 7, and d scription of plate.)—This joint is formed by the inner aspect the ilium, and supra-lateral surface of sacrum. The ligament are five in number. The *fibro-cartilaginous pad* is interpose between the transverse process of sacrum and the venter of ilium synovia may be present. The *sacro-iliac ligaments* consist

strong bundles of fibres, which envelope the fibro-cartilage, and are attached above to the transverse process of the sacrum, and below to the venter ilii. In the cow, prior to parturition, this ligament lengthens, forming the slackening seen in front of the croup. *Superior ilio-sacral*, very short and strong, stretching from the spines of sacrum to posterior spine of ilium. *Inferior ilio-sacral* is triangular, the fibres running obliquely backwards, and it is attached above to the posterior angle of the ilium below to the lateral borders of the sacrum. The *sacro-sciatic*, a broad membranous expansion, is situated at the sides of pelvis, and helps to close up the cavity. It is irregularly quadrilateral, attached superiorly to the lateral borders of the transverse processes of the sacrum and first two or three coccygeal vertebræ; inferiorly, to the superior ischiatic spine and tuberosity of ischium. Between the insertions at the ischiatic notch is a passage for various structures, and at the anterior border an irregular opening, the greater sciatic notch, through which pass the gluteal vessels and sciatic nerves. The posterior border consists of two layers, embracing part of the biceps rotator tibialis, and blending with the aponeurosis of the coccygeal muscles. The external surface is covered by the sciatic nerves and muscles, and is lined internally with peritoneum.

In the Cow it is much stronger, and contains yellow elastic tissue, which is not present in the horse. This enables it to stretch during parturition; in difficult cases, division of this ligament at the tuberosity of the ischium has been performed with success.

Ischio-pubic Articulation.—This articulation is formed by the respective surfaces of the ischium and pubis. The *ischio-pubic symphysis* in the young consists of fibro-cartilage and white fibrous tissue, which ossifies in old age.

The *Obturator ligaments* are thin membranes in quadrupeds, almost closing up the obturator foramina, a small passage being left for the exit of vessels.

The *Ligaments of the Os Hyoides* are three. The *temporo-*

hyoid articulation is amphiarthrodial, the superior angle of th greater cornua articulating with the hyoid process by an elasti cartilage. The *inter-hyoid* articulation is also amphiarthrodia an elastic cartilage joining the greater and lesser cornua. Th latter articulate with the body by a true synovial *capsular* joint In the Ox a ligament unites the two lesser cornua.

Articulation of the Fore-Extremities.

(Pl. IV. figs. 1, 2, 3.)

The *Scapulo-humeral articulation*, or Shoulder-joint, is formed by the glenoid cavity of the scapula, and the articular head o the humerus. It is a ball-and-socket joint, with one stron capsular ligament. The bones are held in position by muscle passing from the shoulder blade to the arm, where the flexo brachii glides through the bicipital groove, the tendon of th muscle being clothed with a synovial bursa. The motion o the joint is angular, lateral, and circumductive.

The *Humero-radio-ulnar*, or Elbow, is a hinge joint, forme by the radius, ulna, and humerus. It has three ligaments. Th *capsular* is extensive, and is strongest in front. It stretche from the inferior end of the humerus to the head of the radius and posteriorly it encloses the articulation of the ulna with th humerus; and it also surrounds the double articulation betwee the head of ulna and radius. Anteriorly, it is attached to th tendon of the flexor brachii; posteriorly, to that of the anconeu muscle. The *internal lateral* (Pl. IV. fig. 1, *a*) is crucia longer, but not so strong as the external. It stretches from small tuberosity on the inner side of the internal condyle of th humerus to the head of the radius. The *external lateral* (P IV. fig. 1, *b*), crucial, short and thick, passes from a ridge o epitrochlea, and a cavity on its outside, to a tuberosity on th outer head of the radius, and is separated from the skin b aponeurosis. The joint performs flexion and extension.

The *Radio-ulnar Articulation* is formed by adjacent surfaces o

PLATE IV.

LIGAMENTS OF THE EXTREMITIES.

Fig. 1.—Ligaments of Elbow, along with those between the Radius and Ulna.

a. External lateral ligament of elbow joint. *b*. Internal lateral ligament. *c*. External transverse ligament between radius and ulna. *d*. Internal transverse ligament between these bones.

Fig. 2.—Common and Special Ligaments of the Knee Joint, seen from the front.

a. Internal lateral ligament. *b*. External lateral ligament. *c*. Interosseous ligaments of upper row. *d d d*. Interosseous ligaments of lower row.

Fig. 3.—Special Ligaments of Knee Joint seen from the inner side, behind.

a. Superior-internal ligament. *b*. Inferior-internal ligament. *c*. Posterior oblique ligament. *d*. Interosseous ligament.

Fig. 4.—Special Ligaments of Tarsal Articulation, seen from the inner side.

a. Internal lateral ligament. *b b b b*. Interosseous ligaments.

Fig. 5.—Ligaments of Posterior Knee Joint, Patella, and Inter-articular Cartilage, seen from behind.

a. External transverse ligament of patella. *b*. External lateral ligament of knee joint. *c*. Posterior crucial ligament. *d*. External inarticular cartilage. *e*. Internal inarticular cartilage. *f*. Posterior-superior ligament of external inarticular cartilage. *g*. Posterior-inferior ligament of external inarticular cartilage. *h*. Interosseous ligament of tibia and fibula.

Fig. 6.—Ligaments of Posterior Knee Joint and Patella, seen from the inner side.

a. Internal lateral ligament of knee joint. *b*. Internal transverse ligament of patella. *c*. Internal straight ligament of patella. *d*. Middle straight ligament of patella. *e*. External straight ligament of patella.

Fig. 7.—Common Ligaments of Tarsal Articulation, seen from behind and within.

a. Internal lateral ligament. *b*. Posterior or calcaneo-metatarsal ligament.

he radius and ulna, and has three ligaments. The *arciform*, ttached to the superior part of the ulna and radius. They are urved, and blend with the lateral. Below the arch is a few ibres, which constitute the *inferior radiating*. The surfaces eneath the radio-cubital arch are joined by the *interosseous*, which ossifies in old age (Pl. IV. fig. 1, *c*, *d*).

Carpal Articulation.—The KNEE consists of several joints—1, articulations between the bones of the upper row, *superior carpal;* 2, between the bones of the lower row, *inferior carpal;* 3, between the radius and upper row, *radio-carpal;* 4, between he upper and lower rows, *inter-carpal;* 5, between the lower row nd metacarpal bones, *carpo-metacarpal;* 6, 7, those common to he entire knee, *carpal* (Pl. IV. figs. 2 and 3, and description of lates).

1. *Superior Carpal.*—The *upper row* consists of four bones, rticulating by diarthrodial facets on their lateral surfaces. They re held together by *six ligaments*, *three anterior* and *three nterosseous*. The *anterior* are flat bands which unite the caphoid to the lunar, the lunar to the cuneiform, and the uneiform to the trapezium. The two first are covered by, and ttached to, the anterior common ligament; the third is covered y the external lateral ligament. The *interossei* are attached to he roughened grooves between the articular facets on the lateral urfaces. Those uniting the scaphoid to the lunar, and the unar to the cuneiform, are covered by the anterior; that join-ng the cuneiform to the trapezium by the posterior common gament.

2. *Inferior Carpal.*—The *lower row* usually consists of three ones, articulating by lateral facets, held together by *four liga-ents*, *two anterior* and *two interosseous*. The *anterior* are flat; ne one connecting the trapezoid and the magnum is covered by ne internal lateral, that between the magnum and the unciform y the anterior common ligament. The *interossei* are two; the ne joining the magnum to the trapezoid is covered by the an-rior ligament, the other separated from it by an articular facet.

3. *Radio-carpal Articulation.*—The radius is joined to the upper row by *three special* and *four common* ligaments. The *special* are the *large round* ones stretching obliquely from the lower extremity of the radius, under the posterior common ligament, to the scaphoid. A *second* small one stretches from the external side of the inferior extremity of the radius to the superior border of the trapezium, partly covered by the external lateral ligament. A *third*, the smallest of all, is buried under the former, and stretches from the inferior part of the radius under the insertion of the first to the os lunare.

4. *Inter-carpal articulation.*—It has also *four common* ligaments and *three special* ones; two are short, and situated behind the knee, under the posterior common ligaments. The *first* runs vertically from the scaphoid to the magnum and trapezoid; the *second* passes obliquely from the cuneiform to magnum; while the *third*, the strongest, stretches from the trapezium to the cuneiform and head of the external splint bone, blending externally with the posterior common ligaments.

5. *Carpo-metacarpal articulation.*—Besides the four common, this joint has six special ligaments—*two anterior*, *two superior* and *two interosseous*. The *first anterior* consists of two bundles, and unites the os magnum to the large metacarpal. The *second anterior* binds the cuneiform to the external splint. The *two posterior* bind the magnum and trapezoid to the large and inner small splints. The *interossei* unite the heads of the small splints to the large metacarpal and bones of lower row. The *synovial capsules* are *five*—*two small* and *three large*. Of the former, one is for the radius and the upper row, extending between them as far as the interossei, and the other passes between the upper and lower rows. Of the latter, one passes between the lower row and common bones, dipping between the large and small splints, a second between the trapezium and cuneiform, and the third is for the pisiform, when present.

6, 7.—The *four Common Ligaments* are the *external* and *internal lateral*, and the *anterior* and *posterior* common, or *cap*

sular. The *internal lateral* is crucial, and consists of two bundles of fibres which cross each other, both springing from the internal sides of the inferior extremity of the radius; the superficial bundle going to the os magnum and large metatarsal, and the deep set to the scaphoid, trapezoid, and inner small splint. The *external lateral* also consists of two fasciculi. It springs from the external-lateral side of the lower end of the radius, the superficial fibres passing down to be inserted into the outer small splint. The deep bundle are attached to the cuneiform, unciform, and external small splint. The *anterior common* or *capsular* is membranous, covering the anterior portion of the knee. Part of this ligament is attached to the radius, the head of the large metacarpal and the lateral ligaments, and the remainder is attached to the upper and lower bones and their anterior ligaments. The inner surface is smooth, and lined by synovial membrane. The *posterior common* ligament is the *strongest in the body*. It covers the posterior surface of the carpus, levelling up asperities. It passes from the lower end of the radius to the head of the metacarpus magnus, adhering externally to the ligament of the trapezium and splint bones. Its anterior surface is attached to the two rows of bones, while its posterior is smooth, for passage of the special large round ligaments of the radio-carpal articulation. The inferior carpal ligament is continuous with it.

The movements of the knee between the upper row and radius, and between the two rows, are extension, flexion, and slight circumduction; between the lower row and metacarpal bones, gliding.

The *Carpal ligaments* are two, the superior and the inferior or metacarpal, which pass from the head of the metacarpus to the tendon of the flexor pedis perforans.

The *Inter-metacarpal articulation* is formed by the cannon bone and small splints. The latter are attached to the former by *interosseous ligaments*, which ossify in advanced life.

The *Metacarpo-phalangeal articulation*, or fetlock joint, is

formed by the metacarpus magnus, os suffraginis, and a pair sesamoids. There are two sets of ligaments, *proper* and *acce sory*. The former consist of capsular and two lateral. Th *capsular* runs from the lower end of the metacarpus magnus t the head of the os suffraginis and sesamoids. The *lateral* pa are crucial, stretching from the infero-lateral aspect of the met carpus to the supero lateral surface of the suffraginis.

The *Accessory ligaments* are the *seven sesamoids*. The *superi suspensory* or sesamoidean is a long, strong band, consisting white and yellow fibres. It arises from the posterior part the lower row of the carpus and the head of the metacarpal passing behind the cannon and between the small splints. bifurcates, and is attached to the summits of the sesamoid whence it passes downwards as *lateral suspensory*, reuniting, a the *broad ligament*, at the antero inferior part of the os suffr ginis, where, after *again subdividing*, it travels along the latera front of os coronæ, terminating there, and on either side of th pyramidal process of os pedis, being also attached to the tendo of the extensor pedis. The *inferior sesamoidean* consists of *thre* —the *external* bundles, or long inferior; *middle*, or short; an *internal*, or crucial. The *external* is Y-shaped, and runs fro the base of the sesamoids to the supero-posterior part of the coronæ. The *middle* one is V-shaped; arising from the base the sesamoids, it passes to the triangular ridge on the back of th suffraginis. The *internal* likewise travels from the base of th sesamoids to the superior part of the posterior face of the suffraginis, its fibres intercrossing. The *lateral sesamoidean external* and *internal*, are two thin layers, passing from th relative angles of the sesamoids to the tubercles on the latera aspect of the os suffraginis. Posteriorly, the sesamoidean bone are connected by the *interosseous*, or inter-sesamoidean, an covered by fibro-cartilage, which forms a smooth groove for th passage of the flexor tendons, increasing their leverage. Th motion of this joint is flexion and extension.

The *Proximal Interphalangeal articulation*, or pastern join

is formed by the suffraginis and the os coronæ. It has *five ligaments*. The *capsular*, which extends from the articular margin of one bone to that of the other. The *lateral* pair are crucial, springing from the lower end of the suffraginis. They pass obliquely downwards to the postero-lateral aspect of the os coronæ. The *two posterior straight* run from the dorsal surface of the suffraginis to the os coronæ, on either side of the insertion of the external bundle of the inferior sesamoidean.

The *Distal Inter-phalangeal articulation*, or coffin joint, is formed by the os coronæ and navicular. The ligaments are *special* and *navicular*. The *three special* are *capsular*, which includes the articulation formed by the three bones attached to the extensor tendon in front, and flexor behind. The *antero-lateral*, which are crucial, and spring from the imprints on the lateral aspect of the os coronæ. They are inserted into two depressions at the superior border of the os pedis, partly covered by the lateral cartilages. The *postero-lateral* is a continuation of the lateral ligaments of the pastern, which, after reaching the os coronæ, form an elastic fibrous cord, attached to the upper border of the navicular—the two uniting to form the *superior broad ligament*. They give off short bundles, which become attached to the retrorsal processes and inner surface of the lateral cartilages. The *navicular ligament* is the *superior broad* or *interosseous*, which is attached to a roughened portion on the outer border of the navicular and the semilunar ridge of the os pedis. The motion of the joint is flexion and extension.

Articulations of Hind Extremity.

(Pl. IV. figs. 4, 5, 6, 7.)

The Hip Joint.—This joint is a ball and socket, and is formed by the acetabulum in the os innominatum and articular head of the femur. It has five ligaments. The *capsular*, which grasps the brim of the acetabulum and roughened edge of the head of femur; the *cotyloid*, which circles round and deepens

the acetabulum ; the *transverse*, which stretches over the cot loid notch, completing the cavity of the acetabulum, and secur the round and pubio femoral ligaments; the round or *ligame tum teres*, which arises from the notch in the head of the femu and is inserted into the centre of the cotyloid cavity ; the *pubi femoral*, which arises from the head of femur, alongside of th round ligament, passes through the cotyloid notch below th transverse, then alongside the groove on the under side of th pubis, meeting and crossing its fellow in front of the symphysi being finally lost in the abdominal fascia. It is only found i the Horse, and by forming a X with its fellow, the head of th right femur is attached to and kept in position by the muscle of the left side, and *vice versa*. As it passes over the pubis, synovial bursa is interposed. In the Ox there is no transvers ligament, the cotyloid notch not being so complete as in th horse. The motion of the joint is flexion, extension, abduction rotation, and circumduction.

The Stifle Joint.—This articulation is formed by the trochle and condyles of the femur, tibia, and patella (Pl. IV. figs. and 6, and description of plate). The ligaments are *proper* c *femoro-tibial*, and *accessory* or *patellar*. The *accessory* are *si* in number. *The capsular*, which is attached round the trochle of the femur and the articular surface of the patella. It i capacious, admitting of great freedom of motion; between it an the synovial membrane is interposed a cushion of fat. Th *lateral ligaments, internal* and *external*.—The *internal* is th smaller, arising from the internal lateral aspect of the femur, jus above the internal condyle ; it is inserted into the correspondin surface of the patella. The *external* arises from the externa lateral surface of the femur, just above the external condyle, an is inserted into the corresponding side of the patella. The *thre straight ligaments* arise from the anterior surface and inferio border of the patella, and are inserted into the anterior aspec of the tuberosity of the tibia. The *femoro-tibial ligaments* ar thirteen. The *semilunar* half moon or scythe-shaped cartilage

re *two* fibro-cartilaginous discs interposed between the condyles of the femur and head of tibia. The internal is the arger and thinner. Their internal borders are sharp and concave, embracing the tibial spine, while the external are thick nd convex. Their superior surfaces are hollowed for the reception of the femoral condyles; the inferior are smooth and lat, resting on the tibia. Their extremities terminate in ligaments which attach them to the bones. These are the *coronary* —*five* in number, *two* for the *internal* discs—one anterior, ttaching it to an excavation in front of the tibial spine; the ther, posterior, fixes it to a furrow behind the tibial spine; and *three* for the external disc—*one* in front of the tibial spine, and *wo* behind it. The superior one is longer and stronger, being nserted into the lower part of the femur, while the inferior is hin and flat, and passes to the head of tibia. *Two capsular*, *xternal* and *internal*.—The *internal* passes from the internal ondyle of the femur to the semilunar cartilage and head of the ibia; the *external* from the external condyle of the femur to the emilunar cartilage and head of the tibia. These ligaments consist of white and yellow fibres which cross each other, meeting at he crucial between the cartilages. They form the *ligamentum mucosum* or longitudinal ligament, which is continued up etween the condyles. The *crucial* or interosseous, *anterior* and *osterior*, are situated between the condyles of the femur and the ibial spine. The *anterior*, or internal, stretches obliquely forwards, and is attached to the excavation between the condyles, r to the external condyle of the femur and a depression in front f the tibial spine. The *posterior*, or external, the longer, passes bliquely backwards, arising anteriorly from the inner part of the nternal condyle. It is inserted posteriorly into a small eminence ehind the inner articular half of the head of the tibia. These igaments are very strong, and consist of fibres which cross each ther, interlacing with the longitudinal ligament and the *lateral*, *rucial*, *external*, and *internal*. The *external*, the shorter and tronger, arises from the external condyle of the femur, and passes

to the heads of the tibia and fibula, coursing through a synovial groove on the external tuberosity of the tibia. It is separated from the capsular ligament by the tendon of origin of the popliteus. The *internal* arises from the internal condyle of femur, and is inserted into the internal lateral aspect of the head of the tibia. The motion between the tibia and femur is angular; between femur and patella, gliding.

The *Tibio-fibular articulation* is formed by the adjacent surfaces of tibia and fibula. This is a diarthrodial articulation. The ligaments are a *small irregular* one between the head of the fibula and the external tuberosity of the head of the tibia and the *interossei*, which divide into *superior* and *inferior*. The former is a small bundle at the upper third of the fibula; the latter consists of a broad membranous expansion, extending from the middle to the lower extremity of the fibula, and a ligamentous cord, which extends from the apex of the fibula to the postero-external part of the distal extremity of the tibia.

The *Tarsus* or Hock (Pl. IV. fig. 4, *a*, *b*, *b*, *b*, *b*) should be studied on the same plan as the knee; it likewise consisting of several secondary articulations:—

1. The *ligaments common* to the whole joint—*external* and *internal lateral*. The *internal* is a *triplet* formed of three fasciculi of fibres—superficial, middle, and deep. The superficial, the longest and strongest, arises from the internal malleolus of the tibia, becomes attached in its passage downwards to the astragalus, the three cuneiforms, and, finally, to the large and inner small metatarsals. The middle fasciculus, consisting of two cords, likewise arises from the internal malleolus of tibia, one division passing backwards to become attached to the astragalus; the other reaches the os calcis. The deep fasciculus is very small; it arises from the internal malleolus, and is inserted into the astragalus. The *external lateral* consists of two fasciculi—superficial and deep. The superficial is strong and flat, arising from the external malleolus of the tibia. It is inserted into the astragalus, os calcis, cuboid, large and small external metatarsal

bones. The internal or deep fasciculus is short; arising from the external malleolus of the tibia, it passes obliquely backwards to the lateral aspect of the astragalus and calcis. The external and internal bundles intercross each other.

2. Two *capsular—anterior* and *posterior*. The former is very strong, and attached superiorly to the anterior part of the articular surface of the lower extremity of the tibia, to the anterior aspect of the inferior border of the astragalus, to the cuneiforme magnum and medium, and to the lateral ligaments; inferiorly, it terminates on the transverse ligament, which stretches from the astragalus to the large metatarsal bone. The posterior is attached superiorly to the posterior part of the tibia; inferiorly, to the os calcis and astragalus; and, laterally, to the lateral ligaments. There is a fibro-cartilaginous disc in its centre, over which glides the flexor tendon, protected by a synovial bursa.

3. The *ligaments between astragalus and calcis* are *four—one superior, two lateral*, and *one interosseous*. The *superior* stretches from the upper part of the pulley of the astragalus to the calcis. The *lateral* are very thin, and covered by the lateral tarsal ligaments. The *interosseous* is strong, occupying the greater part of the rough excavation between the articular facets of the bones.

4. The *ligaments between the bones of the lower row*. They are *six—two anterior, one superior, three inferior*, which join the cuboid to the large and middle cuneiform bones. *Two interossei* correspond to the anterior ones; *one interosseous* between the large and the other two cuneiforms, and *one* between the middle and small cuneiforms.

5. The *calcaneo-cuboid* or superior straight ligament stretches from the posterior part of the apex of the calcis to the posterior part of the cuboid, terminating on the head of the small external metatarsal. Laceration of this ligament constitutes curb.

6. The *inferior straight* passes from the lower end of cuboid to the small external metatarsal.

7. *Transverse, oblique*, or *astragalo-metatarsal*. Arising from

the antero internal side of the astragalus, it becomes inserte into the cuneiforme magnum and medium, the large metatarsa and the anterior capsular ligament.

8. The *plantar* is a strong ligament, which unites posteriorly all the bones of the hock to the three metatarsals. It i smooth, for the passage of tendons.

9. The *interosseous*, which unites the os calcis and astragalu above to the cuboid and cuneiforme magnum below.

There are two *synovial membranes* for the true hock, on between the astragalus and tibia in front, and another behind and there is also a synovial membrane between the lower row and the three metatarsals, stretching down between the larg and small ones.

The *tarsal ligaments* are—the *superior*, attached to gastroc nemius internus; the *inferior*, or metatarsal, to the flexor pedis The *inter metatarsal*, *metatarso phalangeal*, and *inter phalangeal* are distributed like their homologues in the fore limb.

MYOLOGY.

Tendons are the terminations of muscles. They possess grea power of resistance; are white, and either round or flat. One o their extremities is continuous with the muscle; the other attached to the osseous system, transmits dynamic action t the parts which the muscles move. It is uncertain how th muscular fibres and tendons unite—probably by continuatio and condensation of the sheaths which enclose and help to for the muscular fibrillæ. They are sometimes prolonged into th fleshy portion, forming several strong bands which offer man points of attachment, constituting a *radiating* muscle; anot they form an intermediate cord, constituting a *digastric* muscle They may form transverse or oblique bands, which effectuall augment and support muscular contraction; or the fibres ma converge towards the tendon on both sides, like the barbs of feather, forming a *penniform*; or to one side, producing a *semi*

penniform; or they may originate by two or three bundles, constituting a *biceps* or *triceps* muscle.

Tendons vary much in form, size, and density, but all consist of longitudinal slender fibres, with serrated edges, running parallel, and united to each other by cellular tissue. They are very strong and resistant, the bone frequently breaking before the tendon gives way.

Aponeuroses are flattened or expanded tendons, consisting of white fibrous tissue, one side being continuous with the muscle, the other attached to the bone.

The most remarkable property of muscular fibre is its irritability; contraction results from physical, mental, or organic stimuli, which are always conveyed directly, through the medium of the nerves, or by reflex action.

Muscular nomenclature is neither satisfactory nor explicit. What is derived from human anatomy is frequently inappropriate.

Percival follows in the wake of Shape, Stubbs, and others, naming some muscles from their form, as trapezium, rhomboideus, scalenus; others, from their use, as flexors, extensors, adductors, abductors; some from their direction, as recti, transverse, oblique; others from situation, as temporalis, peroneus, subscapularis; some, again, from their attachment, as sterno-maxillaris, coraco-radialis, and stylo-hyoideus; and some even from their comparative size, as magnus and parvus.

In studying muscles, there are certain considerations to be borne in mind—situation, form, direction of fibre, attachments, relations with contiguous organs—as well as their actions. In describing their attachments certain terms are used; thus that extremity of a muscle which is connected to some fixed or partially movable part is called its origin or head; the other extremity, attached to the part to be moved, its insertion or termination. As a rule, the tendon of insertion is always longer than that of origin, which is frequently rudimentary; the intermediate portion is termed the belly or body.

The usual method of classifying muscles is to arrange them

into groups, in conformity with the anatomical divisions of the body, as those of the head, neck, trunk, fore and hind extremities,—subdividing these into regions, as the cervical into superior and inferior.

Fascle.—Each group is bound down by strong membranous expansions of white fibrous tissue, called *fasciæ*, which are firmly connected with the bone. This term is, however, applied to other membranous expansions, differing very materially in strength, texture, appearance, connection, and uses. For example, lying immediately below the skin there is an imperfect membranous expansion, which forms a continuous covering over the whole body, composed of cellular tissue more or less condensed. This has led to the division of fasciæ into *cellular* or *superficial*, and *deep aponeurotic* or *aponeurosis*.

Superficial fascia consists entirely of cellular tissue, varying in thickness in different regions of the body. Where the skin is loose it is most distinct. Sometimes it is inseparable from subcutaneous cellular tissue, muscles and skin, as in the eyelids and lips. Its meshes may be filled with adipose tissue, or condensed and so destitute of fat as to form a fibro-cellular membrane; its use is to allow freer action.

Aponeuroses consist entirely of white and yellow fibrous tissue. They are divided into fasciæ, connected with muscular fibres, and called *aponeurotic tendons*, as in the abdominal muscles, and those which bind down and cover the soft parts called *aponeurosis of investment*. They not only bind down the muscles, but afford processes between them, which become united to, and blend with, the periosteum. Some of these fasciæ have distinct muscles for rendering them tense, as the fascia lata. There is a third class of fibrous expansions termed fascia, found chiefly in connection with the walls of cavities, as the iliac and pelvic.

Investing fascia are of considerable importance, maintaining the organs they cover *in situ*, and, by exerting pressure on the muscles, not only regulate combined but isolated action.

Examine the arm or thigh where the muscular bellies form lengthy masses, with long tendons attached to bones at considerable distances apart, and it is at once apparent that there would be displacement during motion, were it not that in these parts the fascia is very strong, enclosing the body of each muscle in a sheath.

Strong layers of white fibrous tissue bind down and secure tendons during muscular action, as in the hock and knee, where broad strong bands are joined to the bones, forming what are called *anterior* and *posterior annular ligaments.* The same arrangement exists at the fetlock, where the flexor tendons pass over the sesamoids. These are lined with synovial membranes, to facilitate motion.

Muscular Tissue.—Before studying the muscles individually, it is necessary to understand the composition of muscular tissue. In addition to muscular tissue, other elements enter into a muscle, viz., nerves, blood-vessels, absorbents, areolar and fibrous tissue.

Muscular tissue is the name applied to contractile fibres, which are either collected into bundles connected at their extremities, forming distinct organs termed muscles, to which the familiar name flesh or meat is applied, or found disposed around cavities, as the heart, or interposed between the coats of hollow organs or viscera, as the intestines.

Muscular tissue is reddish, varying in intensity, and palest in those fibres disposed around the viscera. Two varieties are recognised—*voluntary* and *involuntary. Voluntary* or *striated fibres* constitute the muscles of animal life; they are usually collected into bundles, furnished with tendons at either extremity, which attaches them to bones, are under the influence of the will, and can be excited to action by volition. *Involuntary* or *smooth fibres* constitute the muscles of organic life, chiefly exist around hollow viscera, and are beyond the control of the will.

All muscular tissue in the living body contracts and relaxes more or less rapidly under stimuli transmitted through the

medium of the nerves; it also possesses great power of resis ance; when dead, it loses these properties. Voluntary an involuntary muscular fibres differ in the mode by which the are excited to act, and in their anatomical structure. Th former are uniform, and marked by transverse parallel line situated at regular distances; whereas the latter are homo geneous, smaller, flattened, and nonstriated, the only exception being some fibres of the œsophagus and heart, muscles of interna ear and urethra, which, although beyond the control of the will are striated.

Voluntary striped muscular fibres are gathered into masse forming solid organs, called muscles, which vary in form an volume according to their functional movements. Each ulti mate fibre terminates at either extremity in fibrous tissue, b means of which they are attached to the bones, and which, ac cording to the disposition of its fibres, forms rounded o flattened cords called tendons or membranous lamina aponeu rosis. The intermediate fleshy portion, the belly, is of a variabl red colour. This is composed of bundles, called *fasciculi* o lacerti, which consist of smaller bundles, and these again c ultimate fibres. The microscope declares these fasciculi to con sist of fine filaments termed *fibrilla*, which run parallel wit each other, maintaining an undivided course throughout; th fascicular fibres likewise extend continuously from one end c the belly to the other, or from one terminal tendon to the othe converging towards their tendons. Each ultimate fibre is en closed in a delicate tubular sheath called the *sarco* or *myolemma* This tube sheath is composed of a transparent and apparentl homogeneous membrane, very tough, elastic, and excessivel fine, which isolates each fibre from surrounding parts; th sheath, owing to its toughness and elasticity, frequently re mains entire after rupture of the enclosed fibrilla. The fibre about $\frac{1}{200}$th of an inch large in the male, are gathered to gether into prismatic or polyhedral fasciculi, and invested wit a sheath of areolar tissue, which extends between each fibr

The larger bundles have likewise an investing sheath of areolar tissue, which passes inwards; the entire muscle having a similar arrangement. This areolar tissue is composed of white and yellow fibres, its use being to connect the bundles together, and to serve as a medium for the ramification of vessels, nerves, and absorbents. Examine an ultimate fibre with a microscope of 300 diameters, and longitudinal waving striæ or lines are seen; these are the fibrillæ from which the name "striated" is derived;—and about $\frac{1}{5000}$th of an inch apart there are also transverse striæ, which cause the fibrillæ to appear like rows of beads; these are the sarcous elements, and appear like dark quadrangular bodies with bright spaces between and around them, in which reside the contractile power of the muscle within the sarcolemma. The fibrillæ are so arranged that the dark central portions are placed side by side, the intervening clear portions lying on the same plane across the fibres. Cleavage of muscular fibre may occur in the longitudinal direction, forming fibrillæ, or transversely, constituting discs.

Involuntary smooth muscular fibre is simple in structure, pale in colour, and consists of flattened fusiform bands, with a homogeneous texture, presenting ever and anon a bulged appearance, due to the elongated corpuscles which they contain. These bands are formed into bundles by an interstitial substance, and bound into fasciculi by areolar tissue. They are not invested in a sarcolemma; their termination is uncertain; and it is questionable whether each fibre surrounds the viscus as a ring, or spiral, or vertically clothes the tube, the circle being completed by another fibre. It is also uncertain whether the areolar tissue in connection with these fibres unite with their extremities, or simply involve them in their meshes. The unstriped fibre is very abundant, existing in all parts where a distinct contractile power is required, as the alimentary canal, bronchial tubes, bladder, and uterus.

Areolar, cellular, or *connective tissue* is the most diffused element of organisation, constituting the basis of every animal. It has an uninterrupted continuity throughout the body, and

consists of numerous delicate semi-transparent filaments, which intercross each other, leaving interspaces which freely communicate. These areolæ are cells of the tissue which, in health, always contain a thin albuminous fluid, resembling blood serum, or the secretions of serous cavities, hence called *cellular serosity*. Its functions vary. It unites and keeps the organs *in situ*, and facilitates their movements by its lubricating fluid. It is more abundant in voluntary muscles, not only investing the fasciculi, but, penetrating between the fibres, forms septa, which enables each fibre to act in some measure independently. Its chief use is to support the supply vessels; had these been attached to the contractile fibres, they would have been liable to undue compression or dilatation.

The blood vessels of a muscle are abundant. Each artery is accompanied by twin veins. The capillaries are arranged in longitudinal and transverse networks, corresponding with the striæ in the fibres.

The nerves of voluntary muscles are large, and branch into sets, which form arches, loops, or plexuses amongst the fibres. Straight branchlets are said to end in and mingle with the fibrillæ; little is known about the lymphatics.

APONEUROSES AND MUSCLES.

Subcutaneous Region.

After removing the skin and subcutaneous cellular tissue, the first muscle which presents itself is peculiar to quadrupeds, viz., the PANNICULUS CARNOSUS OR MUSCULUS SUBCUTANEOUS. This fleshy panniele is spread over the whole body, and divided into facial, cervical, thoracic, and abdominal. The facial portion consists of an aponeurotic expansion, which passes over the cheeks and face, becoming muscular over the masseter and anterior part of the zygoma. Its fibres now diverge and are inserted into the angle of the mouth, forming the retractor anguli oris, the laughing

muscle (Santorini). Posteriorly, it unites with the cervical portion; this is likewise chiefly aponeurotic, and commences in front of the neck by a thin muscular portion, which joins its fellow by a fibrous raphe, covering the muscles of inferior cervical region. As it proceeds upwards, it gradually thins, while infero-laterally it becomes more fleshy, and is inserted into the anterior portion of the cariniform cartilage. Some describe this as a part of the levator humeri. The scapular portion is continuous with the cervical at the sternum by fascia, which is carried over the front of the shoulder, becoming fleshy on the outer side of flexor brachi. It runs up the point of the elbow, and joins the fascia of the arm. Superiorly, it encloses the entire external side of the shoulder, and is attached to the dorsal spines along with the trapezium. The abdominal portion forms a broad oval-shaped fleshy expansion, its fibres running from the shoulder to the flank. Anteriorly, it joins the scapular aponeurosis. On the supero-lateral sides of the abdomen, it is thick and fleshy, especially behind the arm, below which it sends a tendinous expansion which penetrates between the caput muscles and the chest, and gets attached to the pectoralis magnus and internal trochanter of humerus. Posteriorly, by a strong band, fleshy and aponeurotic, it is inserted into the stifle joint and fascia of the thigh. Above, it reaches the lumbar and dorsal spines; below, it meets its fellow in the mesian line.

Relation: Externally, with skin; internally, with abdominal tunic and muscles.

Action: To corrugate skin, bind down other muscles, and assist in difficult expiration.

Inferior Abdominal Region.

The infero-lateral walls of the abdomen are formed by a large musculo-aponeurotic envelope, consisting of four pairs of muscles and the abdominal tunic, the structures on the right being separated from those on the left by the linea alba, a white line extending from sternum to pubis.

The *Abdominal Tunic* is composed of yellow elastic tissue, and covers the external oblique muscles. It is thickest at the pubis, and on each side of the linea alba, thinning as it approaches the sternum, and disappearing at the posterior insertion of pectoralis magnus muscle. It blends with the external oblique, anteriorly, reaching the digitations of serratus magnus; posteriorly, it furnishes fibres detached from the surface of the common tendon (prepubian), is carried between the thighs, and lost in the crural muscles.

Relation: Externally, by cellular tissue to the panniculus and skin. Postero externally, is differentiated into the suspensory ligament of the sheath and scrotum in the male and elastic envelope of the mamma in the female, in whom it is always thickest.

Action: To afford a mechanical support to the abdominal viscera, and conserve muscular action by substituting elasticity for it. On the application of distensile force it yields considerably.

The *Linea alba* is a white fibrous cord situated between the inner borders of the recti-abdominalis, to which it gives attachment, in common with the other abdominal muscles. Anteriorly, it is attached to the inferior surface of ensiform cartilage. Posteriorly, it becomes confounded with a large tendon, common to the abdominal muscles, which passes to the anterior border of the pubis. This prepubian tendon, covered by the abdominal tunic, contributes to the formation of the internal commissure of the inguinal ring, and originates the pubio-femoral ligament. About its posterior third, the line is enlarged, and forms a lozenge-shaped space, in the centre of which is the remains of the umbilicus.

Obliquus Abdominis Externus *vel* Costo Abdominalis.—The largest and most external. Situated on the infero-lateral aspect of the abdomen.

Figure: Quadrilateral, its fibres running obliquely downwards and backwards. Its aponeurosis commences at a white

line, the linea semi-lunaris, and is continued to the linea alba, where it blends with that of the internal oblique.

Origin: By fleshy fibres, supero-anteriorly from the outer surface of the 13 or 14 last ribs, just below their middle. The 4 anterior digitations are received between corresponding ones of the serratus magnus; the remaining 10 digitate with the superficialis costarum. Supero-posteriorly, it is attached to the lumbar fascia.

Insertion: Into crista ilii and anterior spinous process of ilium; infero-posteriorly, to pubis and prepubian ligament; inferiorly, to linea alba throughout its whole extent. The aponeurosis, which stretches from the anterior spine of ilium to pubis answers to the fold of the groin, and bounds the trunk and hind extremity. Posteriorly, it splits into two layers; one descends internally over the thigh, forming the crural aponeurosis; the other is reflected upwards, and enters the abdomen, constituting the Crural Arch or Poupart's ligament. Near the prepubian ligament, and immediately in front of the division of the aponeurosis, it is pierced by a large oval foramen, the external abdominal ring, through which passes the spermatic cord of the male, and the mammary vessels of the female, This opening leads to the inguinal canal.

Relation: Externally, with panniculus and abdominal tunic; antero-externally, with pectoralis magnus; internally with the ribs, cartilage, and intercostals, internal oblique and rectus; anteriorly, with serratus magnus; posteriorly, with serratus and superficialis costarum.

Action: To support abdominal viscera, compress bowels, assist in defecation, urination, and parturition. It is a flexor of the vertebral column, and a muscle of expiration.

The divisions of the posterior aponeurosis of the external oblique is—

1. The *Crural Aponeuroses*, which descends over the fold of the groin to the patella and internal surface of the thigh, blends outwardly with the fascia lata, covering the adductor longus, part

of the brevis, vastus internus, and the crural vessels as they leav
the abdomen.

2. The *Crural Arch, Poupart's Ligament vel Ligament o
Fallopius*, is a ribbon shaped reflected portion of the aponeurosi
of external oblique, and is attached by its extremities to the an
terior spine of the ilium, and anterior border of the pubis. Ante
riorly, it forms the posterior pillar of the inguinal canal, then give
attachment to the posterior fibres of the internal obliqu
Posteriorly, it is applied against the superior extremity of the sa
torius and pectineus muscles, and the crural vessels, embracin
those parts in a sort of arch, hence its name. Its superior borde
at its external half is inserted into the lumbo iliac aponeurosis
Its middle is confounded with the external surface of sartoriu
and iliacus. Within, at the insertion of pectineus and psoa
parvus, it forms a triangular opening with the anterior borde
of pubis and the iliacus and sartorius, called the crural ring
through which pass the crural vessels, to gain the crural arch
and leave abdomen. The inferior border is continuous with th
femoral aponeurosis.

The *Inguinal Canal* is infundibuliform and compressed late
ally; through it pass the spermatic cord of the male and mam
mary vessels of the female. It is placed obliquely in ever
direction between the crural arch, which is its posterior, and th
internal oblique, which forms its anterior, wall. The *inguina
opening* or *external abdominal ring*, larger than the internal, i
oval, running backwards and inwards. It presents two pillar
and two extremities or commissures. The pillars, anterior an
posterior, are formed by the arciform fibres of the aponeuros
of the external oblique. The commissures, external and interna
are constituted—the former by the prepubian tendon, the latte
by the union of the pillars. The *abdominal peritoneal* or *in
ternal abdominal ring*, is situated in front of the crural ring. I
is a mere dilatable cleft between the crural arch and intern
oblique, and but indifferently marked at its extremities.

Obliquus Abdominis Internus *vel* Ilio-abdominalis.—Situ

ated below Externus on the postero-lateral and inferior aspect of the abdomen.

Figure: Broad, thin, fan-shaped fibres diverging downwards and forwards.

Structure: Fleshy and aponeurotic. The fleshy portion is thick, and occupies the flank; the aponeurosis commences at the linea semi-lunaris, its fibres intertwining with those of the external oblique.

Origin: Supero-posteriorly, from the anterior spine of the ilium, whence its fleshy fibres radiate from the transverse processes of the lumbar vertebræ and posterior border of last rib. It is sometimes described as a retractor costæ.

Insertion: Inner surface of cartilage of all the false ribs; postero-inferiorly, to symphysis pubis, through prepubian tendon, aiding in the formation of internal abdominal ring; inferiorly, to linea alba throughout its whole extent.

Relations: Externally, with external oblique; internally, with transversalis and rectus abdominis.

Action: It assists Externus in compressing the abdomen in the act of respiration, and in flexing the body. It also draws the last rib backwards.

Rectus Abdominis *vel* Sterno-pubialis.—Situated on inferior and middle part of abdomen.

Figure: It is long, flat, and polygastric, broadest in the middle. Tendinous at its attachments, its belly consists of numerous flat muscular fasciculi, with transverse tendinous intersections, which are the linea transversalis, to which the united aponeurosis of the oblique muscles are adherent. The posterior part of the muscle enters into the formation of the internal abdominal ring.

Origin and Insertion: Anteriorly to the inferior surface of ensiform cartilage; cartilages of the five or six last true and two first false ribs, and four or five posterior bones of sternum; posteriorly, to the crest of pubis, through the medium of prepubian tendon and pubio-femoral ligament; internally, to linea alba.

Relations: Externally with aponeurosis of obliques; anteriorly,

with pectoralis magnus; internally, with transversalis and th cartilages of nearly all the ribs.

Actions: To support and compress abdominal viscera an assist in respiration, as well as to extend pelvis and flex back.

Transversalis Abdominis *vel* Lumbo-abdominalis.—Situate in infero-lateral aspect of abdomen.

Figure: Broad, flat, and quadrilateral, its fibres extendin obliquely downwards and backwards. It is fleshy from its origin to linea semilunaris, where it becomes aponeurotic.

Origin and Insertion: Posteriorly, from transverse processes o lumbar vertebræ, anterior spine of ilium and crest of pubis, where it aids in the formation of internal abdominal ring; anteriorly, to the inner surface of cartilages of all the false ribs and ensiform cartilage, interdigitating with the diaphragm, and to linea alba throughout its whole extent.

Relations: Anteriorly, with diaphragm; externally, with cartilages of false ribs, obliquus internus, and rectus; internally, it is lined by peritoneum.

Action: To assist the oblique.

Axillary Region.

This region includes four pair of muscles, situated under the sternum, and terminating in the anterior extremity. Percival describes them as three—pectoralis transversus, p. magnus, and p. parvus. Girardé divides the transversus into sterno-humeral or anticus, and sterno-aponeuroticus or transversus.

Pectoralis Anticus *vel* Sterno-humeralis.—Situated on the anterior part of the breast, forming the fleshy prominence seen in front (Pl. VI. fig. 1, *d*, *e*).

Figure: Short thick, and fusiform: fibres extending outwards. Tendinous at its attachments with fleshy belly.

Origin: From cariniform cartilage and first bone of sternum, by fleshy fibres. It passes obliquely backwards and downwards.

Insertion: On a ridge at anterior part of body of humerus at

the insertion of levator humeri, both by fleshy fibres and an aponeurotic tendon common also to levator humeri and transversus.

Relations: Externally, with skin; anteriorly, with levator humeri and panniculus; posteriorly, with pectoralis magnus and transversus; interiorly, with parvus.

Action: To adduct arm.

Pectoralis Transversus *vel* Sterno-aponeuroticus.—Situated on latero-inferior part of thorax (Pl. VI. fig. 1).

Figure: Quadrilateral, the fibres extending outwards and backwards. Internally, fleshy, mixed with tendon; externally, aponeurotic.

Origin: By fleshy fibres from the 4 first bones of sternum, meeting its fellow at a white central line.

Insertion: Into olecranon, the fascia covering the inner side of the arm, and a ridge on the humerus.

Relation: Externally, with skin; anteriorly, with pectoralis anticus; internally, with pectoralis magnus.

Action: To adduct the arm, and tense the brachial fascia.

Pectoralis Magnus *vel* Sterno-trochineous.—Situated on infero-lateral part of thorax (Pl. IV. fig. 1).

Figure: Irregularly four-sided, flat, and thick, the fibres extending downwards and outwards. Externally, aponeurotic; anteriorly, fleshy.

Origin: From inferior border of 4th, 5th, and 6th bones of sternum, ensiform cartilage, and its fellow on opposite side; externally to the cartilage of first false rib, aponeurosis of external oblique, and abdominal tunic.

Insertion: Fascia on inside of arm and inner tubercle of humerus, under the tendon of coraco-humeralis, and by fascia to external part of bicipital groove.

Relations: Externally, with panniculus, skin, and pectoralis transversus; internally, with aponeuroses of external oblique, serratus magnus, and ribs; anteriorly, with parvus.

Action: To draw shoulder back and adduct arm; in difficult respiration, it acts as an inspiratory muscle.

Pectoralis Parvus *vel* Sterno-pre-scapularis.—Situated front of magnus, on infero-lateral part of thorax (Pl. VI. fig. *f, f, g*).

Figure: Elongated and prismatic fibres extending from o wards and upwards, tendinous at its origin, aponeurotic at ins tion.

Origin: Internally from the 4 first bones of sternum, cari form, and cartilages of first 3 or 4 true ribs.

Insertion: Fascia in front of shoulder-joint and anterior cos of scapula, nearly as high up as origin of antea spinatus.

Relation: Supero-externally, with magnus; inferiorly, wi transversus and anticus; internally, with cartilage of ri anteriorly, with levator humeri.

Action: To draw the shoulder-joint backwards and dow wards, adduct arms, and assist magnus.

Inferior Cervical Region

Includes 9 muscles—levator humeri, sterno-maxillaris, stern thyro-hyoideus, subscapulo-hyoideus, rectus capitis antic major and minor, obliquus capitis anticus, scalenus, and long colli.

Levator Humeri *vel* Mastoido-humeralis.—Situated on i fero-lateral part of the neck.

Figure: Flat and elongated, the fibres extending downwar and backwards. Its fleshy belly is divisible into deep and supe ficial, each with aponeurotic tendons at either end.

Origin: Anteriorly, by one tendon from crest of occiput an mastoid process of temporal; by the other, from wing of atlas, t tendon being common to splenius and trachelo-mastoideus, fro transverse processes of 2d, 3d, and 4th cervical vertebræ, fasc of neck, ligamentum nuchæ, and by a tendinous expansion co founded with that of cervical trapezius.

Insertion: Posteriorly, loosely to head of humerus; also to ridge extending downwards from external tubercle to fascia

Plate V MUSCLES OF HEAD & FORELEG

PLATE V.

MUSCLES OF HEAD AND FORE-LEG.

Fig. 1.—Muscles of Fore-limb.

a. Omo-hyoid. *b*. Sterno-maxillary. *c*. Deltoid and Cleido-mastoid. *d d'*. Trapezius. *d*. Its cervical portion. *d'*. Its dorsal portion. *e*. Latissimus dorsi.

Fig. 2.—Muscles of Head.

a. Depressor auris. *b*. Adductor auris inferior. *c*. Adductor auris medius. *d*. Adductor auris superior. *e*. Corrugator supercilii. *f*. Orbicularis palpebrarum. *g*. Levator labii superioris. *h*. Depressor labii inferioris. *i*. Buccinator. *k*. Masseter. *l*. Pyramidalis nasi. *m*. Dilatator nasi inferioris. *n*. Dilatator nasi superioris.

Fig. 3.—Muscles of Fore-limb.

a. Sterno-hyoid. *b*. Sterno-thyroid. *c*. Splenius. *d*. Scalenus. *e*. Rectus capitis anticus major. *f*. Cervical portion of Serratus magnus. *g*. Its costal portion. *h*. Levator anguli scapulæ. *i*. Rhomboid. *k*. Upper end of Pectoralis minor.

houlder and arm, and by cellular tissue to the shoulder joint
uscles.

Relation: Externally, with panniculus; inferiorly, with carotid
rtery, jugular vein, and sterno-maxillaris; supero-posterior with
plenius; internally, with trachelo-mastoideus, rectus capitis
nticus major, and scalenus; anteriorly, with parotid gland.

Action: When the head is fixed, it elevates the humerus; if
ne legs are fixed, they assist in flexing or depressing the head;
ngly, it aids in turning head and neck to one side.

Sterno-maxillaris.—Situated on inferior part of the neck,
long lower border of preceding (Pl. V. fig. 1, *b*).

Figure: Long, narrow, and flat, its fibres extending forwards
nd upwards; it is fleshy, terminating in a flat tendon.

Origin: Infero-posteriorly, from anterior portion of cariniform
artilage, where it becomes united to its fellow.

Insertion: Anteriorly, into angle of lower jaw.

Relation: Externally, with panniculus and levator humeri; in-
ernally, with sterno-thyro-hyoideus, subscapulo-hyoideus, trachea,
nd carotid artery, the jugular vein running along its superior
order; anteriorly, with parotid and sub-maxillary glands.

Action: Acting together, to depress head and open mouth;
ngly, to turn head to one side.

Sterno-thyro-hyoideus.—Situated on inferior part of the
eck (Pl. V. fig 3, *a*, *b*).

Figure: Narrow, ribbon-shaped, dividing into two parts.
nteriorly, its fibres extend forwards and upwards. Fleshy at
origin, it terminates half way up the neck in two portions,
ch having a tendon of insertion. About their middle, at
fferent points, the sterno-thyro-hyoidei have tendinous inter-
ctions, which render them digastric.

Origin: Inferiorly, from superior part of cariniform cartilage,
imately blending with its fellow.

Insertion: By one tendon, to postero-inferior part of thyroid
tilage, and by the other to the spur process of the body of os
oides.

Relation: Inferiorly, with sterno maxillaris; superiorly, wi trachea; on the left side, with œsophagus.

Action: To draw backwards and downwards the hyoid bon and with it the larynx and base of tongue.

Subscapulo hyoideus.—Situated on antero-lateral parts neck.

Figure: Broad, thin and elongated, its fibres extending o liquely forwards and upwards. Aponeurotic at its origin, it followed by a long, flat, fleshy belly, ending in a flat tendo which joins the sterno-hyoideus.

Origin: From the fascia covering subscapularis.

Insertion: Inferior border of spur process of os hyoideus.

Relation: Externally, with sterno maxillaris; internally, wit sterno-thyro hyoideus, blending throughout with levator humer posteriorly, with muscles on inner aspect of shoulder and sc lenus, being related to carotid sheath.

Action: It retracts and depresses hyoid bone and larynx, flex ing the head.

Rectus Capitis Anticus Major *vel* Trachelo-suboccipitali —The long flexor of the head. Situated on antero-lateral part neck (Pl. V. fig. 3, *e*).

Figure: Semi-penniform, fibres passing backwards and fo wards; it has a flattened, fleshy body, diverging from 2 or slips of origin, terminating anteriorly in a flat tendon.

Origin: Posteriorly, from transverse processes and bodies of 3, 4, 5, and sometimes 6, cervical vertebræ.

Insertion: Basilar process of occiput and body of sphenoid.

Relation: Superiorly, with smaller straight muscle and guttur pouch; internally, with longus colli; inferiorly, with œsophagu on left, and trachea and larynx on right side, and carotid sheath

Action: To flex head; when acting singly, to rotate it to on side.

Rectus Capitis Anticus Minor *vel* Atloido suboccipitali —Short flexor of head. Situated on inner side of precedin (Pl. VI. fig. 1, *c*).

Figure: Short, slender, and somewhat cylindrical. It is fleshy, with short flat tendons.

Origin: Posteriorly, from lower part of body and ring of atlas, between insertions of longus colli and obliquus capitis anticus.

Insertion: Into the basilar process of occiput, outside of preceding.

Relation: Infero-externally, with the major; superiorly, with the capsular ligament of occipito-atloidean articulation.

Action: To assist in depressing the head.

Obliquus Capitis Anticus *vel* Atloido-styloideus.—Little flexor of head. Situated at the back of fauces.

Figure: Somewhat prismatic; fleshy from its origin to termination.

Origin: From inferior part of the ring of atlas on the outer side of rectus minor.

Insertion: Styloid process of occiput.

Relation: Inferiorly, with rectus major; superiorly, with capsular ligament of the occipito-atloidean articulation; externally with the parotid gland.

Action: To rotate and flex head.

Scalenus *vel* Costo-cervicalis.—Situated at postero-inferior part of neck, at the side of anterior aperture of thoracic cavity (Pl. V. fig. 3, *d*).

Figure: Short and flat, divided into a superior-posterior and an inferior-anterior portion. Its fibres run forwards and upwards, consisting of 2 or 3 fleshy masses, with strong tendinous intersections, terminating in fleshy and tendinous extremities. The anterior portion is the larger, flat from side to side, and thin in front.

Origin of Anterior portion: From transverse processes of the last cervical vertebræ by short fleshy fasciculi.

Insertion: Anterior and outer border of first rib.

Origin of Posterior portion: From the transverse processes of the 4 last cervical vertebræ.

Insertion: First rib about its upper third.

Relation: Superiorly, with transversalis colli; inferiorly, wit the sterno maxillaris; externally, with levator humeri, pectoral parvus, and subscapulo hyoideus; internally, with trachea an carotid, and on left side with œsophagus. Along its inferio border runs the jugular vein, and between its anterior an posterior portions pass the brachial plexus.

Action: When the first rib is fixed, they flex the neck singly each turns it to one side. When the neck is fixed by drawin the first rib forwards, it acts as an inspiratory muscle.

Longus Colli or Sub-dorso-atloideus.—Situated along in ferior and anterior part of neck (Pl. VI. fig. 1, *a*).

Figure: Cylindrical, the fibres running obliquely into eac other. The dorsal portion is fleshy, the cervical made up o fleshy fasciculi, convoluted and intersected by tendinous fibres.

Origin: Posterior, from inferior surface of the bodies of th first 6 dorsal vertebræ; inferior spines and transverse processe of 6 posterior cervical.

Insertion: By a strong tendon into the inferior spine o tubercle of atlas.

Relation: Externally and anteriorly, with rectus capitis ant cus major; externally and posteriorly, with scalenus; inferiorly with trachea, œsophagus, blood-vessels, and nerves; superiorly with vertebræ. The dorsal portion is related with pleura an sympathetic nerves.

Action: To flex, curve, or straighten the neck, and to mov one vertebra on another.

Superior Cervical Region.

The next muscles are situated in the triangular space forme by the transverse processes of cervical vertebræ, spinous proce of second dorsal, and funicular portion of ligamentum nuchæ they are arranged in four layers in the superior cervical region, viz trapezium cervicalis, and cervical attachment of levator humer rhomboideus longus, splenius, complexus major, complexus mino

trachelo-mastoideus, rectus capitis posticus major, rectus capitis posticus minor, obliquus capitis inferior and superior, spinalis colli, transversalis colli, and a portion of the serratus magnus.

Cervical Trapezius *vel* Cervico-acromialis.—Situated on the side of neck (Pl. V. fig. 1, *d*).

Figure: Thin, flat, and triangular, fibres converging downwards and backwards. Aponeurotic, with pale central muscular fibres.

Origin: From the funicular portion of ligamentum nuchæ, by a tendon common to it, and levator humeri, and panniculus.

Insertion: With dorsal trapezius into the spine of scapula at its tubercle.

Relation: Externally, with levator humeri and panniculus; internally, with splenius, serratus magnus, rhomboideus longus, pectoralis parvus, and antea-spinatus.

Action: To elevate and draw the shoulder forwards.

Rhomboideus Longus *vel* Cervico-subscapularis.—Situated on supero-lateral parts of neck, just below the cordiform portion of ligamentum nuchæ (Pl. V. fig. 3, *i*).

Figure: A tapering triangle, widest posteriorly. It is fleshy, with tendinous extremities.

Origin: From funicular portion of ligamentum nuchæ, as high up as second vertebra.

Insertion: Inner surface of supero-anterior angle of scapula, and to its cartilage of prolongation, just above serratus magnus.

Relation: Externally, with cervical trapezius; inferiorly, with splenius; posteriorly, with rhomboideus brevis, with which it blends; internally, with ligamentum nuchæ, dorsal, and superior cervical blood-vessels.

Action: To elevate and draw scapula forwards.

Splenius Cervico-Trachelius *vel* Mastoideus.—Situated on the side of neck (Pl. V. fig. 3, *c*).

Figure: Broad, flat, and irregular, four-sided. Structure aponeurotic at its periphery; its belly is made up of large fleshy bundles, which are directed obliquely forwards and upwards to the head and first cervical vertebra.

Origin: From the funicular portion of ligamentum nuchæ, th tubercle of occiput in union with tendon of trachelo-mastoi and mastoid process of temporal.

Insertion: Wing of atlas, along with second tendon of trachel mastoid and levator humeri, transverse processes of the first an last cervical vertebræ, but spinous processes of dorsal vertebra from second to fifth.

Relation: Externally, with levator humeri and cervical tra pezius; superiorly, with rhomboid muscles; posteriorly, wit serratus magnus; internally, with complexus, trachelo-mastoid obliquus capitis inferior, transversalis colli, and ligamentum nuchæ.

Action: When acting together, to elevate head; when singly to draw head to one side.

Complexus Major Dorso-occipitalis.—Situated below spl nius, on supero-lateral parts of neck.

Figure: An elongated triangle, with the base backwards Structure fleshy, with tendinous intersections. It may be divide into posterior and anterior. The former is the larger, and apo neurotic at its origin, the anterior, fleshy and tendinous, term nating in a single tendon.

Origin: Its posterior division comes from transverse an spinous processes of the first 5 dorsal vertebræ; its anteric division arises from the oblique processes of all the true cervic vertebræ, and spinous process of axis.

Insertion: By a united tendon into the occipital tuberosity.

Relation: Externally, with splenius and trachelo-mastoid; i ternally, with complexus minor, ligamentum nuchæ, and obliqu muscles; posteriorly, with longissimus and spinalis dorsi. Th superior cervical artery passes through its divisions posteriorly.

Action: To elevate the head; singly, to draw it to one side.

Complexus Minor *vel* Axoido-occipitalis Longus.—Situate on the poll.

Figure: Fusiform, long and slender, fleshy, and tendinous a insertion.

Origin: From ligamentum nuchæ at spinous process of dentata.

Insertion: Along with tendon of complexus major into occipital crest.

Relation: Externally, with complexus major; internally, with rectus capitis posticus major, and ligamentum nuchæ.

Action: To assist the complexus major.

Trachelo-mastoideus *vel* Dorso-mastoideus.—Situated on lateral side of neck, along the inferior border of splenius.

Figure: Elongated and bifid, its fibres passing obliquely forwards and upwards, tendinous at its origin; posteriorly, the belly is divided into two portions, which run parallel, each terminating by a tendon anteriorly.

Origin: From the transverse processes of the 2 first dorsal and oblique processes of last 5 cervical vertebræ.

Insertion: By 2 tendons; one to wing of atlas receiving slips from splenius and levator humeri; the other, common to it and splenius, into mastoid process of temporal bone.

Relation: Externally, with splenius; internally, with spinalis colli; posteriorly, with longissimus and spinalis dorsi.

Action: To erect the head; when singly, to draw it on one side.

Rectus Capitis Posticus Major *vel* Axoido-occipitalis Brevis.—Situated on poll below complexus minor (Pl. V. fig. 3, *e*).

Figure: Long, slender, and fusiform, and fleshy, with tendinous extremities.

Origin: From superior spinous process of dentata.

Insertion: Into a roughened depression on occiput below its tubercle.

Relation: Externally, with complexus minor; internally, with rectus capitis posticus minor, having the obliquus capitis superioris on its outer side.

Action: To extend head and protrude the nose.

Rectus Capitis Posticus Minor *vel* Atloido-occipitalis.—Situated below preceding (Pl. VI. fig. 1, *c*).

Figure: Small, flat, and somewhat triangular, same as major

Origin: Posteriorly, from superior spine of atlas.

Insertion: Into the roughened depression on the posterior surface of occiput.

Relation: Superiorly, with major; inferiorly, with capsular ligament; externally, with obliquus capitis superioris; internally with its fellow and ligamentum nuchæ.

Action: To straighten head on atlas.

Obliquus Capitis Inferioris *vel* Posticus, or Axoido-atloideus.—Situated on the supero-antero-lateral part of neck.

Figure: Broad, flat, four-sided, thick and fleshy fibres, extending obliquely forwards and upwards.

Origin: From the side and superior spine of dentata and capsular ligament.

Insertion: Into wing and body of atlas.

Relation: Externally, with tendon of splenius; internally with complexus minor and ligamentum nuchæ; superiorly, with complexus major.

Action: To elevate the head; singly, to rotate it.

Obliquus Capitis Superioris *vel* Anticus, or Atloido-mastoideus.—Situated on the side of the poll.

Figure: Flat, nearly square, fleshy, with tendinous intersections

Origin: From the supero-anterior portion of roughened edg of wing and lower border of atlas.

Insertion: Mastoid crest and styloid process of occiput.

Relation: Externally, with tendon of splenius; internally with capsular ligament, rectus major, and ligamentum nuchæ.

Action: To draw the head back; singly, to bend it laterall on the atlas.

Spinalis Colli *vel* Dorso-spinalis.—Situated, deep-seated, o side of neck.

Figure: It consists of 5 short fleshy bundles, intersected b tendons, whose fibres extend obliquely upwards and inwards.

Origin: Posteriorly, from oblique process of first dorsal an all the true cervical.

Insertion: The posterior borders of all the cervical vertebræ but first.

Relation: Externally, with complexus major and trachelo-mastoid; internally, with ligamentum nuchæ and vertebræ.

Action: To extend and curve neck and erect head.

Inter-transversalis Colli *vel* Inter-cervicalis.—Situated along lateral part of cervical vertebræ.

Figure: It consists of 4 distinct bundles, with strong tendinous intersections, the fibres passing obliquely outwards and upwards.

Origin: Oblique process of one vertebra.

Insertion: Transverse process of the one in front, filling up the interspaces of all excepting first and second.

Relation: With several deep-seated muscles of neck, vertebræ, vertebral artery, and vein.

Action: To assist in turning one vertebra on another and flexing the neck.

Dorsal Scapular Region

includes costal, sternal, and dorsal trapezius, latissimus dorsi, and rhomboideus brevis.

Dorsal Trapezius *vel* Dorso-acromialis.—Situated on the side of withers (Pl. V. fig. 1, *d*, *d'*).

Figure: Flat and triangular, base uppermost; aponeurotic at its superior border; its belly is fleshy, terminating in a flat tendon.

Origin: Superiorly, from spine and supra-spinous ligament, from 3d dorsal spine as far as 10th or 11th; the fibres converge lownwards and forwards, over superior costa of scapula, and oin cervical portion.

Insertion: Tubercle on spine of scapula.

Relation: Externally, with skin and panniculus; superiorly, vith rhomboidei; internally, with levator humeri and postea-pinatus; and posteriorly, with latissimus dorsi.

Action: To draw upwards and abduct shoulder-joint.

Latissimus Dorsi *vel* Dorso-humeralis.—Situated on supero-lateral parts of chest and loins (Pl. V. fig. 1, *e*).

Figure: Very large, flat, thick, and triangular, its fibres extending obliquely downwards and forwards; aponeurotic above, with fleshy belly, and a tendinous and aponeurotic insertion.

Origin: By a broad aponeurosis, from the supra-spinous ligament and spinous processes of the dorsal vertebræ, commencing at the highest point of the withers, and stretching as far as the last lumbar; the belly given off from the inferior border of aponeurosis becomes very fleshy just behind the scapula, where it contracts, terminating in a flat tendon which passes under it.

Insertion: The internal tuberosity of humerus, along with teres internus, between the two insertions of coraco-humeralis; before gliding under the scapula, it gives off a strong aponeurosis, which passes over the supero posterior part of scapula, and is inserted into the fascia, covering it.

Relation: Externally, with panniculus carnosus, skin, and dorsal trapezius; superiorly, with rhomboideus brevis and superior angle of scapula; inferiorly, with triceps; externally, with brachialis; internally, with scapula, and ulnaris teres internus; postero-internally, with serratus magnus and ribs.

Action: To elevate humerus, and thus flex shoulder-joint; it is likewise a respiratory muscle.

Rhomboideus Brevis *vel* Dorso-subscapularis.—Situated on side of withers below scapula (Pl. V. fig. 3, *i*).

Figure: Flat and square; the fibres extend forwards, and are entirely fleshy.

Origin: From superior spines, from 1st to 6th of dorsal vertebræ, and from their superior spinous ligament.

Insertion: Inferiorly, to the inner surface of the superior costa of scapula and its cartilage of prolongation.

Relation: Externally, with cartilage of scapula, and the dorsal trapezius, separated from anterior portion of the superficialis costarum by a layer of yellow elastic tissue; anteriorly, with

homboideus longus; posteriorly, with serratus magnus and atissimus dorsi; internally, with ribs and their intercostals.

Action: To draw scapula upwards, elevate and adduct shoulders.

Costal Region.

Serratus magnus, superficialis, transversalis, and levatores costarum and intercostals.

Serratus magnus *vel* Trachelo or Costo-subscapularis.—Situated between the shoulders and chest (Pl. V. fig. 3, *f*, *g*).

Figure: Large and fan-shaped; it contains many tendinous intersections, converging to the point of insertion.

Origin: Anteriorly, from transverse processes of 4 or 5 posterior cervical vertebræ; postero-inferiorly, from external surfaces of 8 anterior true ribs below their middles and some of their cartilages.

Insertion: Superiorly, to upper venter surface of scapula, between origin of subscapularis and insertion of rhomboid; also upper angle and cartilage.

Relation: Anteriorly, with splenius and levator humeri; superiorly, with the rhomboidei; supero-posteriorly, with longissimus dorsi; posteriorly, with external oblique and abdominal fascia; inferiorly, with the pectorals; internally, with longissimus dorsi, cervical vertebræ, and intercostals; externally, with scapular and inner shoulder muscles.

Action: To support fore-limb, to approach scapula to ribs, and elevate neck; it is also an extraordinary muscle of inspiration.

Superficialis Costarum *vel* Dorso-costalis.—Situated on supra lateral part of back and chest.

Figure: Broad and thin, fleshy, and aponeurotic.

Origin: Superiorly, from supra-spinous ligament, from 5th dorsal to 2d lumbar vertebræ.

Insertion: Inferiorly, to all the ribs behind 4th, just below their angles, their anterior border up to 13th, thence to the posterior border.

Relation: Internally, with ribs and transversalis costarum anteriorly, with serratus magnus; inferiorly, interdigitating wit external oblique; superiorly, with longissimus dorsi; externally with panniculus.

Action: Respiratory,—the anterior portion drawing the rib up, out, and forwards, acts as an inspiratory; the posterior, b drawing them backwards and upwards, as an expiratory muscle

Transversalis Costarum *vel* Cervico-costalis.—Situated o supero-lateral parts of thorax.

Figure: Long, thin, and semi-penniform. It consists of tw sets of fibres, the outer passing up and backwards, the inne down and forwards, its numerous muscular bundles each ter minate in a flat tendon.

Origin: The outer set comes from the transverse process of th last cervical vertebra, passing over the first three ribs.

Insertion: Anterior border of the remaining ribs.

Origin: The inner set from the transverse process of first lum bar vertebra, passing over two last ribs.

Insertion: Into posterior border of all the other ribs.

Relation: Externally, with preceding muscle; internally, wit ribs; superiorly, with longissimus dorsi.

Action: Complex. Both sets of fibres compress the ribs, assis ing in expiration. The outer is an inspiratory, the inner a expiratory muscle.

Levatores Costarum.—Situated deep in the back.

Figure: Flat and triangular, extending obliquely downward It is fleshy, with tendinous intersections.

Origin: Superiorly, from the transverse processes of 16 anteric dorsal vertebræ, just above the tubercles of the ribs.

Insertion: Inferiorly, into anterior border of the ribs, just abov their angles.

Relation: Externally, with longissimus dorsi; internally, wit ribs.

Action: To elevate ribs upwards and forwards, thus acting a inspiratory muscles.

Intercostals.—These fill up the spaces between the ribs, are external and internal, and usually 17 in number.

Figure: Flat, muscular fibres, included in and intersected by broad aponeurotic tendinous slips. The external ones are thickest.

Origin of the External Intercostals: From the posterior border of one rib.

Insertion: The anterior border of the next rib, their fibres extending obliquely from down and backwards.

Origin of the Internal Intercostals: From the anterior border of one rib.

Insertion: Posterior border of rib in front, their fibres extending from obliquely up and backwards. The external only reach the cartilages. The internal do not pass the angles, either remaining space being filled up by the opposite muscle.

Relation: Externally, with serratus magnus, superficialis and transversalis costarum, and latissimus dorsi; internally, with pleura.

Action: The external ones, expiratory; the internal, inspiratory.

Sternal Region.

Lateralis Sterni *vel* Costo-Sternalis.—Situated on antero-inferior part of chest.

Figure: Long, flat, and thin fibres extending down and backwards. It is tendinous, fleshy, and aponeurotic.

Origin: From lower third of first rib, passing over second, closely from cartilage of third, and by aponeurosis from fourth and fifth ribs, and from sternum, its aponeurosis blending with that of rectus abdominis.

Relation: Externally and inferiorly, with pectorals; superiorly, with serratus magnus; posteriorly, with rectus abdominis; internally, with ribs and intercostals.

Action: A muscle of inspiration, drawing the 4 first ribs forwards and upwards.

Sterno-costales, Externi and Interni.—Situated betwee ribs and sternum.

Figure: Triangular and very tendinous.

Origin of the External: From sternum. Six in number.

Insertion: Cartilage and inferior extremities of true ribs.

Origin of the Internal: From floor of sternum. Also six i number.

Insertion: Cartilages, and inner surfaces of inferior end true ribs.

Action: To assist in respiration.

Dorsal Region.

Longissimus dorsi, spinalis dorsi, semi-spinalis dorsi, and inter transversales lumborum.

Longissimus Dorsi *vel* Ilio-spinalis.—Situated on the superi lateral part of back and loins, between costal arches and dorso lumbar spines.

Figure: Extends backwards in nearly a straight line, being th longest and largest muscle in the body; fleshy at its origin, i becomes thicker and narrower as it proceeds forwards; at th sixth dorsal vertebra, it contracts and proceeds in an obliqu direction to the neck below spinalis dorsi, terminating by severa tendons. Its belly is intersected by several tendons, and i invested by a strong aponeurosis.

Origin: Posteriorly, from crest, inner surface, and superi anterior spine of ilium, spinous and transverse processes of fir 2 bones of sacrum, spinous, transverse, and oblique processes o all the lumbar vertebræ, spinous processes of last 12, and tran verse processes of all, dorsal vertebræ, and at the angles of th 12 posterior ribs just above transversalis costarum.

Insertion: Transverse processes of the last 3 or 4 cervic vertebræ.

Relation: Externally, with superficialis costarum; inferiorly with transversalis costarum; internally, with ribs and vertebra semi-spinalis dorsi lumborum; anteriorly, with spinalis dorsi.

Action: To assist in elevating ribs and neck. It is brought powerfully into play in kicking and rearing.

Spinalis Dorsi.—Situated deeply on the withers.

Figure: Pyramidal, the fibres running forwards. Aponeurotic at its origin, it is with difficulty separated from longissimus dorsi; belly fleshy, with tendinous intersections.

Origin: Posteriorly, by aponeurosis from all the dorsal vertebræ, from supero-spinous ligament, as far back as eleventh, and from spinous processes of 6 anterior dorsal vertebræ.

Insertion: Into the superior spinous and oblique processes of last three or four cervical vertebræ.

Relation: Externally, with trapezius; anteriorly, with complexus major and splenius; inferiorly, with longissimus dorsi; internally, with ligamentum nuchæ.

Action: To elevate head and neck; singly, to draw head to the side.

Semi-spinalis Dorsi *et* Lumborum.—Situated deeply on the back.

Figure: Semi-penniform, fleshy, extending upwards and forwards, with tendinous intersections, which thicken anteriorly, forming a chain of muscles continuous with the spinalis colli.

Origin: Posteriorly, from first bone of sacrum, oblique processes of all lumbar, and transverse processes of all, dorsal vertebræ.

Insertion: Into spinous processes of the next anterior vertebra, becoming continuous with spinalis colli at seventh cervical.

Relation: Externally, with longissimus and spinalis dorsi; internally, with vertebræ.

Action: To assist in moving the spine.

Inter-transversales Lumborum.—These are small muscular slips invested by strong tendinous fasciæ running from the transverse process of one lumbar vertebra to the one adjacent.

Relation: With longissimus dorsi and inter-transverse ligaments.

Action: To assist in turning, by bringing these processes nearer to each other.

Sub-lumbar Region.

Psoas, magnus and parvus, iliacus, and sacro-lumbalis. Th sub-lumbar muscles are covered by the iliac fascia, which attached internally to the tendon of the psoas parvus; exte nally, to the anterior angle and external border of ilium posteriorly, this fascia is very thin, and accompanies psoa magnus and iliacus to their insertions. To its outer surface inserted the crural arch, or Poupart's ligament. Internally, the are related to peritoneum.

Psoas Magnus *vel* Sub lumbo-trochantericus.—Situated o postero-inferior part of spine, below the transverse processes lumbar vertebræ (Pl. VII. fig. 2, *c*).

Figure: Elongated and fusiform, fibres extending downward and backwards; almost entirely fleshy, except at its insertion.

Origin: From head and inner surfaces of three last ribs bodies and transverse processes of three last dorsal, and all th lumbar vertebræ, passing through the bifurcations of iliacus.

Insertion: By a tendon, common to it and the iliacus, into th internal trochanter of femur.

Relation: Anteriorly, with diaphragm; posteriorly, with iliacus internally, with psoas parvus and bodies of vertebræ. Above, i the sacro-lumbalis; and below, the kidney.

Action: To draw the spine on to pelvis, or *vice versa;* t flex and rotate hip joint and thigh.

Psoas Parvus *vel* Sub-lumbo-pubialis.—Situated in the sub lumbar region to inner side of former (Pl. VII. fig. 2, *b*).

Figure: Long, thin, and semi-penniform, the fibres extendin backwards. Fleshy above, with a strong tendon passing alon lower surface to its insertion.

Origin: From neck of three last ribs, transverse processes and bodies of last three or four dorsal, all lumbar vertebra and first bone of sacrum.

Insertion: To ilio-pectineal eminence on brim of pelvis midwa between symphysis and acetabulum, and to iliac aponeurosis.

PLATE VII.

MUSCLES OF TRUNK AND HIND LEG.

Fig. 1.—Abdominal Cavity opened with the Diaphragm and Muscles on the inner side of the Thigh.

a. Diaphragm. *a a*. Its tendinous portion. *a' a' a'*. Its fleshy portion. *a'' a''*. Right and left pillar. *a'''*. Aortic opening. *a''''*. Œsophageal opening. *a'''''*. Opening for vena cava. *b*. Sartorius. *c*. Gracilis.

Fig. 2.—Muscles of Back and Posterior Limb, seen from the inner side.

a a. Quadratus lumborum. *b*. Psoas parvus. *c*. Psoas magnus. *d*. Iliacus internus. *e*. Flexor femoris medius. *f*. Adductor longus. *g*. Adductor brevis. *h*. Adductor magnus. *i*. Semi-membranosus. *k*. Vastus Internus. *l*. Rectus femoris.

Relation: Anteriorly, with diaphragm; inferiorly, with posrior aorta and vena cava; externally, with psoas magnus; steriorly, with iliacus.

Action: To draw pelvis forwards on spine when the loins are xed; when pelvis is fixed, to give lateral motion to loins.

Iliacus *vel* Iliaco-trochantericus.—Situated in the iliac ssa, extending along the internal parts of the thigh (Pl. VII. g. 2, *d*).

Figure: Strong, thick, pyramidal, base looking forwards; ores extending downwards and backwards. Its tendon joins at of psoas magnus. The belly is incompletely divided by a ssure into two unequal portions, the external being the larger. hrough this passes the tendon of psoas magnus.

Origin: From anterior spinous process of ilio-pectineal ridge nd venter surface of ilium below the sacrum, and by fleshy ores to sacro-iliac ligament.

Insertion: Into the internal trochanter of femur, along with soas magnus.

Relation: Superiorly, with ilium; inferiorly, with the iliac scia; anteriorly, with psoas magnus and sartorius; externally, ith tensor vaginæ and rectus femoris, from which it is separated r a bed of fat; internally, are the crural vessels. It runs tween vastus internus and pectineus.

Action: To draw femur forwards, flex the haunch, and rotate igh outwards.

Sacro-lumbalis *vel* Costalis.—Situated on the inner surface loins, below psoas.

Figure: Flat and thin, consisting of several bundles, with ong flat tendinous intersections.

Origin: Posteriorly, from body or angle of sacrum, below cro-iliac ligament, passing directly forwards.

Insertion: Into posterior border of last rib and transverse ocess of last dorsal vertebra, becoming attached in its course the free extremity of transverse processes of the lumbar verræ. The other bundles leave the internal border of the first,

are directed obliquely forwards, and are attached to most of t
transverse processes of the lumbar and inner surfaces of the t
or three last ribs.

Relation: Superiorly, with vertebræ and inter-transversa
lumborum; internally, with psoas magnus.

Action: To assist in turning the vertebræ and draw last r
backwards.

Internal Femoral Region.

Sartorius *vel* Subilumbo-tibialis.—Situated at the anter
internal part of haunch, extending into pelvis (Pl. VII. fig. 1, *b*

Figure: Long, thin, pyramidal, its fibres extending oblique
down and outwards.

Origin: From brim of pelvis, transverse processes of la
lumbar vertebræ in connection with psoas parvus, and from ili
fascia.

Insertion: Into inner surface of superior extremity of tibi
along with gracilis, and by fascia to internal straight ligament
patella.

Relation: Anteriorly, with crural arch, iliac fascia, pso
magnus, and iliacus; posteriorly, with gracilis, pectineus, ad
vastus internus; externally, with skin.

Action: To adduct and flex femur, and to rotate ligament.

Gracilis *vel* Subpubio-tibialis.—Situated at internal part
thigh (Pl. VII. fig. 1, *c*).

Figure: Broad, thin, quadrilateral, directed obliquely dow
wards and outwards. It is tendinous, with a flat fleshy bell
terminating in a broad aponeurosis.

Origin: From inferior surface of the pubio-ischiatic syn
physis, where it is confounded with its fellow, and pubi
femoral ligament.

Insertion: With sartorius, into internal straight ligament
patella and supero-internal part of tibia; posteriorly, it blen
with fascia of biceps rotator tibialis, the two forming the intern
fascia of the thigh.

Relation: Anteriorly, with sartorius and pectineus; internally, ·ith adductor muscles of the thigh; posteriorly, with biceps ıtator tibialis; externally, with skin.

Action: To adduct the limb, flex the stifle joint, and tense ıe fascia of the leg.

Pectineus *vel* Supero-pubio-femoralis.—Situated on inner nd supra-anterior part of haunch.

Figure: Conical, the fibres extending outwards and back-ards. It is tendinous, and bifurcated for pubio-femoral liga-ıent, with a fleshy belly.

Origin: From brim and inferior surface of pubis, near the ·mphysis, and is also attached to pubio-femoral ligament, which asses through its tendons of origin.

Insertion: Into a roughened surface on the inner side of ıe femur, below internal trochanter, and near nutrient fora-ıen.

Relation: Anteriorly, with sartorius, insertion of psoas mag-us, iliacus, and vastus internus; posteriorly, with adductor revis and gracilis; superiorly, with obturator externus.

Action: To adduct and flex the thigh by bending the femur ıwardly on pelvis, and to rotate it inwards.

Triceps Adductores Femoris (Pl. VII. fig. 2, *f*, *g*, *h*).—A ng, muscular mass of muscles, situated on the inner surface f the thigh immediately below gracilis, which act the part of lductors. These may be described as a triceps, or as two muscles -brevis and magnus, regarding the latter as a biceps; or as ree—brevis, magnus, and longus, which is preferable.

Adductor Brevis.—Situated on inner aspect of thigh, behind ·ctineus (Pl. VII. fig. 2, *g*).

Figure: Pyramidal, base upwards, fibres converging down-ards. Fleshy, with tendinous insertions.

Origin: Superiorly, from inferior surface of pubis.

Insertion: A square roughened surface on the posterior part upper third of femur.

Relation: Anteriorly, with pectineus and sartorius; externally.

with gracilis; posteriorly, with longus; internally, with obtur
tor externus.

Action: To flex and adduct the limb, draw the stifle inward
hock outwards, and thus rotate the limb.

Adductor Longus.—Situated on inner aspect of thigh, covere
by gracilis (Pl. VII. fig. 2, *f*).

Figure: Long, flat, and triangular, fibres extending outward

Origin: From the inferior surface of posterior part of pubis.

Insertion: By two divisions—one behind the insertion
brevis, the other to internal condyle of femur, along with th
magnus.

Relation: Anteriorly, with brevis; posteriorly, with magnus
externally, with gracilis; internally, with ischio-femoralis an
obturator externus.

Action: To adduct and flex the limb, and rotate the stifle.

Adductor Magnus *et* Semi-membranosus.—Situated behin
preceding, on posterior internal part of thigh (Pl. VII. fig. 2
h, *c*).

Figure: Triangular, flat, thick; anterior thin, posterior broa
and fleshy, terminating in a flat tendon.

Origin: From inferior surface and tuberosity of ischium b
tendinous fibres, two last bones of sacrum, and first bone
coccyx.

Insertion: Inferiorly, into a small roughened eminence o
inner side of internal condyle of femur, and to inner and upp
part of the head of tibia.

Relation: Anteriorly, with longus; externally, with gracilis
posteriorly, with biceps rotator tibialis, and triceps adducto
femoris; internally, with gastrocnemius externus.

Action: To adduct the limb, and extend thigh.

Anterior Crural Region.

Tensor vaginæ, crural muscles, and ilio-femoralis parvus.

Tensor Vaginæ *et* Ilio-aponeuroticus.—Situated on flank

n front of gluteus externus, and on the outside of vastus ex-ernus (Pl. VIII. fig. 1, *a*).

Figure: Flat and triangular, radiating downwards and back-wards.

Origin: The fleshy portion arises from the anterior spinous pro-ess of ilium, and from it springs the aponeurotic portion of ascia lata, which is divided into superficial and deep. The deep ayer passes between vastus externus and triceps abductor fe-noris, becoming united to tendon of gluteus externus.

Insertion: Into external border of femur. The superficial ayer is again subdivided, and spread outwards on the triceps bductor, being confounded with the aponeurosis at the croup, nd inwards over the internal crural muscles; uniting with emoral aponeurosis, it is prolonged down to the patella, and nserted into tibia and aponeurosis of posterior head of riceps.

Relation: Internally, with iliacus rectus and vastus externus; xternally, with skin; posteriorly, with gluteus magnus and ex-ernus.

Action: Complex; draws the femur forwards, flexes hip, lightly abducts stifle, and renders tense the fascia lata.

Crural Muscles.—Rectus femoris, vasti, and crureus. These ay be described as 3 or 4, or a single triceps cruralis. They re intimately blended, and cannot be separated without cutting uscular fibre.

Rectus Femoris.—Situated on anterior prominent part of aunch (Pl. VII. fig. 2, *l*).

Figure: Thick, elongated, and fusiform, consisting of two flat ndons; a fleshy intersected belly, terminating in tendon and oneurosis.

Origin: From two depressions, one on each side of the neck ilium, just above acetabulum, attached loosely to upper part femur.

Insertion: Into upper anterior part of patella, its aponeurosis nning into the fascia of thigh.

Relation: It lies between the vasti above crureus, and is r
lated superiorly with iliacus and tensor vaginæ; externally an
anteriorly, with skin and panniculus carnosus.

Action: To flex femur on ilium, and extend leg.

Vastus Externus.—Situated on the antero-external part
the haunch (Pl. VII. fig. 2).

Figure: Broad, thick, and semi-oval, extending downward
and forwards; it is fleshy, tendinous, and aponeurotic.

Origin: From neck of femur, and postero-external part
trochanter major, anterior and outer border of femur, and i
trochanter minor externus.

Insertion: Upper and outer part of patella.

Relation: Externally, with tensor vaginæ and gluteus e
ternus; internally, with rectus and crureus; posteriorly, wit
triceps abductor femoris and femur.

Action: To extend stifle joint and thigh, and draw anteri
part of thigh outwards.

Vastus Internus.—Situated on the antero-internal part
the haunch (Pl. VII. fig. 2, *k*).

Figure: Semi-oval, fleshy, becoming aponeurotic at its inse
tion. The externus and internus form a channel in which
lodged the rectus and crureus.

Origin: From neck of femur, antero-internal surface of bon
and trochanter internus.

Insertion: Upper and inner side of patella.

Relation: Internally, with rectus; externally, with sartori
pectineus, psoas magnus, iliacus; posteriorly, with femur; a
teriorly, with crural aponeurosis.

Action: To adduct thigh and extend leg.

Crureus.—Situated below rectus, and between the two vas

Figure: Cylindrical, tendinous, and fleshy; with difficulty
is separated from the vasti.

Origin: From middle third of anterior border of femur, a
anterior surface of lower part of bone.

Insertion: Into supero-internal surface of patella.

Plate VIII

MUSCLES OF HIND LEG, TAIL
AND FEMALE GENERATIVE ORGANS

PLATE VIII.

MUSCLES OF HIND LEG AND TAIL.

Fig. 1.—Outer Side of Left Thigh with the Sacrum, from which the Aponeurosis of the Cutaneous Muscles of the Chest and Abdomen have been removed.

a. Tensor fasciæ latæ. *b.* Gluteus maximus. *c.* Upper part of Gluteus medius. *d d d.* Biceps femoris. *e e.* Semi-tendinosus.

Fig. 2.—Right Hind Leg, seen from the front and outer side.

a. Tibialis anticus. *a' a' a'.* Branches into which its tendon splits. *b.* Extensor longus digitorum. *b'.* Its tendon. *c.* Peroneus longus. *c'.* Place of junction of the tendon of this with that of the former muscle. *d.* Extensor brevis digitorum. *e.* Upper transverse ligament of tarsal joint. *f.* Lower ligament of same joint.

Fig. 3.—Right Hind Leg, seen from the inner side and behind.

a. Popliteus. *b.* Flexor perforatus. *b'.* Its tendon. *b''.* Spot where its tendon passes over the projection of the os calcis. *c.* Flexor perforans. *c'.* Its tendon. *d.* Flexor longus hallucis. *d'.* Spot where its tendon unites with that of the flexor perforans.

Fig. 4.—Muscles of the Tail, Anus, and Female Generative Organs.

a. Levator caudæ. *b.* Abductor caudæ. *c.* Depressor caudæ. *d.* Coccygeus. *e.* Sphincter ani. *f.* Levator ani. *g.* Constrictor vaginæ.

Relation: Anteriorly, with rectus; posteriorly, with femur; and on each side with the vasti.

Action: To draw patella upwards, and thus assist in the extension of the leg.

Rectus Parvus *vel* Ilio-femoralis Parvus.—Situated in front of hip joint.

Figure: Pale and fusiform, with fleshy belly and tendinous extremities.

Origin: From brim of acetabulum, between the tendons of origin of rectus and capsular ligament of hip joint.

Insertion: Into anterior and upper part of femur, just above hip joint, by a long slender tendon.

Relation: Externally, with rectus; posteriorly, with femur.

Action: To render tense capsular ligament of hip joint during extension of leg, and assist in rotating the thigh.

Gluteal Region or Croup.

Gluteus externus, maximus, and internus. These muscles are covered by a continuation of the lumbar fascia, which is carried over the posterior crural region, blending with the superficial layer of fascia lata. This gluteal aponeurosis is attached to anterior spine of ilium and spines of sacrum.

Gluteus Externus *vel* Ilio-trochantericus.—Situated on external part of croup (Pl. VIII. fig. 1).

Figure: V-shaped, apex backwards, fibres converging downwards. It consists of a muscular and aponeurotic portion; the former is double, ending in a flat tendon; the aponeurotic joins the fleshy portion, and runs under the triceps abductor femoris.

Origin: Anteriorly, from anterior spine of ilium and 3 first sacral bones and lumbar fascia.

Insertion: Posteriorly, to a ridge extending from trochanter minor externus; the aponeurotic portion reaches the tuberosity of ischium and sacro-sciatic ligament.

Relation: Externally, with fascia; anteriorly, with tensor vaginæ; posteriorly, with triceps abductor; internally, with maximus.

Action: To flex femur on pelvis and abduct thigh.

Gluteus Maximus *vel* Ilio-trochantericus Magnus.—Situated on external and middle part of haunch (Pl. VIII. fig. 1, *b*).

Figure: Five-sided, large, thick, and fleshy in its centre, terminating in two tendons.

Origin: Anteriorly, posterior and anterior spines, crest, dorsum, and shaft of ilium by fascia, spines and transverse processes of 3 last lumbar and 2 first sacral vertebræ, lumbar fascia and sacro-sciatic ligament.

Insertion: Posteriorly, by 2 tendons, one going to summit of trochanter major; the other passes along its convexity, playing over a synovial bursa, terminating in a ridge just below it.

Relation: Externally, with externus and fascia of croup; internally, with internus, sacro-sciatic ligament, and ilium; anteriorly, with tensor vaginæ and longissimus dorsi; posteriorly, with triceps abductor femoris and biceps rotator tibialis.

Action: To extend femur on pelvis or pelvis on loins, to assist in progression, and when the limbs are fixed, to assist in rearing, when the trunk is fixed, in kicking.

Gluteus Internus *vel* Ilio-trochantericus Parvus.—Situated below and postero-external to maximus (Pl. VIII. fig. 1, *c*).

Figure: Short and fan-shaped, the fibres converging backwards.

Origin: From neck of ilium, sacro-sciatic ligament, ischiatic spine, and capsular ligament of hip.

Insertion: Posteriorly, by tendon to a roughened space in front of convexity of trochanter major of femur.

Relation: Externally, with maximus; internally, with femur and hip joint.

Action: To extend hip, abduct thigh, and rotate femur inwards.

Posterior Crural Region.

Triceps Abductor Femoris *vel* Ischio-tibialis Externus.—Situated on postero-external part of haunch and thigh, behind glutei.

Figure: Large and fleshy, made up of two prismatic portions, with two tendons of origin and three insertions—the anterior, tendinous, central, tendinous and aponeurotic, posterior, entirely aponeurotic.

Origin: Anteriorly, head from spine of sacrum, coccyx, and sacro-sciatic ligament; posteriorly, from internal part of ischiatic tuberosity, below which it sends a strong tendon to a circular impression behind trochanteric ridge.

Insertion: Anterior division into external lateral side of patella and its external ligament; central, into external lateral side of tibia, a ridge on its upper part and fascia of leg, the posterior terminating by a strong aponeurosis on fascia of leg.

Relation: Externally, with fascia and skin; superiorly, with gluteus maximus; internally, with gastrocnemius; posteriorly, with biceps rotator tibialis.

Action: To flex femur on pelvis, abduct leg, extend thigh, and assist in rotating it.

Biceps Rotator Tibialis *vel* Ischio-tibialis Medius or Semi-tendinosus.—Situated on posterior part of haunch, behind triceps (Pl. VIII. fig. 1, *d*, *d*, *d*, *e*, *e*).

Figure: Long, cylindrical, bifid above, consisting of pale, fleshy fibres, enclosed in a strong aponeurosis.

Origin: Superiorly, by one head, from spines of sacrum, 2 first bones of coccyx, and sacro-sciatic ligament; the other comes from the tuberosity of ischium, and by strong fascia from each side of the middle of the body of gastrocnemius.

Insertion: Supero-internal part of tibia, its aponeurosis running to the tibial periosteum.

Relation: Externally, with skin; internally, with gastroc-

nemius externus; posteriorly, with triceps abductor femoris; anteriorly, with the large head of adductor.

Action: To extend femur on pelvis, flex elbow, abduct and rotate limb, and render tense the fascia.

Ischio femoralis.—Situated on the posterior aspect of femur between adductor magnus and obturator externus.

Figure: Long and ribbon-shaped, running downwards and outwards.

Origin: From inferior surface of tuberosity of ischium in front of inferior spine.

Insertion: A scabrous line on posterior of femur to the outer side of trochantericus internus.

Relation: Anteriorly, with femur and abductor externus; posteriorly and externally, with adductor magnus and longus; internally, with obturator internus, gemini, and the sciatic nerves.

Action: To extend, adduct, and rotate upper part of femur backwards and outwards.

Obturator Externus *vel* Subpubio-trochantericus Externus.—Situated on inferior surface of os innominatum, below the obturator foramen.

Figure: Quadrilateral, its belly consisting of delicate fibres.

Origin: From surface of pubis and ischium; external surface of obturator foramen and ligament.

Insertion: Trochanteric fossa.

Relation: Inferiorly, with pectineus and adductors; superiorly with gemini and obturator internus; posteriorly, with triceps abductor and ischio-femoralis.

Action: To rotate femur outwards and adduct the limb.

Obturator Internus *vel* Subpubio-trochantericus Internus.—Situated within the pelvic cavity on upper part of the obturator foramen.

Figure: Fan-shaped, with a delicate fleshy belly, terminating in a flat tendon.

Origin: From internal surface of obturator foramen and liga-

ment it passes round the external part of ischium, behind acetabulum, where its tendon joins the pyriformis.

Insertion: The trochanteric fossa.

Relation: Superiorly, with peritoneum; inferiorly, with obturator ligament, ischium, and pubis.

Action: To rotate upper part of limb outwards.

Pyriformis *vel* Sacro-trochantericus.—Situated on superolateral side of pelvic cavity.

Figure: Flat, elongated, semi-penniform, with a long tendon of insertion.

Origin: From internal surface of transverse process of first sacral vertebra, inner surface of the shaft of ilium, and ramus of ischium; passing through inner side of sacro-sciatic ligament, it winds round the ischiatic notch to join the tendon of obturator internus.

Insertion: Trochanteric fossa.

Relation: With pelvic bones internally; covered by peritoneum; externally, with pelvis, gemini, and obturators, and the crural nerves.

Action: To rotate femur and stifle outwards.

Gemini *vel* Ischio-trochanterici.—Situated on the ramus of ischium, but is inconstant and variable in form.

Figure: A pair of very delicate muscles, with fleshy belly and tendinous insertion.

Origin: From antero-inferior border of shaft of ischium on either side of the conjoined tendon of pyriformis and obturator internus, their fibres passing outwards, and blending with it. There may be another large flat muscle of two layers, situated between the above and obturator externus, originating from internal border of ischial ramus.

Insertion: Trochanteric fossa.

Relation: Posteriorly, with sciatic nerves; anteriorly, with capsular ligament of hip and obturator externus.

Action: To rotate upper part of femur backwards and outwards.

Diaphragmatic Region.

(Pl. VII. fig. 1, and description of plate.)

The Diaphragm *et* Musculo aponeuroticus is the partitio which separates the thorax from the abdomen; it slopes o liquely, downwards and forwards, and is fleshy and aponeuroti

Figure: Elliptical, wide superiorly. The thoracic surface convex and lined by pleura; the abdominal, concave and covere by peritoneum. It is divided into a body or septum, and tw crura or appendices. The body, or greater muscle, is made up a fleshy periphery and an aponeurotic centre.

Origin: The fleshy portion arises from the body and cartilag of eighth rib, superior internal surface of ensiform cartilage, an cartilages of all the false ribs but last; the fibres converge t wards the centre.

Insertion: Between ribs and spine in the aponeurotic expan sion or cordiform tendon. In its centre is a large opening *foramen dextrum*, through which passes the posterior vena cav The *crura* or pillars, two in number, lie below the vertebræ o each side of posterior aorta in sublumbar region. The right the longest and largest, and arises from the inferior surface the bodies of all the lumbar and two posterior dorsal vertebr by strong tendinous fibres which blend with inferior comme ligament. The left differs from the right in only rising fro two anterior lumbar vertebræ. Between the pillars, and incline to the left, is a second opening, the *hiatus aorticus*, throug which passes the posterior aorta, venæ azygos, and thoracic duc Below this, the crura unite for a short distance, then decu sate, forming a fleshy belly, which again bifurcates, leaving third opening, the *foramen sinistrum*, for the passage of œs phagus, pneumagastric, and sympathetic nerves; the crura no join the large muscle. There are thus three openings—*hiat aorticus* above, *foramen sinistrum* in the middle, and *foramen dextrum* below.

Relation: Anteriorly, with lungs; posteriorly, with liver, tomach, spleen, and large colon.

Action: A muscle of inspiration, assisting in expulsive efforts.

MUSCLES OF THE HEAD.

Auricular Region.

The EXTRINSIC muscles of the ear are 8—3 attollentes, 3 retra-entes, 1 abducens, and 1 mastoido-auricularis.

ATTOLLENS MAXIMUS *vel* TEMPORO-AURICULARIS EXTERNUS.—ituated immediately under the skin above temporal muscle in ont of the inner side of ear (Pl. VI. fig. 2, *b*).

Figure: Broad, thin, and fleshy, mingled with aponeurosis.

Origin: From parietal ridge, extending from occipital crest as r forward as orbital process of frontal bone, joining its fellow.

Insertion: Into scutiform cartilage, sending a small band to e internal border of the base of conchial cartilage.

Relation: Externally, with skin; internally, with temporalis nd attollens posticus; posteriorly, with the retrahentes.

Action: To approximate the ears, turning their openings for-ards.

ATTOLLENS ANTERIORIS *vel* ZYGOMATICO-AURICULARIS.—*Situ-ion:* Subcutaneous, in front of the ear (Pl. VI. fig. 2, *c*).

Figure: Small and thin, consisting of 2 or 3 flat, fleshy ndles, joined by condensed cellular tissue.

Origin: From superior part of zygomatic process by a flat ndon, which blends with the orbicularis palpebrarum.

Insertion: By two sets of fibres—one to the anterior part of utiform, the other to base of conchial cartilage, blending with e scuto-auricularis externus and deprimens aurem.

Relation: Externally, with skin; internally, with temporal uscle; posterior, with parotid gland.

Action: To draw ear forwards and depress it.

ATTOLLENS POSTICUS *vel* TEMPORO-AURICULARIS INTERNUS.—uated beneath attollens maximus (Pl. VI. fig. 2, *d*).

Figure: Triangular.

Origin: From parietal ridge and crest of occiput.

Insertion: The tendon is directed obliquely round the intern face of the concha, terminating in the conchial cartilage belo insertion of retrahens externus.

Relation: Externally, with maximus and retrahens externu internally, with temporal bone.

Action: To elevate the ear. The three attollens prick the ea

Abducens Aurem Deprimens *vel* Parotido-auricularis (P VI. fig. 2, *a*).—Situated below the root of the ear on outer sid of parotid gland.

Figure: Flat and thin, tendinous at its insertion.

Origin: From external surface of parotid gland.

Insertion: Into infero lateral part of the concha.

Relation: Externally, to a thin aponeurotic layer of pann culus; internally, with parotid.

Action: To draw ear down, and turn it outwards.

Retrahentes Aurem are 3 muscles—cervico-auricularis e ternus, or superioris, the medius, and the internus or inferioris.

Cervico-auricularis Superioris.—Situated on the poll the side of the ear.

Figure: Thin and flat, joining attollens maximus.

Origin: From cordiform portion of ligamentum nuchæ an crest of occiput.

Insertion: Into middle of the posterior surface of conchi cartilage.

Relation: Externally, with skin; internally, with retrahe internus medius.

Action: To draw the ear backwards.

Cervico-auricularis Medius.—Situated below preceding.

Figure: Broad and thin.

Origin: Same as the externus, its tendon passing und superior external portion of parotid gland.

Insertion: Into posterior part of base of concha under t parotido-auricularis.

Relation: Externally, with preceding; internally, with in-rnus and parotid gland.

Action: To rotate the ear.

Cervico-auricularis Inferioris.—Situated below the pre-ding.

Figure: Thin and fleshy.

Origin: From ligamentum nuchæ and crest of occiput.

Insertion: Outer and lower part of concha winding round its se and posterior part of auricular cartilage.

Relation: Externally, with medius; internally, with parotid.

Action: The three retrahentes straighten the ear, the opening ing outwards and slightly forwards.

Mastoido-auricularis.—Situated deeply at the base and ner side of concha.

Figure: Flat and slender; made up of two small fleshy ndles united by cellular tissue.

Origin: From mastoid and auditory processes.

Insertion: Into base of concha.

Action: To draw concha downwards and shorten the external r.

The chief intrinsic *muscles* of the external ear are scuto-au-ularis, externus and internus.

The Scuto-auricularis Externus.

Origin: From external surface of the scutiform cartilage.

Insertion: Inner side of conchial cartilage. It is composed of o bundles covered by attollens maximus, and draws the open-g of the ear outwards and forwards.

The Scuto-auricularis Internus consists of two pale bundles nich cross each other.

Origin: Under surface of scutiform cartilage.

Insertion: Contracted portion of the base of concha.

Action: To draw opening outwards and backwards.

Palpebral Region.

Levatores palpebræ superioris externus and internus, and t orbicularis palpebræ.

Levator Palpebræ Superioris Externus *vel* Fronto-supe ciliaris.—Situated immediately above the orbit. Subcut neous.

Figure: Short, thin, and narrow.

Origin: From external surface of frontal bone above fronta arch and near the supra-orbital foramen. The fibres pass dow wards and outwards, blending with the orbicularis at the superi part of the lids towards the inner angle of the eye.

Relation: Externally, with skin; internally, with the bone.

Action: To elevate upper eyelids.

Orbicularis Palpebræ *vel* Musculus Ciliaris.—Situate round eyelids. Subcutaneous (Pl. VI. fig. 2, *f*).

Figure: A large, thin, oval sphincter, common to upper an lower eyelids.

Origin: It is covered by skin, to which it intimately adhere The superior portion is the larger, and consists of numero fleshy fasciculi, with a small flat tendon.

Insertion: Into the lachrymal tubercle, on the orbital rim lachrymal and frontal bones.

Action: To close the eyelids.

Levator Palpebræ Superioris Internus *vel* Orbito-pal pebralis.—Situated within the ocular sheath in relation wit the superior straight muscle of the eyeball.

Figure: Broad, thin, and bandlike.

Origin: From superior border of optic foramen, on a level wit lachrymal gland. Passing under, it emerges aponeurotic, ru ning between the conjunctival membrane and fibrous portion upper lid.

Insertion: Inner surface of lid and tarsal cartilage.

Action: To raise upper lid.

Facial Region.

Divided into—*Anterior Maxillary:* Zygomaticus, levator labii superioris alæquæ nasi, nasalis longus, labii superioris, dilatator naris lateralis; three dilatatores narium, viz., transversalis, inferioris, and superioris; depressor labii superioris, levator labii inferioris, depressor labii inferioris, buccinator, caninus, and orbicularis oris. *Posterior Maxillary:* Masseter, temporalis, stylomaxillaris, digastricus, pterygoideus internus and externus.

Anterior Maxillary Region.

Zygomaticus *vel* Zygomatico-labialis.—Situated on the side of face, its fibres extending forwards.

Figure: Ribbon-shaped and very pale.

Origin: By a flat tendon from surface of the masseter, near the anterior aspect of the zygomatic or maxillary spine.

Insertion: The angle of mouth, its fibres blending with those of alveolo-labialis.

Action: To retract angle of mouth.

Levator Labii Superioris Alæquæ Nasi *vel* Super-naso-labialis.—Situated on the side of cheek, running obliquely forwards (Pl. VI. fig. 2, *g*).

Figure: Long and flat, aponeurotic superiorly, dividing into two unequal bands, between which passes the dilatator naris lateralis.

Origin: Side of nasal bone at its junction with superior maxilla and lachrymal bone; the anterior division, the larger and thicker, passes under the dilatator naris lateralis.

Insertion: The alæ of nose and upper lip, the posterior division reaching the angle of mouth.

Action: To retract upper lip and angle of the mouth, and to dilate nostrils.

Nasalis Longus Labii Superioris *vel* Supero-maxillo-labialis.—Situated on side of cheek below the preceding; it runs obliquely forwards.

Figure: Pyramidal, with fleshy belly and flat tendon of insertio

Origin: From external surface of superior maxilla at its jun tion with malar and lachrymal. The tendon passes to th extremity of nose, where, with its fellow, it forms an aponeurot expansion.

Insertion: It is lost in the upper lip.

Action: To elevate and corrugate the middle of upper li and dilate the false nostrils.

Dilatator Naris Lateralis *vel* Supero-maxillo-nasalis Ma nus.—Situated on side of cheek between the branches of levat labii superioris, running almost vertical.

Figure: Pyramidal, having a flat belly and tendon of origin

Origin: From the anterior extremity of maxillary spine.

Insertion: Fleshy, into the side of nostril and upper lip, blen ing with orbicularis oris.

Action: To dilate nostrils and retract upper lip.

Dilatator Naris Transversalis *vel* Naso-transversalis.— Situated at the supero-anterior extremity of nose in front nostrils.

Figure: Flat and four-sided, consisting of transverse fibr which cross each other.

Origin: Nasal peak.

Insertion: Superior surface of cartilaginous alæ of nostrils.

Action: To dilate nostrils.

Dilatator Naris Inferioris *vel* Nasalis Brevis Lai Superioris *vel* Supero-maxillo-nasalis Brevis.—Situated side and little behind the nostrils (Pl. VI. fig. 2, *m*).

Figure: Long and four-sided muscle.

Origin: Fleshy termination, aponeurotic origin, upper fi margin of superior and anterior maxillary bones.

Insertion: Membrane of false nostrils.

Action: To dilate false and assist in dilating true nostril.

Dilatator Naris Superioris (Pl. VI. fig. 2, *n*).—Situat just above preceding.

Figure: Broad and thin, with aponeurotic insertion.

Origin: From lateral surface of free margin of nasal bones.
Insertion: Membrane of false nostril.
Action: To assist preceding.

Depressor Labii Superioris.—*Situation:* Inner surface of pper lip covered by buccal membrane.
Figure: Broad, thin, and fleshy.
Origin: From internal maxilla at the alveoli, extending from teral incisors to tushes.
Insertion: The diverging fibres pass obliquely forwards to end with upper lip and nasal cartilages.
Action: To compress upper lip and anterior incisors.

Levator Labii Inferioris *vel* Levator Menti.—Situated on ner surface of under lip below mucous membrane.
Figure: Like the preceding.
Origin: From alveoli of inferior maxilla between lateral cisors and tushes.
Insertion: Under lip by diverging fibres.
Action: To elevate under lip and chin, and press lip on eth.

Depressor Labii Inferioris *vel* Maxillo-labialis.—Situated ng the surface of the lower jaw.
Figure: Long and pyramidal.
Origin: Posteriorly, in common with buccinator, from a tu-rcle on superior maxilla and superior border of inferior maxilla, hind the molar alveoli.
Insertion: The infero-lateral part of under lip by a flat tendon.
Action: To depress under lip.*

Buccinator and Caninus *vel* Alveoli Labialis.—Situated on e of face, filling the space between the jaws (Plate V. fig. 2, *i*).

* While dissecting at the Edinburgh Veterinary College in December 3, I was particularly struck with the action of this muscle; its tendon livides in the areolar and muscular tissue of chin and posterior lip, and ction is not quite to depress the under lip, but to elevate the chin and r lip, and thus separate the lower lip from the lower incisors. This e opinion, I find, recorded by the late Professor Goodsir in his posthu-s manuscript.

Figure: Flat and thin, consisting of two layers, sometir described as separate muscles.

Origin: Alveolar tuberosity of superior maxilla, alveoli of mo teeth of both jaws, and interdental spaces as far as the tushes

Insertion: It blends with orbicularis oris.

Relation: Internally, buccal glands and mucous membrane

Action: To elevate the angle of mouth, throw the food ba between the molars, and prevent the buccal membrane fr being nipped by teeth.

Orbicularis Oris *vel* Labialis. — Disposed as a sphinct round the mouth.

Figure: Oval; they embrace lips, uniting at the commissu and form the substance of the lips. They are not attached bone unless by other muscles.

Action: To approximate and close lips.

Temporo *vel* Posterior Maxillary Region.

Masseter Externus *vel* Zygomatico-maxillaris.—Situat on upper part of the cheek (Pl. V. fig. 2, *h*).

Figure: Broad, thick, flat, and irregularly four-sided, consi ing of several layers intersected by tendinous bands, enclosed aponeurosis.

Origin: From zygomatic spine and external surface of sup rior maxilla.

Insertion: Outer surface of posterior border and angle of i ferior maxilla.

Relation: Externally, with facial panniculus. Over its surfa are distributed the facial nerves; along its anterior border is t parotid duct, glosso-facial artery, and vein; and, buried benea its substance, the venæ varicosæ.

Action: To elevate lower jaw and close the mouth, being important agent in mastication.

Temporalis *vel* Temporo-maxillaris.—Situated in the te poral fossa, which it fills.

Figure: Strong and fleshy, intersected by tendons, and overed by fascia.

Origin: From parietal ridge, and part of occipital crest, zygo-atic process of temporal and external surface of parietal bones.

Insertion: Coronoid process of inferior maxilla.

Relation: Externally, with muscles of the ear and scutiform rtilage; inferiorly, with the pterygoid.

Action: To assist in closing the mouth.

Stylo-maxillaris.—Situated behind lower jaw.

Figure: Pyramidal and fleshy.

Origin: From styloid process of occiput.

Insertion: Into posterior angle and inner margin of lower jaw.

Relation: Externally, with parotid gland; internally, with ttural pouch.

Action: To depress lower jaw and open mouth.

Pterygoideus *vel* Masseter Internus or Spheno-maxil-aris.—Situated on inner surface of lower jaw, in the internal axillary space; opposed to masseter externus.

Figure: Strong, fleshy, with numerous tendinous intersections.

Origin: From inferior part of sphenoid crest of palatine ptery-id bone, tuberosity of superior maxilla, and fossa on inner rface of posterior angle of inferior maxilla.

Insertion: Inner posterior border and angle of inferior maxilla.

Relation: Posteriorly, with pterygoideus externus and tem-ralis; internally, with guttural pouch, hyoid bone, muscles, d vessels.

Action: To raise jaw and close the mouth; when acting singly, produce lateral motion.

Pterygoideus Externus. — Situated behind preceding, in nt and inner side of temporo-maxillary articulation.

Figure: Short, thick, and fleshy, with tendinous intersections.

Origin: From internal surface of sphenoid.

Insertion: Passing backwards and downwards, it reaches a ghened depression on inner side of inferior maxilla, just ow its condyle.

Relation: With temporalis and pterygoideus internus.

Action: To assist internus.

Digastricus.—A continuation of stylo-maxillaris. Situate along inner surface of lower jaw, in intermaxillary space.

Figure: Two fleshy bellies, united by a mesial tendon.

Origin: From styloid process of occipital bone.

Insertion: By a long flat tendon to inner surface of lower jaw near its symphysis; the tendon plays through a groove formed by the tendon of hyoideus magnus, at the body of the hyoid bone.

Action: To elevate hyoid, and depress inferior maxilla.

Hyoidean Region.

Mylo-hyoideus.—Situated in intermaxillary space, along the inner side of lower jaw.

Figure: Broad, flat, and penniform; it is attached to a line running along inferior maxilla, just below the alveolar processes, extending forwards as far as symphysis—the inferior surface of body and spur process of hyoid bone meeting its fellow from the opposite side in the mesial line.

Relation: Externally, with digastricus and lymphatic gland; internally, with sublingual glands, Wharton's canal, genio-hyoideus, hyo-glossus longus, and genio-hyo-glossus, hypogloss and lingual nerves; posteriorly, with the pterygoidei.

Action: To elevate tongue, by drawing os hyoides upwards and forwards.

Genio-hyoideus.—Situated as preceding.

Figure: Long and fusiform, tendinous at its extremity.

Origin: From the jaw, near its symphysis.

Insertion: Free extremity of spur process of os hyoides.

Relation: Externally, with preceding; internally, with genio-hyo-glossus, joining its fellow.

Action: To draw os hyoides towards antero-inferior part of intermaxillary space, and thus elevate back of tongue.

Hyoideus *vel* Kerato-hyoideus Magnus.—Situated on outer de of pharynx and larynx, and inner side of guttural pouch, ehind the greater cornua of os hyoides, running in the same irection.

Figure: Short, fusiform, and tendinous at either extremity.

Origin: From postero-inferior angle of greater cornua of os yoides.

Insertion: Into a small tubercle on heel-like portion of the one.

Relation: Externally, with pterygoid muscle; internally, with harynx, guttural pouch, hypoglossal nerve, glosso-facial artery, nd glosso-pharyngeal nerve. The inferior tendon forms a ring hrough which plays the middle tendon of the digastric.

Action: To draw the body of the os hyoides backwards and pwards, antagonising the preceding; it also assists in dilating he glottis.

Hyoideus *vel* Kerato-hyoideus Parvus.—Situated above the receding muscle.

Figure: Small, flat, and triangular.

Origin: From inferior border of anterior extremity of greater ornua, and posterior border of lesser cornua.

Insertion: Into body and heel process of os hyoides, filling p the space between them.

Relation: Externally, with basio-glossus and lingual arteries; ternally, with buccal membrane.

Action: To draw body of bone to the greater cornua.

Hyoideus Transversus.—A short, thin muscle, joining the sser cornua together by their superior extremities.

Action: To approximate the lesser cornua.

Stylo-hyoideus.—*Situation:* It fills up the space between e posterior part of the angle of greater cornua and styloid pro- ss of occipital bone.

Figure: Flat and triangular.

Origin: Anterior border of styloid process.

Insertion: Posterior part of greater cornua.

Relation: Externally, parotid gland; internally, guttur pouch. Its fibres blend with those of the origin of digastric.

Action: To draw back and elevate the greater cornua of hyoides.

Glossal Region.

Hyo glossus Longus *vel* Stylo-glossus.—Situated on out surface of tongue, near tip.

Figure: Long and flat.

Origin: From external surface of the cornua of os hyoides.

Insertion: Substance of tongue at first molar tooth

Relation: Externally, with mylo-hyoid and sublingual glan sublingual nerve, and canal of Wharton; internally, with geni hyo-glossus and hyo-glossus brevis.

Action: To retract and repress tongue within the mouth.

Hyo-glossus Brevis *vel* Basio-glossus.—*Situation:* Inn surface of hyo-glossus longus.

Figure: Broad, flat, square, and semi-penniform. The fibr pass obliquely forwards and upwards.

Origin: From the side of the body and spur process of hyoides and inferior part of large cornua.

Insertion: The side of tongue.

Relation: Externally, with mylo-hyoideus and hyo-gloss longus, hypo-glossal nerve, Wharton's canal, and mucous mem brane of mouth; internally, with hyoideus parvus and less cornua, genio-hyo and hyo-glossus brevis, lingual artery, a glosso-pharyngeal nerve.

Action: To draw base of tongue downwards and backward and assist in preceding.

Hyo glossus Parvus.—Situated inside of preceding muscle

Figure: A thin, semi-penniform muscle.

Origin: From inferior part of lesser cornua and spur proce of hyoid.

Insertion: Posterior part of tongue.

Action: To assist brevis.

Genio-hyo-glossus.—Situated on inferior surface of tongue.

Figure: Broad, thin, and semi-penniform. Its fibres pass obliquely upwards and backwards.

Origin: From lateral aspect of inferior maxilla, near its symphysis.

Insertion: Substance of the tongue and lesser cornua of hyoid.

Relation: Internally, to its fellow; inferiorly, to genio-hyoideus; superiorly, with substance of tongue; externally, with hyo-glossus longus and brevis, sublingual gland and artery.

Action: To retract tongue into the mouth, and press it against its base; singly, to draw it on one side.

Pharyngo-glossus.—These are a few fibres which unite the tongue to the pharynx, passing between the fibres of genio-hyo and hyo-glossus parvus.

Sacro-Coccygeal, or Region of the Tail.

Erector, curvator, depressor, and compressor coccygis. The three former pair arise from sacrum, the latter from the ischium. They are enclosed in a strong tendinous sheath, continuous with the sacro-sciatic and inferior ilio-sacral ligaments.

Erector Coccygis *vel* Sacro-coccygis Superioris.—Situated on supero-lateral part of tail.

Figure: Bundles of fibres, intersected by tendons, which gradually diminish in size from before backwards, each terminating in a flat tendon.

Origin: The tuberous summits and lateral aspect of posterior sacral spines, and superior surface of coccyx.

Insertion: Into coccygeal bones.

Relation: Internally, with its fellow and coccygeal vertebræ; externally, with skin and fascia; inferiorly, with curvator.

Action: When acting together, to elevate the tail; singly, to draw it upwards and laterally.

Depressor Coccygis *vel* Sacro-coccygis Superioris.—Situated on infero-lateral aspect of tail.

Figure: Similar to erector, but thicker.

Origin: Within the pelvis, from inferior surface of the body and transverse processes of sacrum, inner surface of sacro-sciatic ligament, and coccygeal vertebræ.

Insertion: By tendons, to inferior surface of all the coccygeal vertebræ successively.

Relation: Superiorly, with sacrum, coccyx, and curvator; inferiorly, with rectum; externally, with curvator and sacro-sciatic ligament; internally, with its fellow.

Action: To depress the tail; singly, to draw it downward and to one side.

Curvator Coccygis *vel* Sacro-coccygis Lateralis.—Situated on side of tail.

Figure: Similar in structure to the preceding. It is merely a continuation of spinalis lumborum.

Origin: From the spines of the 2 last lumbar, lateral aspect of sacral, and coccygeal vertebræ.

Insertion: Sides of coccyx, between erector and depressor.

Relation: Superiorly, with erector and inferior sacral ligament; inferiorly, with depressor; posteriorly, with compressor.

Action: To curve tail, or draw it sideways over the quarters.

Compressor Coccygis *vel* Ischio-coccygis.—Situated at the side of pelvis.

Figure: Large, thin, and triangular.

Origin: By aponeurosis, from superior ischiatic spine and inner surface of sacro-sciatic ligament, running upwards and backwards.

Insertion: By fleshy fibres, into the side of terminal sacral and first two coccygeal vertebræ.

Relation: Externally, with sacro-sciatic ligament; internally with curvator and rectum.

Action: To compress tail against rump, thus acting as a depressor.

Sphincter Ani.—Situated round the termination of rectum.

Figure: Circular, with central opening, some of the fibres lending with the muscles of perineal region. It is attached to ıe fascia covering the perineum, and to the coccygeal verte-:æ, and consists of two layers. The inner is white, being the ıctal fibres covered by skin.

Action: To close the anus.

Retractor Ani *vel* Ischio-analis.—Situated on the side of ıus.

Figure: Long, flat, and cylindrical, curving outwards.

Origin: From a rough margin just behind the acetabulum, ıd inner surface of sacro-sciatic ligament.

Insertion: Into lateral aspect of anus, its terminal fibres lending with the sphincter.

Action: To retract the anus.

Levator Ani *vel* Ischio-perinealis.—Situated on upper part rectum.

Figure: Thin and flat.

Origin: From 3 first coccygeal vertebræ.

Insertion: Its fibres blend with rectum.

Action: To elevate the anus.

Muscles of the Anterior Extremity.

Divided into four regions, corresponding to the four ana-mical divisions of the skeleton — the shoulder or scapular, e arm or brachial, the fore-arm or anti-brachial, and pedal or ɔt.

The *Scapular Muscles* are again divided into external and ernal, all arising from the scapula. The *External Scapular gion* includes the teres externus, antea, postea, and postea-natus minor; and the *Internal Scapular Region* includes the ɔscapularis, teres internus, scapulo-humeralis parvus, and aco-humeralis. The external are covered by a strong fascia, ich is rendered tense by the pectoralis parvus and teres

externus. From its inner surface slips pass which penetrat between the external scapular muscles. It is attached to th cartilage of shoulder above, in front to the internal fasci gradually becoming lost posteriorly.

Scapular Region.

Teres Externus *vel* Scapulo-humeralis Parvus.—The lon abductor of the arm, the scapular part of which corresponds t the deltoid of man. Situated on outer and posterior part o shoulder. It consists of two portions, anterior and posteric between which the aponeurotic insertion of levator humeri received (Pl. VI. fig. 5, *a*, *a*).

Figure: The posterior or inferior. The larger is triangul and very muscular, the fibres extending obliquely downward and forwards. It is lodged in a depression of the caput ma num. The anterior, or superior, is thin, aponeurotic, and ve tendinous, extending over the postea-spinatus.

Origin: The posterior section arises from the dorsal ang and posterior border of scapula; the anterior, by a strong fasci from a tubercle on spine of scapula and scapular fascia. Th unite inferiorly, and by tendon and fleshy fibres are inserte into the external tubercle, on the head of humerus, and a rid descending from it below the postea-spinatus minor, being r lated to the capsular ligament of shoulder joint.

Relation: Anteriorly, with postea-spinatus; posteriorly an inferiorly, with caput magnum; externally, with panniculu and fascia.

Action: To flex, abduct, and rotate humerus.

Antea-Spinatus *vel* Supero-acromio-trochiterius.—Situat in the antea-spinatus fossa of scapula (Pl. VI. fig. 2, *a*).

Figure: Triangular, with base downwards. Its fleshy fibr extend obliquely forwards; becoming tendinous, it is bifurcat for the passage of flexor brachii, the divisions being connect by aponeurosis.

Origin: From the anterior fossa of scapula, anterior surface of spine, anterior costa, and cervical angle of scapula.

Insertion: By a bifid head, externally, to summit of external trochanter or trochlea; internally, to summit of internal trochanter.

Relation: Externally, with panniculus; anteriorly, with pectoralis parvus; posteriorly, with spine and anterior border of postea-spinatus; internally, with bone; antero-inferiorly, with pectoralis magnus, subscapularis, levator humeri and tendon of flexor brachii.

Action: To extend humerus on scapula, and tense the fascia covering flexor brachii. It braces like a ligament the shoulder joint.

Postea-Spinatus *vel* Sub-acromio-trochiterius.—*Situation:* Lodged in the fossa-postea-spinatus (Pl. VI. fig. 2, *b*).

Figure: Broad, flat, and triangular, with the apex below, to which its fibres radiate; fleshy, with strong tendinous intersections.

Origin: From the posterior costa of scapula, posterior border of spine, cartilage of prolongation, and posterior fossa.

Insertion: By two divisions—one of which goes to the inner side of convexity; the other, a strong tendon, passes over the external trochanter, and is inserted into a roughened ridge below. On the head of the humerus, between the tendon and convexity, is a synovial bursa.

Relation: Externally, with capsular ligament; superiorly, with trapezius; inferiorly, by panniculus; anteriorly, with postea-spinatus; posteriorly, with teres externus, levator humeri and caput magnum.

Action: To flex, abduct, and rotate humerus outwards.

Postea-Spinatus Minor *vel* Scapulo-humeralis Parvus.—Situated below teres externus and postea-spinatus, along posterior border of scapula (Pl. VI. fig. 2).

Figure: Long and prismatic; fleshy; intersected by tendons.

Origin: From posterior border of scapula, posterior part of

fossa, postea spinatus, and a small tubercle on the external sid of the rim of glenoid cavity.

Insertion: Into the posterior part of the head of humerus.

Relation: Externally, with teres externus and postea-spinatus internally, with caput magnum.

Action: To abduct and rotate humerus outwards.

Subscapularis *vel* Subscapulo-trochantericus.—Situate on inner side of shoulder blade, occupying the subscapular fossa

Figure: Fan-shaped, forming three points superiorly, its fibre converging downwards.

Origin: From inferior three-fourths of subscapular fossa anterior and posterior angles of scapula.

Insertion: Into a small eminence on posterior part of interna trochanter, passing over its summit, where rests a small synovia bursa.

Relation: Externally, with scapula; internally, with serratu magnus; anteriorly, with antea-spinatus and pectoralis parvus posteriorly, with teres internus.

Action: To extend and adduct the arm, also to rotate it inwards

Teres Internus or Major *vel* Subscapulo-humeralis.—Th adductor of the arm. Situated just behind subscapularis, at th postero-internal part of scapula; it runs obliquely downward (Pl. VI. fig 4, *b*).

Figure: Elongated, wide in the middle, tapering at the ex tremity.

Origin: From dorsal angle and posterior costa of scapula.

Insertion: By a flat tendon, which joins the latissimus dors to the internal tuberosity of humerus, between the tendons o insertion of coraco-humeralis.

Relation: Postero-externally, with triceps; anteriorly, witl subscapularis; internally, with pectoralis magnus, latissimu dorsi, and serratus magnus; inferiorly, with coraco-humerali and humeralis obliquus.

Action: To flex, adduct, and rotate humerus inwards.

Scapulo-humeralis Grêle *vel* Parvus.—Situated behind an

below shoulder joint, between caput magnum and capsular ligament.

Figure: Slender and fusiform, with a pale, delicate, fleshy belly, and tendinous extremities.

Origin: From postero-inferior part of scapula, just above glenoid cavity, and capsular ligament of shoulder joint.

Insertion: Between the fibres of humeralis obliquus, into the posterior part of the head of humerus.

Action: To render tense capsular ligament of joint, and thus prevent its injury during flexion.

Coraco-humeralis.—Situated at inner and lower side of shoulder joint (Pl. VI. fig 4, *c*).

Figure: Long and fusiform, radiating from above downwards, belly and insertion fleshy.

Origin: From the beak of coracoid process of scapula. Passing between subscapularis and antea-spinatus, the tendon is succeeded by two fleshy bellies, superficial and deep. The latter, being thin and short, is inserted into the body of humerus just above its internal tuberosity; the former, by far the larger, is inserted into a rough surface about the middle of inner part of humerus.

Relation: Anteriorly, with flexor brachii; superiorly, with antea-spinatus and subscapularis; internally, with pectoralis magnus; inferiorly, with latissimus dorsi and teres internus, which pass between its two bellies.

Action: To extend, adduct, and partially rotate shoulder.

Humeral Region.

Like the scapular, the muscles are divided into anterior and posterior. The former are flexors of the fore-arm, two in number, flexor brachii and humeralis obliquus, both passing to the radius; the latter are extensors, and consist of the 3 heads of triceps—extensor brachii, scapulo-ulnaris, and anconeus—and are all inserted into the olecranon.

Anterior Brachial Region.

Flexor Brachii *vel* Coraco-radialis.—The biceps in ma situated in front of humerus, forming the bulge of arm.

Figure: Long and cylindrical, passing obliquely backward The tendon contains fibro-cartilage, and has a fleshy belly, int sected by tendinous fibres.

Origin: From the base of coracoid process of scapula, by strong tendon, which passes over the bicipital groove, whe there is a synovial bursa.

Insertion: By a short tendon, which passes under interna lateral ligament of elbow joint to a tuberosity on antero-intern part of head of radius, and to capsular ligament of elbow joi by aponeurosis.

Relation: Anteriorly, with panniculus carnosus and skin externally, with pectoralis anticus; internally, with corac humeralis; posteriorly, with humerus; superiorly, its tend passes between the two insertions of antea spinatus, where strong fascia envelopes its origin.

Action: To flex radius on humerus, extend arm on th shoulder, and render tense the ante-brachial fascia.

Humeralis Externus *vel* Obliquus or Humero-radialis.- Situated in musculo-spiral groove.

Figure: Flat, oblong, and almost entirely fleshy, wide abo its fibres, cover successively the posterior, external, and anteri surfaces of humerus, terminating on inner side of radius.

Origin: From postero-superior part of the body of humeru just behind articular head, winding round the bone under th external tubercle.

Insertion: Into a ridge on inner part of head of radius, aft passing through a transverse groove just below, and within th insertion of flexor brachii, and to the ulna, blending with th arciform ligament.

Relation: Externally, with caput medium; internally, with umerus; posteriorly, with flexor brachii.

Action: To extend ligament, flex elbow, and abduct the mb.

Posterior Brachial Region.

Scapulo-ulnaris *vel* Long Extensor of Fore-arm.—ituated on the postero-internal part of scapular region, adher-ng to caput magnum.

Figure: Broad and flat muscle, aponeurotic at its origin, with fleshy belly, divisible into an anterior and posterior por-on.

Origin: From dorsal angle and posterior costa of scapula.

Insertion: By tendon to inner part of apex of olecranon, and y fascia to ante-brachial aponeurosis.

Relation: Externally, to caput magnum; anteriorly, with iput medium; internally, to serratus magnus and levator umeri; superiorly, with latissimus dorsi and teres internus.

Action: To turn elbow inwards, adduct limb, flex shoulder, xtend fore-arm, and render tense ante-brachial fascia.

Triceps Extensor Brachii.—A bulky muscle, filling up the ngle between the posterior part of scapula and humerus. It is enerally described as caput magnum, medium, and parvum:

Caput Magnum *vel* Scapulo-ulnaris Magnus.—The great xtensor of fore-arm. Situated on infero-posterior part of houlder.

Figure: Thick and triangular, extending obliquely down-ards and backwards. It consists of three bundles, with ndinous intersections.

Origin: From dorsal angle and posterior costa of scapula.

Insertion: By a strong tendon into inner and upper part of ecranon, a synovial bursa being interposed between it and the ex.

Relation: Externally, with panniculus carnosus, teres exter-

nus, postea-spinatus, and latissimus dorsi; internally, wi pectoralis parvus and magnus; inferiorly, with caput medii and parvum; posteriorly, with scapulo-ulnaris.

Action: To flex shoulder and extend fore-arm.

Caput Medium *vel* Humero-ulnaris Externus.—The exte sor of fore-arm. Situated on infero-external part of arm, betwe preceding muscle and humerus.

Figure: Flat and oblong, extending obliquely backwards.

Origin: Aponeurotic from a ridge on the supero-poster part of the body of humerus, running upwards from exter tubercle to neck.

Insertion: Supero-posterior part of olecranon, and by apone rosis to extensor metacarpi.

Relation: Superiorly, with teres externus and postea-spinat minor; externally, with panniculus carnosus; posteriorly, wi caput magnum; inferiorly, with humeralis obliquus and extens metacarpi magnus; internally, with caput parvum and anconeu

Action: To adduct elbow and extend fore-arm.

Caput Parvum *vel* Humero-ulnaris Internus.—The midd extensor of fore-arm. Situated on inner and inferior part humerus, along the inferior border of magnum.

Figure: Long, slender, and triangular, with a tendino origin and fleshy belly. The fibres pass obliquely backward terminating in two flat tendons.

Origin: From postero-internal part of middle third of h merus, extending from inner tubercle.

Insertion: Into inner part of apex of olecranon, one tend passing through a small groove before its insertion, which below the other.

Relation: Superiorly, with caput magnum; externally, wi humerus, humeralis obliquus and caput medium; internally, wi insertion of coraco-humeralis, teres internus, and latissim dorsi; inferiorly, with anconeus.

Action: To abduct elbow. The three combined, extend for arm and elbow.

Plate VI MUSCLES. NECK CHEST & FORELEG

PLATE VI.

MUSCLES OF FORE-LEG.

Fig. 1.—Neck and Chest seen from below, the Left Fore-limb drawn aside.

a. Longus colli. *b*. Rectus capitis lateralis. *c*. Rectus capitis anticus minor. *d*. Thoracic portion of Pectoralis major. *e*. Clavicular portion of Pectoralis major. *ff*. Part of Pectoralis minor. *g*. Lower end of Pectoralis minor.

Fig. 2.—Muscles of Right Fore-limb, seen from the outer side.

a. Supra-spinatus. *b*. Infra-spinatus. *c*. Posterior part of Deltoid. *d*. Anconeus longus. *e*. Anconeus externus. *f*. Biceps. *g*. Extensor carpi radialis. *h*. Abductor pollicis longus. *i*. Flexor carpi ulnaris. *k*. Extensor communis digitarum. *k'*. Its tendon. *k''*. Accessory tendon derived from the superior sesamoid ligament. *l*. Extensor minimi digiti. *l* . Its tendon.

Fig. 3.—Left Fore-foot, seen from the inner side.

a. Anconeus internus. *b*. Flexor digitorum perforatus. *b'*. Its tendon. *b''*. Superior tendon passing to be inserted into the pastern bone. *b'''*. Inferior tendon to the same bone. *c*. Flexor digitorum perforans. *c'*. Head of the muscle arising from posterior surface of radius. *c''*. Its tendon. *c'''*. The tendinous band which leaves the posterior common ligament of knee joint. *d*. Spot where the flexor tendon of coffin bone passes through that of the coronet bone.

Fig. 4.—Right Fore-limb, seen from the inner side.

a. Subscapularis. *b*. Teres-major. *c*. Coraco-brachialis. *d*. Extensor cubiti longus. *e*. Flexor carpi radialis. *f*. Flexor carpi ulnaris.

Fig. 5.—Muscles of Fore-limb, seen from the outer side.

a a. Teres minor. *b*. Small head of Infra-spinatus. *c*. Upper part of Biceps, cut through and thrown up. *c'*. Its cartilaginous smooth surface which lies upon that of the humerus. *d*. Brachialis internus. *e*. Anconeus parvus. *f*. Extensor communis digitorum. *g*. Thiernesse's muscle. *h*. Philips' muscle. *h* . Its tendon.

Anconeus *vel* Humero-ulnaris Parvus.—The little extensor f fore-arm. Situated at the back of elbow joint (Pl. VI. fig. 2, *d*).

Figure: Small, thick, and triangular, almost entirely fleshy, lling up the space between the condyles of humerus or ole-anon fossa.

Origin: From postero-inferior part of humerus, epitrochlea-ssa, and capsular ligament of elbow joint.

Insertion: Antero-external part of ulna.

Relation: Posteriorly, with the caput muscles; anteriorly, ith elbow joint and humerus.

Action: To extend elbow joint and render tense the capsular gament.

Muscles of the Fore-Arm

e 11 in number, and are arranged in 2 groups, anterior and sterior, entirely clothing the bones, except at the inner side, here the radius contacts with the skin. The anterior are tensors, the posterior, flexors, and enclosed in the antebrachial scia, which is attached to the olecranon, inner head, and inner d outer sides of the lower end of radius. This fascia is ndered tense by scapulo-ulnaris and flexor brachii.

Anterior Region of Fore-arm.

Extensor metacarpi magnus, obliquus pedis, and suffraginis.

Extensor Metacarpi Magnus.—Situated in front of radius.

Figure: Pyramidal, extending downwards. It consists of a shy belly, and long flat tendon, which, about the middle third of lius, passes over the knee, terminating at the head of metacarpus.

Origin: From epitrochlea, trochlea, or external condyle of merus, capsular ligament of elbow joint, and external part of head of radius. The tendon passes through a groove or theca the antero-internal part of lower end of radius, where there is ynovial sheath or bursa, then over the knee through a second ovial apparatus. Two synovial sheaths are thus interposed

between the tendon and knee, which are bound down by th anterior annular ligament.

Insertion: To a prominent tuberosity on the anterior part o head of metacarpal bone towards its inner side.

Relation: Anteriorly, with fascia and skin; posteriorly, wit radius; externally, with extensor pedis; supero-internally, wit flexor brachii; inferiorly, with the obliquus.

Action: To extend carpus and metacarpus, and flex elbow joint

Extensor Metacarpi Obliquus.—Situated on externo-later and lower part of radius.

Figure: Triangular and penniform; broad and aponeuroti above, it terminates in a small tendon, which crosses obliqued the inferior extremity of anterior surface of radius below extens pedis and above extensor metacarpi magnus.

Origin: From external border of radius. Its tendon passe through the oblique groove on antero-internal lateral side o lower end of radius in a synovial sheath.

Insertion: The head of inner small splint.

Relation: Anteriorly, with extensor pedis, fascia, and skin; po teriorly, with extensor metacarpi magnus and bone; externall with extensor suffraginis.

Action: To extend and rotate leg outwards.

Extensor Pedis.—Situated on antero-external part of fore arm

Figure: Long and pyramidal, extending downwards; its bel is bifid inferiorly.

Origin: By tendinous fibres and one long tendon, which com mences about the inferior third of radius, which is somewha rounded until it reaches fetlock, where it flattens, forming a so of capsular ligament to the small pastern joint.

Origin: From base of epitrochlea and side of trochlea, anteri border of external lateral ligament of elbow joint, and outer pa of the head of radius. The tendon passes through a synovi theca in the external groove on lower end of radius, under a terior annular ligament below the knee. It sends a tendon-sl to join the extensor suffraginis, passes over the front of fetlo

int, having a small synovial bursa interposed below the fet-
ck. It receives on either side slips from the lateral suspensory
gament, is attached to capsular ligament of small pastern and
nterior part of first and second phalanx.

Insertion: Pyramidal process of os pedis. In ruminants this
uscle is divided into two portions—one common to both, the
her to internal digit.

Relation: Anteriorly, with skin and fascia; posteriorly, with
tensor metacarpi obliquus radius, knee, os metacarpus, suffrag-
is, and coronæ; internally, with extensor metacarpi magnus;
stero-externally, with extensor suffraginis.

Action: To extend foot and leg.

Extensor Suffraginis *vel* Lateral Extensor of Phalanges.
-Situated on externo-lateral part of fore-arm between extensor
dis and flexor metacarpi externus.

Figure: Semi-penniform, consisting of a fleshy belly, enveloped
a strong aponeurotic sheath, through which runs a strong
ndon above the knee. The belly ends in a slender round
ndon which passes through a theca in the vertical groove on
ternal side of lower extremity of radius, adown the external
pect of knee joint, reaching the anterior surface of large meta-
rpal bone. It terminates at the pastern joint, where there is a
all synovial bursa.

Origin: From external part of head of radius, external lateral
ament of elbow joint, body of radius, and lateral aspect of
na.

Insertion: Head of os suffraginis, related also to capsular
ment of fetlock joint below the knee. It is joined by two
dinous slips—one from flexor metacarpi externus pedis, the
er passing backwards and upwards to the trapezium.

Relation: Anteriorly, with extensor pedis and metacarpi obli-
s; posteriorly, with flexor pedis perforatus, perforans, meta-
pi externus, skin, and fascia.

Action: To extend fetlock and knee, assist extensor pedis in
extension of foot, and abduct the leg.

Posterior Region of Fore-arm.

Flexor metacarpus externus, medius, and internus, perforan perforatus, ulnaris, and radialis accessorius.

Flexor Metacarpi Externus.—Situated on externo-posteri part of radius.

Figure: Elongated and flattened, the fleshy belly being inte sected with tendon.

Origin: By a short thick tendon from postero inferior part epitrochlea of humerus and capsular ligament of elbow joint, te minating in two tendons; the anterior, longer, and more delicat passes through a synovial theca in a groove on the external su face of os trapezium.

Insertion: Head of outer splint bone. The posterior, short an flat, becomes inserted into superior part of os trapezium, its fibr blending with flexor metacarpi obliquus.

Relation: Externally, with skin and fascia; internally, wi flexor pedis perforans; postero internally, with medius an ulnaris accessorius; antero externally, with radialis accessorius.

Action: To flex carpus and metacarpus on radius.

Flexor Metacarpus Medius *vel* Obliquus.—Situated postero internal side of radius, extending almost directly dow wards.

Figure: Long and flat, bifid above; one head is small, with long slender tendon, the other large and fleshy.

Origin: Of large head, from the inferior part of internal co dyle and capsular ligament of elbow; of small head, postero-inferi surface of olecranon. They unite about half way down radius

Insertion: By one tendon to the supero-posterior and inn part of os trapezium, blending with externus.

Relation: Posteriorly, with skin and fascia: anteriorly, wi perforans; externally, with external flexor and ulnaris acce sorius; internally, with internal flexor.

Action: To assist preceding in flexing knee.

Flexor Metacarpi Internus.—Situated on postero-internal
le of fore-arm.

Figure: Long and flattened, with a fleshy belly.

Origin: By tendinous fibres from base of epicondyle of hu-
rus, just below the medius, and capsular ligament of elbow joint.

Insertion: Head of inner small splint bone, the long round ten-
n passing through a synovial theca on the inner side of knee joint.

Relation: Postero-internally, with skin and fascia; anteriorly,
th the flexor of foot; posteriorly, with medius.

Action: To flex carpus and metacarpus.

Flexor Pedis Perforatus *vel* Superficialis (Pl. VI. fig. 3,
b', *b''*, *b'''*).—Situated at the posterior part of fore-arm below
e preceding 3 muscles.

Figure: Long, thin, and prismatic, with belly fleshy, with
ndinous intersections, which extend almost to the knee, where
is succeeded by a long tendon which passes through a synovial
eca behind the knee, formed by the posterior annular liga-
ent. Above the knee, the tendon is joined by a broad band of
rous tissue, sometimes called the superior carpal ligament,
hich springs from the posterior surface of the radius, and is
ntinuous with ante-brachial fascia and perforans muscle; be-
ath the knee, the tendon assists in the formation of a synovial
eath for the perforans. At the fetlock it forms a ring or com-
te synovial sheath, through which passes the perforans tendon;
low the pastern joint the tendon splits into two.

Origin: From postero-inferior part of internal condyle of
merus, upper and outer aspect of radius, by a tendon common
it and perforans.

Insertion: Into projecting and lateral parts of os coronæ.

Relation: Posteriorly, with flexor metacarpi externus and
dius; anteriorly, with perforans.

Action: To flex pastern and fetlock joints, and assist in flexing
knee.

Flexor Pedis Perforans *vel* Profundus.—Situated between
ceding and radius (Pl. VI. fig. 3, *c*, *c'*, *c''*, *c'''*).

Figure: Long, tendinous at its origin, with a fleshy belly, whi ends just above the knee in a cordiform tendon. This tendo passes through a theca behind the knee, then through a sheat formed by perforatus below the knee; half down the metacarpu it is joined by the metacarpal ligament and tendons of the acce sory flexors; running between them, it passes through a ring fascia above the fetlock, and over the sesamoids, a synovial burs being interposed, over the postero-superior part of os corona where there is a second bursa, also over the navicular bone, an a synovial capsule, to the solar surface of os pedis.

Origin: In common with perforatus from postero-inferior pa of internal condyle of humerus and part of the head of radius.

Insertion: Supra-external semi-lunar ridge on solar aspect os pedis.

Relation: Posteriorly, with perforatus; anteriorly, with rad alis accessorius and radius.

Action: To flex the foot, and assist in flexion of pastern, fe lock, and ligament. At the pastern there is a fibrous sheat through which the tendons of perforatus and perforans pla formed by the posterior aspect of sesamoids, inferior sesamoi ligaments, and a membranous expansion, which is attache laterally to suffraginis and os coronæ, and to the perforatus the middle line.

Ulnaris Accessorius *vel* Flexor Pedis Accessorius Su limis.—Situated on posterior part of fore-arm, between th external and middle flexors of the metacarpus.

Figure: Triangular, passing obliquely downwards and i wards; it has a short, thick, fleshy belly, ending in a long, fla slender tendon, which passes through a theca behind the knee.

Origin: From postero-internal part of olecranon.

Insertion: It blends with the tendon of perforans half w down cannon bone.

Relation: Externally, with skin and fascia; internally, wit flexor metacarpi internus; externally, with medius.

Action: To assist peforans.

Radialis Accessorius *vel* Flexor Pedis Accessorius Pro-
ndis.—Situated on postero-inferior part of radius.

Figure: Flat and elongated, passing downwards and inwards;
ends above the knee in a slender tendon, which travels through
theca.

Origin: From posterior part of the body of radius.

Insertion: It blends with the perforans.

Relation: Anteriorly, with radius; posteriorly, with perfo-
tus and perforans.

Action: To assist perforans.

Below the knee are four slender muscles, the Lumbrici.—
hey are situated behind the cannon bone; a pair right and
ft of the suspensory ligament, anteriorly and posteriorly on
ther side.

Figure: The anterior are most distinct, ending in thread-like
ndons.

Origin: Below knee, between suspensory ligament, and small
lint bones, covered by fibrous tissue.

Insertion: The fetlock pad. The posterior arise from the
sterior borders of suspensory ligament between it and per-
rans tendon.

Action: These muscles are inconstant, and can only serve to
tablish their analogy in the horse with the interossei, which
ites the metacarpals in many-toed animals.

Muscles of Hind Extremity

10—4 anterior and 6 posterior, grouped around tibia and
ula; they cover them, with the exception of a portion of
ner surface of tibia, and are enclosed in the fascia of the
gh, which is rendered tense by the gracilis, adductor magnus,
l triceps abductor femoris; the fascia is attached to the inner
face of tibia, apex of os calcis, and to a strong fibrous band
ow the tendon of gastrocnemii above the hock, sometimes
led the tibial ligament.

Anterior Tibial Region.

Extensor pedis, flexor metatarsi, peroneus, and flexor meta tarsi parvus.

Extensor Pedis.— Situated on the anterior surface of leg.

Figure: It extends downwards and backwards, about th inferior fourth of tibia. A little above the hock, the fusifor belly terminates in a long flat tendon, which passes over th front of hock and metatarsal bone, at the middle third of whic it receives the peroneus; the united tendon now passes dow and is connected with capsular ligament of fetlock, below whic it expands, after receiving, as in fore-leg, two slips from suspe sory ligament.

Origin: From antero-inferior part of external condyle o femur by tendon common to flexor metatarsi, the digital foss and the head of tibia; by muscular fibres it passes over the hoc through a theca, and is attached to capsular ligament of fetlock and anterior surface of suffraginis and corona.

Insertion: Pyramidal process of os pedis.

Relation: Anteriorly, with fascia; internally, with flexo metatarsi; posteriorly, with peroneus and bones.

Action: To extend foot and flex hock.

Peroneus *vel* Extensor Pedis Lateralis.—Situated o antero-external side of leg (Pl. VIII. fig. 2, *c*, *c'*).

Figure: Penniform, consisting of a prismatic fleshy belly originating by a short, and terminating by a long tendon, whic passes through a theca on external side of hock, joining th extensor pedis below the joint.

Origin: From external condyle of femur; external later ligament of stifle; external part of head of tibia, head, and e tire length of fibula.

Insertion: Into tendon of extensor pedis.

Relation: Externally, with fascia; anteriorly, with extens pedis; posteriorly, with flexor pedis.

Action: To assist extensor pedis.

Flexor Metatarsi.—Situated on antero-internal side of leg.

Figure: Strong and thick, tendinous and fleshy. The tendinous portion consists of a fibrous cord, situated between the fleshy portion and belly of extensor pedis; the fleshy part is pyramidaloid, terminating by two tendons of insertion.

Origin: From the anterior part of superior extremity of tibia, just below and around the groove, through which the tendinous portion passes from external lateral side of tibia and capsular ligament of elbow joint. After passing through the ring formed by the tendinous portion, it bifurcates the larger division, passing directly downwards.

Insertion: Anterior surface of large metatarsal bone, along with the larger branch of tendinous part; the smaller portion runs inwards to cuneiforme parvum and head of inner splint.

Relation: Anteriorly, with extensor pedis; posteriorly, with tibius.

Action: To flex hock.

Flexor Metatarsi Parvus.—Situated in front and below the hock.

Figure: Triangular, filling up the space between the tendons of extensor pedis and peroneus.

Origin: From inferior border of anterior surface of calcis, attached to cuneiform bones and head of large metatarsal.

Insertion: Into the tendons of extensor pedis and peroneus.

Action: To prevent the tendons being jammed during flexion of the hock.

Posterior Tibial Region.

Gastrocnemius externus and internus, plantaris, popliteus, flexor pedis, and pedis accessorius.

Gastrocnemius Externus.—Situated at the back of leg.

Figure: Heart-shaped, ending in a flattened tendon; the fleshy belly is divisible into two portions, superiorly intersected by strong tendons.

Origin: By two heads—one from a ridge, extending upward from external condyle in front of supra-condyloid fossa; th other from posterior surface of femur, about its lower third, jus above intercondyloid fossa, and from internal condyle.

Insertion: Posterior part of tuberosity of os calcis, a synovi bursa being interposed between it and antero-superior part tuberosity.

Relation: Anteriorly, with gastrocnemius internus, popliteu popliteal vessels and nerves; posteriorly, with triceps abducte femoris; internally, with biceps rotator tibialis.

Action: To flex stifle, and extend hock.

Gastrocnemius Internus *vel* Flexor Pedis Perforatus.—Situated immediately below preceding (Pl. VIII. fig. 3, *b*, *b'*, *b''*

Figure: Cordiform, with fleshy origin and tendinous interse tions; about half way down the tibia, the belly is succeeded by strong tendon, united to fibrous fascia, which is fixed to the inn surface and ridge of tibia and the summit of os calcis, being co tinuous with tibial aponeurosis, and enclosing both tendons. Th tendon of internus, at first below the externus, winds round it inner side, and then surmounts it; on reaching the point of the calcis it forms a cap, giving slips of insertion to the sides of the bone; a large synovial bursa exists here, which is one of the seat of capped hock. It now descends the back of leg as the tend perforatus.

Insertion: Precisely as tendo-perforatus of anterior extremity

Relation: Posteriorly, with preceding muscles; anteriorly with tibia, popliteus, flexor pedis, and accessorius.

Action: To extend hock, flex fetlock and pastern.

Plantaris.—Situated on postero-external part of leg, to th outside of gastrocnemius externus.

Figure: Slender and rudimentary, with a long delicate te don of insertion.

Origin: From external part of the head of fibula, by fleshy fibre

Insertion: Along with tendon of gastrocnemii, on the poi of os calcis.

Relation: Externally, with fascia; internally, with gastrocnemius externus; anteriorly, with popliteus and extensor pedis.

Action: It assists the gastrocnemius externus, turning os calcis outwards.

Popliteus.—Situated at the back of tibia, just below stifle.

Figure: Triangular, fleshy, with tendinous intersections, the fibres passing obliquely inwards.

Origin: By tendon, from postero-external side of external condyle of femur, capsular ligament, and stifle joint.

Insertion: The triangular surface on supero-posterior part of the body of tibia, and upper two-thirds of its internal lateral side.

Relation: Posteriorly, with gastrocnemii; anteriorly, with tibia and popliteal vessels; externally, with flexor pedis and accessorius; internally, with fascia.

Action: To flex and rotate tibia inwards, and guard capsular ligament of stifle.

Flexor Pedis Perforans.—Situated on postero-external side of leg (Pl. VIII. fig. 3, *c*, *c'*).

Figure: Thick and cordiform, consisting of a fleshy belly and long tendon of insertion. The belly is tendinous, prismatic, and bifid, the external being the larger. The double tendon commences a little above the hock, passes through a groove on the inner side of os calcis, over posterior capsular ligament of the true hock, where it is bound down by fibrous tissue, which forms a synovial sheath, the *seat of true thorough pin.* It then ascends behind the metatarsal bone. About half way down it is joined by the metatarsal ligament, which springs from the lower bones of hock and head of metatarsal bone, which is similar to, but considerably less, than the metacarpal. Here it is joined by the tendon of accessorius, and henceforth behaves exactly as the perforans of anterior extremity.

Origin: From postero-external side of tibia and fibula, body of tibia and ligament uniting these bones.

Insertion: Semi-lunar ridge on solar surface of os pedis.

Relation: Posteriorly, with gastrocnemii and plantaris; ante-

riorly, with the tibia and fibula; internally, with flexor pedis accessorius; externally, with peroneus.

Action: To flex fetlock and foot, and to extend hock.

Flexor Pedis Accessorius *vel* Obliquus.—Situated on postero-internal part of leg, between popliteus and flexor pedis.

Figure: Fleshy, with a short tendon, which has numerous fibrous intersections.

Origin: From external tuberosity of tibia, and postero internal border of fibula, by tendon, which commences just above the hock joint, and passes through a theca on its internal aspect.

Insertion: Tendon of flexor pedis, half way down metatarsus.

Relation: Posteriorly, with gastrocnemii; anteriorly, with tibia; internally, with popliteus; externally, with flexor pedis.

Action: To assist flexor pedis.

The Lumbrici are similar to those of the fore-leg.

COMPARATIVE MYOLOGY.

The *panniculus carnosus* of the Dog and Pig varies from that of the Horse. The fleshy belly of the abdominal portion is prolonged over the buttocks and united in the mesian line of the back and loins to its fellow. The *cervical panniculus* presents two fleshy portions. The superior is the larger and thicker, springing from the scapular region. It covers the muscles of lateral aspect of the neck, passes over the parotid gland and deprimens aurem, terminating on the face, where its fibres unite with those of the opposite side.

The *psoas parvus* in the Dog is always relatively larger than the magnus. In both Dog and Pig the abdominal tissue is reduced to a single cellular aponeurosis, exercising very little pressure on the abdominal walls.

The *diaphragm* in the Ox is very large, and the pillars long. In the dromedary there exists a central bone.

The *flexor brachii* is much thinner and less tendinous in all other domestic animals. In the Dog and Pig, its insertion is quite

ifferent from that of the Horse and Ox. It gives off a small
ndinous branch, which glides over the internal surface of the
dius, guarded by a synovial bursa, and is inserted into the
ner side of ulna, near the base of olecranon. The *humeralis*
bliquus in the Dog and Pig is attached by a small tendon to the
lna, below the insertion of flexor brachii.

The *caput parvum* is long and thick in the Dog and Pig, and
he *anconeus* in the Dog.

The *extensor metacarpus magnus* in the Pig becomes inserted
nto the head of inner large metacarpal bone. In the Dog and
at, its tendons of insertion is divided into two portions, one
eing inserted into the internal, the other into the second meta-
arpal bone.

The *extensor metacarpus obliquus* in the Ox and Sheep is in-
erted into the inner side of superior extremity of metacarpus
agnus; in the Pig, to the inner small metacarpus; in the Dog
nd Cat, to the metacarpal bone of dew claw, sending a slip of
endon which glides over the third bone of the lower carpal row,
ear to a small sesamoid, blending eventually with the posterior
arpal ligament.

The *extensor pedis* in Ruminants is divided into two parallel
arts—an external, which forms the extensor common to both
gits, and an inner, proper to the internal digit. The belly of the
mmon extensor is the larger, its tendon bifurcating at the lower
rd of the metacarpus, to be inserted into the pyramidal process of
pedis. The internal tendon on reaching the fetlock expands,
d near the insertion of suspensory ligament bifurcates, becoming
tached to the anterior surface of os coronæ, and the external side
the inner pedal bone. In the Pig there are also two tendons—
e common to four digits, the other proper to the inner two.
the Dog there is but one, which divides into four tendons, one
each external digit.

The *extensor suffraginis* in the Ox is the extensor of the external
git, its tendon bifurcating; one division goes to the anterior
e of the second phalanx, the other to the outer side of the

external pedal bone. In the Dog the tendon divides into 3 which terminate on the anterior surface of the 3 external digits blending with the common extensor tendons.

The *flexor pedis perforans* in the Ox consists of two portions which unite in the middle of the metacarpus; the tendon again divides, each being separately inserted. In the Dog it is a large muscle, whose tendon divides into 4, and these terminate on the second phalanx of the four principal toes.

The *flexor pedis perforatus* in the Ox divides into 2, in the Pig into 4, in the Dog into 5 branches.

The muscles in the Dog which have no analogues in the horse are:—

Extensor pollicis is a small penniform muscle arising from supero-external surface of the radius; it passes over the carpus dividing into two branches—one for the thumb, the other for the index finger. The rudimentary *supinator longus* arises from the epitrochlea of humerus with extensor metacarpus, and becomes aponeurotic at the carpus; it turns the foot upwards, or supinates it. *Supinator parvus*, a triangular muscle, arising from a fossa on the outside of the trochlea of humerus and external lateral ligament of elbow; it is inserted into the antero-internal face of radius. The short thick *pronator teres*, situated at the supero internal aspect of fore-arm, arises from a small tubercle on epicondyle, and is inserted on the inner side of the upper end of radius by aponeurosis; it pronates arm and foot, or turns it downwards. The pronator is a square muscle, situated behind and passing from the radius to ulna. There are several small muscles between the claws—the short *abductor*, the *adductor*, and *flexor of dew claw*, the *adductor of first* and *extensor of outer claw lumbrici*, and *metacarpal interossei*. The *extensor pedis* consists of three portions, one for each claw, and are common to both with 4 separate tendons of insertion. The *peroneus* is double.

ORGANS OF DIGESTION.

The organs of digestion receive the alimentary matter, and bject it to specific actions, which adapt it for nutrition. Di-stion embraces the collective operations and changes which the od undergoes in the gastro-intestinal tract. The digestive gans consist of the alimentary canal and its accessories.

The *alimentary canal* is a musculo-membranous tube extend-g from mouth to anus, and lined throughout by mucous mem-ane. It consists of a series of tubes and cavities, as the outh, pharynx, œsophagus, stomach, and intestines. These e divided into 3 sections—the preparatory, or ingestive, em-acing the mouth, pharynx, and œsophagus, in which food is epared for future chemical change; the essential, or digestive, cluding stomach and some of the intestines, where the food sses through chemical change; and the egestive, or organs of ex-ulsion, by which the residue is expelled from the system. Each vision is provided with accessories—the preparatory with teeth d salivary glands, and the essential organs with the liver, ncreas, and spleen.

The functional processes of digestion are—*prehension*, the king up of food, performed by the lips in the horse, by the ngue in the ox; *mastication*, chewing, grinding, and mixing e ingesta with the fluid secretion of the salivary glands; *de-utition*, or the swallowing of prepared food, by means of the ngue, pharynx, and œsophagus; *chymification*, or conversion food in the stomach into a pultaceous chyme, by chemical nge, initiated in the gastric juice; *chylification*, or conver-n of chyle into a fluid, which occurs in duodenum, presum-y by the agency of the liver and pancreatic secretions; *ecation* or excretion, the expulsion of residual inert matter.

The Mouth, then, is an irregular vestibule at the commence-nt of the alimentary canal, containing the organs of taste and ruments of mastication, and is an oval cavity situated be-

tween the jaws, its long diameter following that of the head. is pierced by two openings—the anterior for the introduction food, the posterior, through which it passes into the pharyn It is bounded in front by the lips and anterior opening, or *fissu oris*, laterally by the cheeks; the roof is formed by the palati and superior dental arches; its floor is occupied by the tong and inferior dental arch; the posterior boundary is the *velu palati*, a membranous partition separating it from the pharyn The *mucous membrane* is pale, roseate, and continuous with th skin and faucial membrane. The *labia* or *lips*, superior an inferior, are movable fleshy curtains surrounding the anteri opening, united laterally by a commissure. They consist of ski and mucous membrane, which enclose muscles, vessels, nerve areolar tissue, fat, and some labial glands, situated betwee the mucous membrane and muscle, analogues of the salivari The mucous labial surface of the lips is bridled mesially to the gu by a doubling of membrane, constituting the *frænum labii sup rioris* and *inferioris*. The *buccæ*, or *cheeks*, are two muscul membranous walls, which close the mouth laterally; they a continuous with the lips, and consist of an external cuticula a central muscular, and an internal mucous coat, with numero small buccal glands, similar to the labial, which open on th surface of each dental arch by straight projecting pointlets, an are analogues of the parotid; a few large ones are known as th *molar glands*. On either side of the buccal membrane, near th third upper molar, is a *papilla*, in which rests the opening of th parotid. The nerves of the cheek are the fifth (sensory) an seventh (motor). The *gingivæ*, or *gums*, are reflections of th buccal membrane, and consist of dense fibrous tissue, continuou with the periosteum of the alveolar processes; they embrac without being attached to, the neck of the teeth, and are reflecte into the alveoli.

The Palate, or mouth-roof, includes the hard in front and th soft palate behind. The former is bounded antero-laterally b the superior dental arch; posteriorly, by the soft palate.

nsists of the palatine bones and palatine processes of superior axilla, covered by a dense membrane composed of the periosum and buccal membrane, and is equally divided by a longitudinal ridge corresponding to the palatine suture, which originates at the base of a small tubercle. From this raphe spring ansverse ridges, which divide the palate into a number of ches with their concavity backwards; these become smaller steriorly, and consist of a permanent corrugation of mucous embrane with submucous tissue. The palate is supplied by ood from the palatine arteries, which is returned in a veinous exus, forming an erectile tissue in the periosteum. The sensive nerves come from the superior maxillary division of the fifth. The SOFT PALATE, or *velum pendulum palati*, is the valvular rtain suspended between mouth and pharynx, and consists of ucous membrane, enclosing muscles, aponeurosis, vessels, and rves. It presents 2 surfaces and 4 borders. Its superior rder is attached to, and of the same form as, the palatine, and continuous with the hard palate, whence it passes obliquely wnwards and backwards. The lateral borders are united to e wall which separates the cavity of the mouth from the arynx. The inferior border is concave and free, resting upon d closely embracing the base of the epiglottis. From the posior extremities of this border, 2 very thin prolongations run the lateral walls of the pharynx near the beginning of œsoagus. These are the *posterior pillars* of the fauces. Between e free border of the velum pendulum palati and base of the iglottis is the posterior opening of the mouth, called the *hmus*, which in the horse, from the extreme development of e palate, is constantly shut, except during the passage of food water. It is owing to the great size of the velum pendulum ati that a horse is unable to breathe through his mouth. e anterior surface of the velum forms the posterior boundary the mouth, marked by longitudinal folds and transverse lines, ich are studded with the mouthlets of submucous glands. is surface is united laterally to the base of the tongue by

large mucous columns, the posterior pillars of the tongue, *anterior* of the fauces. Behind these are two lateral triangul spaces, the *amygdalæ*. The posterior surface of the soft pala is convex, and forms the anterior wall of the pharynx; it pr sents 3 very small longitudinal ridges, continuous with th mucous membrane of posterior nares.

The Tongue is a movable, muscular, membranous organ, situate in the floor of the mouth between the lateral portions of low jaw; being triangular, it adapts itself to the lingual canal. It the special organ of taste, and materially assists mastication an deglutition. In the Ox it is prehensile. All quadrupeds lap prehend water with the tongue. It presents a root or bas body, and apex or tip. The *base*, the widest and thickest pa is muscularly attached to the os hyoides and inferior maxilla to the epiglottis by 3 folds of mucous membrane, the *gloss epiglottic ligaments*, and to the velum palati and pharynx the anterior and posterior pillars of the fauces. The *apex* or t is free, broad in the Horse, pointed in the Ox; it is directed f wards against the inner surfaces of the lower incisors. T under surface of the tongue is connected laterally to the low jaw by the genio-hyoglossi, and by the reflection of muco membrane over the sublingual glands, to the inner surface the inferior maxillary gums. Antero-mesially, the mucous me brane folds into a *frænum linguæ* or anterior pillar. The tong consists of muscles and glands, having its free surface envelop by mucous membrane, which varies in thickness, being smoo and pellucid infero-laterally, where the ranine vein can traced. Right and left of the frænum, are the openings of t submaxillary, and on either side, between the tongue a maxilla, are the ducts of the sublingual glands. The *dorsum* convex, and marked along its middle by a *raphe*, which divi it into two lateral halves. The raphe terminates an inch fr the base in the foramen cæcum; where numerous mucous follic open, and the papillæ circumvallatæ, on each side of the rap meet as the foramina of Moragni. The mucous membra

overing the under part of the free surface is smooth, but as it asses over the borders it assumes a papillary character, and on ie dorsum it is covered with papillæ, which roughen and give a velvety appearance. In the Ox, the tongue being prehensile, papillæ are numerous; they are the essential organs of taste, and consist of three varieties: papillæ maximæ or circumvallatæ, mediæ fungiform, and minimæ, which include the conical and filiform. The *papillæ circumvallatæ*, 3 to 5, are situated at the back art of the dorsum. They are arranged in two V-shaped rows, hich run obliquely forwards and outwards, meeting in front of ramen cæcum. These papillæ rest in cup-like depressions of ucous membrane, and are inversely conical, with the apex own. The flattened base is free, and, in common with its argin, is covered with small papillæ. The deep-red *fungiform apillæ* are more numerous, and scattered irregularly over the orsum, clustering near the tip, and are attached by a narrow eck, the base being round, free, and clothed by juvenile papillæ. he *papillæ minimæ* cover the anterior two-thirds of the dorum, vanishing towards the base. They are conical or filiform, ranged similarly to the circumvallatæ, gradually losing their liquity as they reach the tip, where they are transverse. The iform are whitish, and covered by a thick epithelium, with merous minute secondary elastic papillæ, which are the true atient organs. Papillæ are processes of the corium of the ucous membrane, and are highly vascular, containing capillary ssels, the larger having numerous loops, the filiform only one ney also contain terminal nerve loops, numerous in the larger, t difficult to trace in the smaller papillæ. Like the mucous embrane, they are covered by a thick layer of squamous ithelium, which is sometimes imbricated. The special sense taste resides in the papillæ. They also possess common d tactile sensibility. The filiform papillæ serve a mechanical rpose during the action of the tongue on the food.

The mucous membrane is plentifully supplied with *glands*, mple and compound. The simple are mere follicles, secreting

mucus, which is a transparent or slightly turbid protective visc fluid. The compound are analogues of the labial and bucca and abound at the base of the tongue, near the foramen caecu and papillæ circumvallatæ, into which many of their ducts ope

The tongue is composed chiefly of muscular layers running i different directions, between which adipose tissue is interpose They are divided into extrinsic and intrinsic. The former originat beyond, and terminate on the base and under surface of the organ The *intrinsic lingual muscles* are arranged in two layers of long tudinal, with an intervening set of transverse fibres. The *lingualis superficialis* lies on the upper surface of the tongue just below th mucous membrane, running longitudinally from apex to os hy oides. The *lingualis inferioris vel propria*, also longitudinal, i arranged in a rounded band, which travels the entire floor of th tongue from base to apex, a few fibres reaching the hyoid bon The *lingualis transversus* lie between the superficial and dee layers, intersecting the extrinsic muscles. They are alway intermixed with a quantity of adipose tissue, and form the bul of the organ. These muscles alter the form of the organ. Th superficial tilt the tip upwards; the inferior curve it downwards the transverse retract or elongate it.

The posterior portion of the tongue is divided by fibrou tissue, which forms a partial septum, commencing at the hyoi bone, and losing itself in the muscles.

The blood comes from the lingual and sublingual branches o the submaxillary artery, and is returned by the lingual or ranin and sublingual veins.

The principal nerves are the lingual, or gustatory; a branc of fifth to the antero-lateral aspect,—the lingual branch of glosso pharyngeal to the base—both sensory; and the hypo-glossa motor, to the lingual muscular mass.

The Salivary glands are accessories of the mouth. The secrete saliva, which passes into the mouth, softens the food favouring mastication and deglutition. There are three primar pairs, viz., parotid, submaxillary, and sublingual.

The Parotid (Pl. XIV. fig. 1, *a*, *a*, *b*), the largest, is long and at, situated in the space bounded by the posterior border of uperior maxilla and anterior border of the wing of atlas, im-ediately below the ear, and covered by the deprimens aurem. t is related to the guttural pouch and cervical muscles. It is reyish, and, like all salivary glands, conglomerate, consisting f a number of lobes held together by dense areolar tissue, and hese again of lobules, each of which is formed by minute closed esicles, originating in the dilatation of the branched terminations f the ducts. These unite to form larger ones, and terminate in *tenо's duct*, which commences at the antero-inferior surface, ear the insertion of the sterno-maxillaris, passes along the osterior aspect of the digastricus, round the inferior jaw, with ne submaxillary artery and vein lying most posterior and along he anterior border of the masseter, and entering the mouth etween the second and third upper molar. In some animals iere is a small detached gland connected with it, the *glandula ccia parotidis*, which opens into the parotid duct as it crosses ie masseter. The canal consists of an internal mucous and an xternal contractile coat.

The Submaxillary gland is long, thin, and semicircular, the oncavity looking forwards and upwards. It lies in the intra-max-lary space, below and behind the parotid, and to the outer side f the pharynx, extending from the wing of the atlas to the body f the hyoid, where it terminates in *Wharton's duct*, which isses between the mylo-hyoid and hyo-glossus brevis, and is ntinued along the side of the jaw between the hyo-glossus ngus and sublingual gland, opening into the mouth rather in ont of the frænum linguæ, where it is protected by a thick ipilla, composed of mucous membrane, called a *barb* in cattle, ie opening being guarded by a plate of cartilage. In structure is similar to the parotid, its lobes being larger, its attachments oser, and its duct-coats thinner.

The delicate, long, flat Sublingual glands are situated under ie mucous membrane of the buccal floor, and extend from the fræ-

num as far as the spur process of the hyoid bone. In the Hor it opens by 15 or 20 ducts at the sides of the inferior den arch. These are the *ducts of Rivinius*. In the Dog they m unite to form a single canal which enters the mouth anterior and is known as the *duct of Bartholini*. The sublingual duc sometimes become obstructed, and constituting a disease call ranula. Similar in structure to the other glands, its lobes are mo loosely attached.

Other conglomerate and presumably salivary glands are t molar and buccal in the cheeks, between the membrane ar buccinator, the lingual, in the tongue, the labial, in the lips, a the staphyline in the velum palati.

Saliva, the fluid secreted by these glands, is clear, visci colourless, and slightly saline taste, with a specific gravity 1007. Alkaline when secreted, becoming acid if retained the mouth, it consists of water with about one per cent. of solid including fat, mucus, albumen, and a special animal princip ptyalin or salivin, which prevents putrefaction, and conver starchy matter into sugar. Saliva also contains alkaline an earthy salts, and a trace of sulphocyanide of potassium or sodium The secretion of the different glands varies; that of the parot is most watery, and does not gelatinise as the submaxillary do on cooling. The parotid secretes most abundantly during ma tication, and always in direct ratio to the dryness of the food; t others secrete equally, whether the aliment be dry or moi There are two physical forms of saliva: the clear watery flui which is secreted only during mastication, on the side on whic chewing goes on, hence termed the *saliva of mastication*; and t tenacious, which being secreted whenever food enters t mouth, whether masticated or not, is called the *saliva of degl tition*. A sight or thought of food will frequently induce secretion from the submaxillary and sublingual.

Teeth are hard, bony processes, planted in the alveoli of t jaws of all animals. In domestic animals, they serve as indic tions of age. Like bone, they consist of inorganic earthy sal

ith a cellular basis of organic animal matter. They are harder han bone, which contains about 66, while teeth contain 76½ er cent., of earthy salts. An average analysis of teeth is:—

Phosphate and fluate of lime, . . .	66·72
Carbonate do. . . .	7·85
Phosphate of magnesia, . . .	1·06
Other salts, ...	0·89
Chondrine.	22·90
Fat, ...	0·58
	100·00

ne material physical difference between bone and teeth is that he latter bears exposure and friction with impunity, while the ormer can endure neither without becoming diseased. Teeth ary with the animal in number, size, form, structure, position, nd attachment, but in all cases are in correlation with the food nd generic habits. Thus, in herbivora, where grinding is neces- ary, the molars partake of the millstone character, their table urfaces being rough and flat. In carnivora, where tearing is equisite, the molars are sharp pointed and serrate; in omnivora, here the food is general, the teeth are mixed. The form of eeth thus depends upon the food of the animal, and there is lways a harmony between their disposition and the conformation f correlate organs. They are not found in all animals. Birds ave none, and human teeth are the only ones that are level and ninterruptedly touch each other. In all *living* animals, except an, there is an interdental space. They are divided into simple nd compound. Simple, as in the Dog, where the entire surface s covered by a solid cap of enamel, which is alone in wear. Compound, or complex, as in the Horse, where various tissues are n wear, enamel processes dipping between them. Each tooth onsists of 3 anatomical parts: the body or *crown*, which is free f the gums, the grinding surface of which is the *table;* he *cervix* or neck, the part invested by the gums; and the fang r root, which is inserted into the socket or *alveolus*,—this is

covered by the periodontal membrane, whence the external p of the tooth receives its nourishment. The *alveoli* or alveo processes are the bony parts of the jaw in which the fangs inserted; more porous, spongy, and vascular than other bo they appear and grow with the teeth, and when these dec become absorbed. They are lined by periosteum, which reflect from the gums, at the base of the socket, again passes to t fang, forming the *periodontal membrane*, inferiorly communic ing with the *pulp cavity*, which runs up the fang centre, a contains a highly vascular and nervous organ, the *pulp*, when the dentine of the tooth grows. This pulp is enclosed in vascular membrane, and the dentine tubuli radiate from it in t aged tooth. This becomes ossified, forming the secondary *osteo-dentine*. The sensitive nerve of the pulp comes from t fifth cranial; it is owing to this extreme sensibility that toot ache is so severe when this pulp is exposed.

Three different structures enter into the formation of teeth dentine or ivory, enamel, and cementum or crusta petrosa.

Dentine constitutes the major part of the tooth, and is yellowish homogeneous substance, which consists of very minu tubuli imbedded in a dense granular intertubular matrix, a contains the bulk of the earthy matter. These tubuli commen at the pulp cavity, and radiate to the superficies of the denti where they anastomose and terminate in minute cavities, ana gous to the lacunæ of bone. They are about the $\frac{1}{40000}$th of inch in diameter, and, like the canaliculi, absorb blood plas from the vascular pulp, thus maintaining a languid but sat factory vitality.

Enamel, the second tooth material, crusts over the dentine the body, and dips into the cavities of the tables. It is knov by its peculiar whiteness. It is the hardest animal texture. a consists of hexagonal fibres, composed of about 93 per cent. earthy salts. These are enclosed in a delicate animal membra and arranged side by side with one extremity resting on t surface of the dentine, whence they are disposed in gent

Plate IX DENTITION OF HORSE.

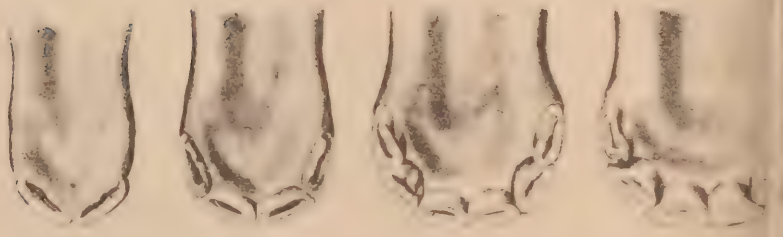

PLATE IX.

DENTITION OF HORSE.

Fig. 1.—Permanent Incisors.

A. Anterior surface.
B. Posterior ,,
C. Internal border.
D. External ,,
E. Anterior border.
F. Posterior ,,
G. Infundibulum.

Fig. 2.—Longitudinal and Transverse Sections of a Permanent Incisor.

Longitudinal.—*a a'*. Enamel, clothing the entire tooth and lining both cavities. *b b'*. Crusta petrosa. *c*. Pulp and vessels.
Transverse.—*a*. Circling enamel. *b*. Central enamel. *c*. Dentine star or osteo-dentine, which replaces tooth pulp. *d*. Dentine.

Fig. 3.—Left Figure is a Permanent Incisor, with the successive shape of its Table Surface shown as it ages and wears *up*. The Right Figures are Milk Incisors.

Fig. 4.—Canines.

A. External, somewhat rounded surface, with longitudinal shape.
B. Internal surface, capped by a conical eminence, pointed as tooth is, and separated from either surface by a deep groove.

Fig. 5.—Inferior and Superior Molars.

Showing: Cement, or external crusta petrosa; external enamel; dentine; interior enamel; internal crusta petrosa; remains of infundibulum.

Fig. 6.

A A. Pinchers, Nippers, or Central Incisors of Lower Jaw.
B B. Lateral Incisors of Lower Jaw.
C C. Corner Incisors of Lower Jaw.

Fig. 7.—Lower Jaw Nippers of a new-born Foal.

Fig. 8.—Lower Jaw of a Foal 6 months old.

Fig. 9.—Lower Jaw of a Foal 1 year old.

Fig. 10.—Lower Jaw of a Foal 2 years old.

aving lines towards the surface. They vary somewhat, but verage $\frac{1}{200}$th of an inch. No nutrient vessels or nerves have en traced into enamel, and when destroyed it is not reproduced.

Crusta petrosa or cementum, the third constituent, completely vers the external surface, and dips into the enamel plates of ie table. It is thickest towards the roots, most abundant on ie molars, and is distinguished by its brownish-yellow colour. : is the softest dental texture, closely resembling true bone in ructure, having tubuli and cells resembling the canaliculi and cunæ, and may be traversed by vascular canals analogous to ie Haversian. The proportion of earthy matter, about the ie same as in bone, is 69 per cent.

Teeth are arranged alongside of each other, so as to form ie dental arches, which open behind; these are interrupted at ch side, leaving *interdental spaces* or *diastema*. They are ivided into *incisors* or cutting, in front of the arches; *canines* tusks, in the interdental spaces; and *molars* or grinders behind. ie Horse has two sets: the *temporary* or *milk* are 24, viz., 12 cisors and 12 molars; and the *permanent* or *horse* teeth 40, z., 12 incisors, 4 canine and 24 molars. In the mare there e usually 36, the tusks being awanting or rudimentary.

	M.	C.	I.	C.	M.			
Formula of temporary teeth,	$\frac{3}{3}$	$\frac{0}{0}$	$\frac{6}{6}$	$\frac{0}{0}$	$\frac{3}{3}$	=	$\frac{12}{12}$	= 24
Formula of permanent teeth,	$\frac{6}{6}$	$\frac{1}{1}$	$\frac{6}{6}$	$\frac{1}{1}$	$\frac{6}{6}$	=	$\frac{20}{20}$	= 40

The *incisors* (Pl. IX. figs. 1, 2, 3, 6) in the horse are 12—6 in e superior, and 6 in the inferior maxilla; the upper ones are ie longest, meeting by a table surface; in rare cases they erlap, constituting a parrot mouth. The *central* pair are the rgest, the adjacent ones the middle or *lateral*, and the smallest, outer, the *corner* incisors. They present the segment of a rcle; the younger the tooth the greater the curve, which adually decreases with age, owing to the root of the tooth owing up. The anterior surface of the young incisor presents

a triangular shape, with the base at the table. Viewed latera
it is still triangular, but its apex is at the table. The table s
face is therefore oblong, being widest transversely. As it wea
it narrows laterally, but widens antero-posteriorly, until in c
age it is nearly round, the fang being in wear. In addition
the pulp cavity in the fang, there is a funnel-shaped one
the surface of young incisors, called the *infundibulum* or d
cavity, which in a tooth not in wear is about an inch deep, o
third of it wearing away each year. In a young tooth, t
cavity stretches across from side to side, is lined with cru
petrosa, and generally filled with tartar or food, which, stain
it, constitutes the mark which, being narrow and limited
extent, wears with the tooth, and ultimately vanishes. F
example, the permanent central incisors are up at three yea
the infundibulum wears away one-third each year; the anim
must, therefore, be six years of age when the mark vanishes fr
the central incisors. Sometimes the cavity is absent, its pl
being occupied by crusta petrosa; still, in the centre of the to
there is the mesial ring of enamel to guide one. In the tra
verse section of a young tooth, there are from without inwa
rings of crusta petrosa and dentine, a central ring of enam
and, finally, lining this, a ring of crusta petrosa or infundibulu
In the centre, the table in front of the cavity is broader th
that behind it, and as the tooth wears it still broadens. T
corner teeth may have no posterior tables, constituting *shell teet*
rarely they are absent in every tooth when we have a *shell mou*
(Pl. X. fig. 10). *Milk teeth* are whiter than the permanent, a
have distinct necks, the neck of the permanent being only c
ventional. Permanent teeth are convex anteriorly, the low
incisors having one, the superior two, grooves down the cen
of the body; these are filled with cement, and absent in old tee
as the grooves are limited in extent. Milk teeth are convex a
grooved posteriorly, and have their dentine stained. Ea
incisor, however old, is marked in its table surface; but t
mark of an aged tooth is quite distinct from that of a young o

In making a longitudinal section of an old incisor, what was the pulp cavity is found filled, the pulp disappearing when the tooth requires no further nourishment. In lieu of the pulp cavity there is a small canal, which is closed with osteodentine. As the table wears, being more porous than the dentine, this stains, constituting the mark of an old tooth, which can never be mistaken for that of a young one, as it is never oval, but almost round, and *never encircled by a ring of enamel*.

The *tusks*, or canines (Pl. IX. fig. 4), well developed in Dogs and other carnivora, are simple teeth, 4 in number, a pair above and below. They rest in the interdental spaces, the lower being nearer the incisors than the upper ones; they are permanent *ab initio*, and appear between the fourth and fifth year, sometimes a year in advance. The body is somewhat conical, the base rising at the gums. The external surface convex, and marked by several fine longitudinal parallel lines. The internal surface presents on either side a sharp ridge which separates it from the external. In the centre we have a conical eminence, with a deep depression on each side, and between it a sharp ridge. Externally, the ridges and depressions are widely separated at the base, and meet at the apex. When a tusk has been long in wear, the ridges disappear, and the internal surface becomes nearly smooth. The neck is merely conventional. They are sanguinaries, only developed in the male.

The *molars*, or grinders (Pl. IX. fig. 5), are 12 in the temporary set, 3 on either side of each jaw; 24 in the permanent set, 6 on each side above and below; they are numbered from before backwards, and, like the incisors, those of the upper jaw are largest. In a transverse section of an upper-jaw-molar there are two distinct caps or rings of enamel. In the centre, in addition to the outer ring within the smaller caps, is the crusta petrosa; between the smaller and outer one, the dentine; and outside the large ring, the crusta petrosa. Again, in a similar section of a lower jaw tooth, there is but one ring of enamel, within which is the dentine, the crusta being on the outer side. The

three tissues are thus more elaborately mixed in the upper ja
Each molar presents a body, neck, and root. The body of t
upper is somewhat square; their external surface presents tv
grooves running from table to root, the anterior being t
deepest. The body of the lower molars are narrower, but long
than the upper ones, and have only one groove. The inner su
face of the upper molars is not so deep as the outer, while t
inner surface of the lower ones is the deepest when *in situ* a
the jaws at rest; the two are V-shaped at the base of the mout
The molar grinding surface is very irregular, owing to the
variable hardness. They present two distinct transverse em
nences and depressions, disposed regularly in the directio
The teeth rub on each other; and when a molar cuts the gum
has no distinct fang, only a square root thrice as long as th
body, but as the tooth grows, the fangs develope. A horse ma
have supplementary molars or *wolf* teeth; these are small, an
placed one on each side of the jaw anterior to the first molar
and are usually shed with the milk teeth; sometimes they remai
and should be extracted, as they are supposed to induce op
thalmia.

The *development of the teeth*, as demonstrated by the la
Professor Goodsir, consists of three distinct stages—papillar
follicular, and saccular. In early fœtal life, the lips an
tongue are developed, but there exists neither mouth, alveoli, n
teeth. About the sixth week, a horse shoe depression is form
in the mucous membrane of the gums, which is the *primiti
dental groove*, from the floor of which arise papillæ or process
corresponding numerically to, and constituting the germs of, th
milk teeth; this is the *papillary stage*. About the tenth wee
the groove deepens, the papillæ enlarge, the margins of th
grooves thicken and become prominent; prolongations or sep
pass from one side of the groove to the other, enclosing eac
papilla in an open follicle or bag; this constitutes the *follicul
stage*, which is completed about the fourteenth week. Somewh
later, the papillæ begin to assume the shape of the crowns of th

ture teeth. Small membranous processes or opercula are now veloped from the sides of the follicle, which correspond in mber and shape with the table surfaces of the teeth; thus, for e incisors, there is one on either side, the tusks have three, and e molars four or five, according to their size and situation. ne lips of the follicles, as well as the opercula, close and cohere; e grooves become obliterated, and what were open follicles are nverted into close sacs, completing the *saccular stage*. Shortly fore the closing of the follicles of the milk teeth, a lunated pression, similar to that of a finger-nail, is noticed behind, d to the inner aspect of each follicle; these become converted to *cavities of reserve*, which recede into the substance of the ms, and ultimately form sacs for the development of the permanent incisors, as well as the three anterior permanent molars. ne dental sac, as well as the enclosed papilla, continue to large. The papilla is adherent by a broad base to the bottom the sac, and becomes converted into the pulp, acquiring the mblance of the dental crowns. The contents of the sac now nsist of the vascular pulp, covered by its membrane—an ternal vascular layer, lining the sac, called the *periodontal mbrane;* and a fluid lying between the two membranes, the *amel* or *outer pulp*. The process of *calcification* now comnces. A thin lamina or cap of dentine is first developed on e outer and most prominent part of the pulp, from its coverg membrane. This continues to be formed by the substance the pulp, which gradually decreases as the dentine increases. the same moment the enamel is being deposited in crystals m its own peculiar or outer pulp. The cementum also forms *ri passu* from the calcification of the periodontal membrane ing the sac. When calcification of the dental textures is fficiently advanced, the tooth makes its way through the gums, nich are absorbed, as the crowns are forced upwards by the owth of their fangs. The septæ or divisions between the ntal sacs now ossify, and constitute the alveoli. During the owth of the teeth and formation of alveoli, the jaw deepens

and the fangs grow. The base of the pulp, by contracti forms the neck. It now elongates, and, during the ossificati of the fang, gradually becomes less, owing to the formation dentine on its outer surface, until only a small cavity is left the centre, in which rests the pulp and its vessels. In t molars, every point on the crown has a separate cap of calcific tion. These enlarge, and finally meet. In the formation of t molar fangs the pulp divides, ossification in each section pr ceeding as in a single-fanged tooth.

The permanent teeth are developed like the temporary one During the closing in of the follicles small, limited cavities reserve were formed on their inner side. These gradually elo gate, and recede into the substance of the gums. At the sa time a papilla appears in each, and opercula are developed fro the sides of the sac, which meet, as in the milk teeth, coveri the papilla, and leaving a narrow portion above, which gradual becomes obliterated. The sacs thus formed for the permanen as well as those for the milk teeth, continue to grow, the form receding into the bone below and behind the milk tooth, t sacs being separated by a bony partition. As the permane tooth continues to grow, it gradually encroaches on the mi one, presses on, and ensures absorption of its roots, the pe manent one taking its place, until the entire fang is remove when the crown of the milk tooth falls out, and the permane one is cut, appearing above the gums. The remaining pe manent teeth, the three posterior molars in each side of eith jaw, are developed thus: Behind the third molars there is portion of the dental groove unobliterated, which forms a cavi called the *posterior cavity* of *reserve*, in the fundus of which papilla appears, and undergoes the same change as the te porary teeth, forming the rudiment of the fourth molar. Fr this cavity is developed a second follicle for the fifth, and fr this the follicle of the sixth or last molar.

Plate X

DENTITION OF HORSE.

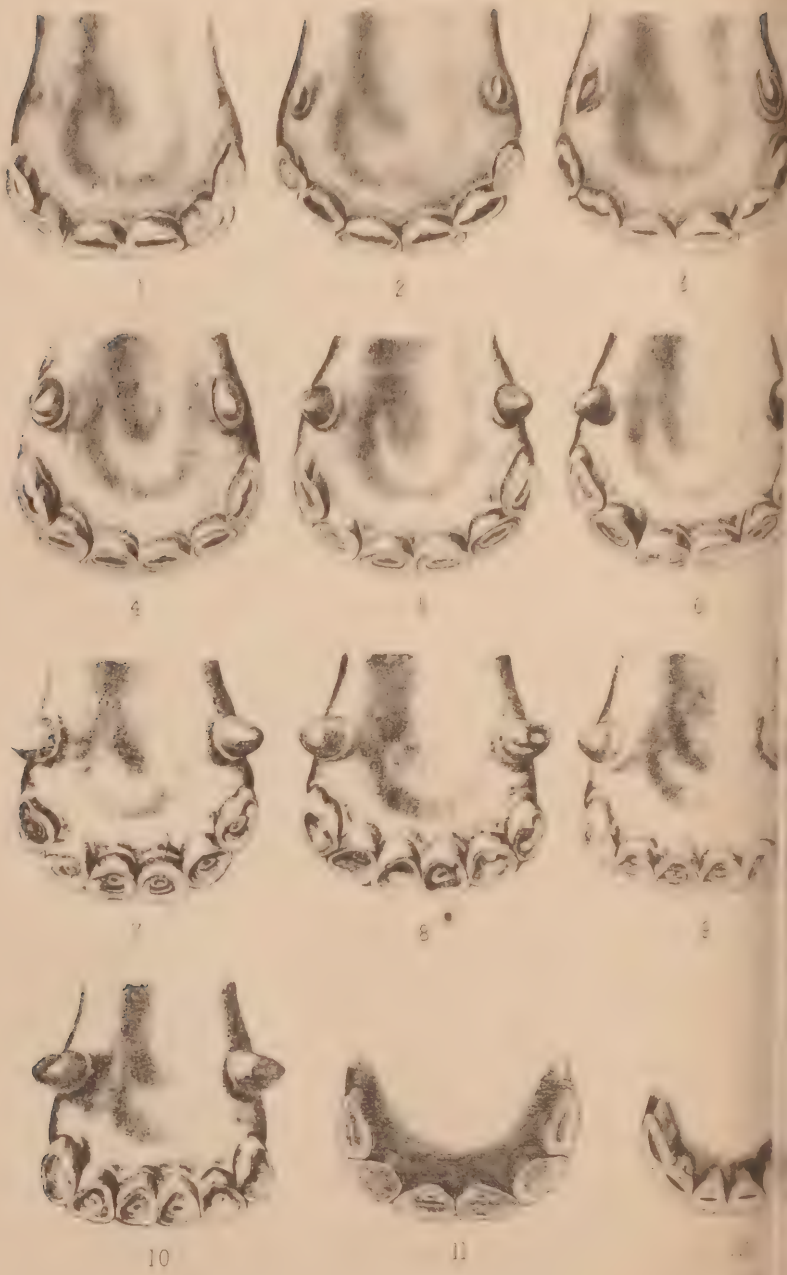

PLATE X.

DENTITION OF HORSE.

Fig. 1.—Represents the Lower Jaw of a Horse at 3 years of age.

Fig. 2.	,,	,,	4	,,
Fig. 3.	,,	,,	5	,,
Fig. 4.	,,	,,	6	,,
Fig. 5.	,,	,,	7	,,
Fig. 6.	,,	,,	8	,,
Fig. 7.	,,	,,	10	,,
Fig. 8.	,,	,,	12	,,
Fig. 9.	,,	,,	14	,,
Fig. 10.	,,	,,	16	,,

Fig. 11.—Is a Shell Mouth, in which the infundibulum in the incisors persists abnormally long, thus presenting a *false appearance* of youth.

Fig. 12.—Is a Bishoped Mouth, the false counter mark being an attempt to give a fictitious appearance of youth to an aged horse. It is always found *anterior* to the remains of the ossified tooth pulp or osteo-dentine of the fang, and *never* has a ring of enamel circling it.

Teeth as Age Indicators.

'l. IX. figs. 7, 8, 9, 10; Pl. X. figs. 1, 2, 3, 4, 5, 6, 7, 8, 9, 10).

The protrusion of the milk teeth is by no means regular, but precise knowledge of the moment of their appearance is of tle importance. The foal is usually dropped with 12 molars, on either side of each jaw, and sometimes with 4 incisors, the ntral pair above and below. Their appearance is, however, onstant, varying from birth to fourteen days thereafter, pending somewhat upon the period of gestation in the mare. out six, or from that to nine weeks, the second pair, or the eral incisors, are cut. At nine months the third pair, or rner incisors, appear above the gums. Their edges do not, wever, meet until twelve months. At one year old, then, e foal has all its temporary incisors up, and their tables in position. About this period the first 4 permanent molars, ., the fourth above and below on either side, come up. Thus, *addition to all the temporary incisors, a yearling foal has* 16 *olars, consisting of* 12 *milk and* 4 *permanent ones.* At this e, or somewhat later, care must be taken not to mistake the outh for a five-year-old, especially in small rough ponies, the rfaces of whose incisors certainly resemble each other; but mistake can possibly occur, as the deciduous teeth are milky hite, have distinct necks, and no groove on their anterior rface.

At eighteen months, preparations are made for cutting the cond 4 permanent molars, the fifth on either side of each jaw. distinct swelling appears on the gum at the back of the jaw, d at one year and nine months, or, at the latest, at two years, ey are up and meet. At *two years, then, the foal has* 12 *milk isors and* 20 *molars, viz.*, 12 *milk and* 8 *permanent.* At this e, too, the date cavities are worn out of the tables of the wer incisors. At two years and six months the gums enosing the central milk incisors get full and round. About ree months later, the permanent teeth may be seen protruding

through the gums, and when the animal is three years old th
are up and in wear.

Just before the foal is three years old, preparations are made f
shedding the first and second temporary molars, and replacin
them by permanent ones, which are up at three years. *In a thr
year-old mouth we have, then,* 2 *permanent incisors, the centr
ones, and* 8 *permanent molars, Nos.* 1, 2, 4, 5, *on either si
of each jaw, along with* 4 *temporary incisors above and* 4 *belo
and* 4 *temporary molars, one on each side of either jaw.* A
three and a half years the lateral incisors change, as the centr
ones did, and the permanent lateral incisors appear, but the
edges are not opposed until the animal is four years old. A
four years, also, the third and last temporary molars are replac
by permanent ones. At the same time, the sixth and fin
molars of either jaw are cut, so that *at four years of age the fo
has in each jaw* 4 *permanent incisors—the central and later
above and below; and all* (*i.e.*, 6 on either side of each ja
the permanent molars up.

The *tushes* generally appear at *four years*, but they may e
sooner than four, or as late as five years. When the foal is *fo
and a half years old*, the same change ensues in the corner mi
as took place in the central incisors at two and a half years, a
the lateral ones at three and a half. About four years a
nine months, the *corner or shell permanent teeth* appear, a
at five years they are up and level with the others, with t
exception of their inner shells, which are not in wear.
change in the name of the animal now takes place: the co
having a full mouth of permanent teeth, becomes a horse, a
the filly a mare. *At six years, the inner tables of the corner i
cisors are up and in wear*, and the infundibulum or mark is wo
out of the central incisors of the lower jaw; *after this a thorough
bred or race-horse is aged.* At *seven years*, the *mark is effac
from the lateral incisors of the lower jaw*, the tushes also becom
rounded at their apex, and lose their posterior ridges; t
upper corner teeth at seven sometimes appear notched, in co

quence of their being broader than the lower ones, the outer rner of the uppers not being in wear. At *eight years, all of the rks are obliterated from the lower incisors*, and they are on a vel. Their forms now change; the tables have become oval stead of oblong, the cavity has been replaced by a long transrse ridge or eminence of enamel, which is the termination of e infundibulum. Special changes take place in the shape of e gums, on which some lay great stress. At five, the gums circling the tooth neck are circular; at six, less so; at seven, trigular; and at eight, square. Above eight, all horses are (racers cepted) said to be past the mark of the mouth, or aged. fter this period, considerable experience is required even to zard an opinion respecting the age. There are various ethods of arriving at the conclusion. Some rely on the upper cisors, maintaining that the mark is worn out of the upper ntral incisors at nine, out of the lateral pair at ten, and out of e corner ones at eleven years, while others aver that the rks of each upper incisor takes two years to wear out; thus, nen worn out of the central pair the animal is ten, out of the teral ones twelve, and when the mark is gone from all the per incisors, fourteen years old. The simple fact of there ing room for three years' difference of opinion regarding the earing out of the marks in the upper corner incisors, shows that tle reliance can be placed on either. Girard adopts, as a guide, e varying shape of the table surface of the lower incisors. At st oblong transversely from the centre to the corners, they ange to oval, round, and finally become triangular. He notes at, at eight years, the central lower incisors become oval, the teral pair at nine, and the corner ones at ten, the transverse minence of enamel lessening and approaching the posterior surce. At ten, also, the central teeth have assumed a roundish rm, the lateral ones at eleven, the corner pair at twelve, the ntral enamel having entirely disappeared at thirteen, the sides the central incisors are getting long, and, at fourteen, equal to eir anterior border, and are, consequently, triangular. At

fifteen, the sides of the lateral incisors lengthen, and at sixte their tables are triangular. At sixteen, the corner incisors becoming, and at seventeen, are quite, triangular. After th the teeth steadily flatten, converge, and pass straighter from t gums; owing to what was the fang coming into wear, the nec of aged teeth are frequently enveloped in tartar. In *crib-bite* the outer margin of the upper incisors are more worn than other horses.

The Tonsils in the Horse are imperfectly developed. Betwe the velum palati and the base of the tongue there are two l teral spaces of a triangular form, and in each of these spac there is a pit or excavation pierced by numerous opening which are the mouths of the ducts of many small glan crowded together behind the excavation. This pit is a tr tonsilar cavity, and represents the tonsil in man and car vorous animals, which is a more highly developed structu Nothing is known of the nature and functions of the muc like fluid secreted by these glands; but in the Horse, where th anatomical structure is so simple, it probably serves to lubrica the fauces.

The Pharynx is a musculo-membranous cavity common to th digestive and respiratory organs. Cylindrical in the Horse, extends obliquely downwards and backwards, and lies behi the velum palati, which separates it from the mouth, forming i anterior wall. It is attached superiorly to the base of th cranium by muscles and aponeurosis, infero-laterally to th larynx, and infero-posteriorly is continuous with the œsophagu It communicates with other cavities by 7 openings, viz., th *posterior nares* superiorly; posteriorly, on either side, with th slit-like openings of the *Eustachian tubes*, which lead to th guttural pouches, and are guarded by a cartilaginous valve; a teriorly, below the posterior nares, is the *isthmus of the fauc* leading into the mouth, and, unless during deglutition, clos by the *velum palati;* inferiorly, behind the tongue root, is th *cordiform opening of the larynx*, and behind this the *œ*

Plate XIV

DIGESTIVE ORGANS

PLATE XIV.

DIGESTIVE ORGANS.

Fig. 1.—Left Side of Head with the Superficial Salivary Glands.

a a. Parotid gland. *b b.* Its excretory duct. *c.* Superior buccal gland. *d.* Inferior buccal gland.

Fig. 2.—Portion of Horse's Stomach Inflated and Dried, with the Pyloric Opening.

a. Pyloric opening. *b.* Ring-like valve.

Fig. 3.—Inflated Stomach of Horse seen from the side.

a. Left sack. *b.* Right sack. *c.* Great curvature. *d.* Small curvature. *e.* Œsophagus. *f.* Duodenum.

Fig. 4.—Cæcum and Colon of Horse, Inflated.

a. Cæcum. *b c.* Its muscular bands. *d.* Posterior end of ileum. *e e' f f'.* Colon. *e.* Inferior transverse colon. *e'.* Descending colon. *f.* Ascending colon. *f'.* Superior transverse colon. *g.* Posterior or pelvic curvature. *h.* Anterior or gastric curvature. ➳ Sign which indicates course of the contents in the intestine.

Fig. 5.—Portion of Horse's Stomach, Inflated and Dried, with the Œsophageal Opening.

a. Opening of the œsophagus. *b.* Semi-lunar valve.

haryngis. The pharynx is composed of 3 coats—an external, muscular, a central, elastic and aponeurotic, with an internal, mucous.

The ŒSOPHAGUS, or gullet, is a long musculo-membranous cylindrical canal, passing from the pharynx to the stomach, through which the food travels. Leaving the pharynx, it ascends the neck behind the trachea, then inclines to the left, entering the thorax along with it; it soon passes to the upper side of the trachea, surmounts the base of the heart, leads through the posterior mediastinum, penetrates the diaphragm in the foramen sinistrum, gains the abdominal cavity, and terminates on the cardiac orifice of the stomach. It is divided into cervical and thoracic portions, narrowest at its origin behind the cricoid cartilage; it is of uniform size until it reaches the diaphragm, where it again constricts, thence it gradually widens to its insertion. It consists of two tunics, an internal mucous and an external muscular, which are united by areolar tissue. The mucous coat is continuous with the pharynx and stomach, but is paler in colour, and clothed with squamous epithelium; it presents numerous longitudinal folds, which allow dilatation, and is studded with minute papillæ and œsophageal glands, which abound posteriorly. The muscular coat consists of external longitudinal, and internal spiral or circular fibres. The cervical and anterior thoracic muscular coat is striated and voluntary, the remainder pale, smooth, and involuntary. The longitudinal layer commences by three fasciculi, one in front and one on either side, which unite to form a continuous layer. The circular fibres originate at the inferior constrictors. Inferiorly, both sets of fibres cross and pass to the stomach. The œsophagus is supplied by the carotid, superiorly, and the œsophageal arteries, posteriorly; its nerves come from the pneumo-gastric. In the Ox the muscular coat of the œsophagus is thicker than in the HORSE, and the inner fibres are doubly oblique in the HORSE; peristalsis is alone requisite; in the Ox peristaltic and anti-peristaltic action ensues. Food grasped by the nippers,

torn by the laniaries, and crushed by the molars, gathers as bolus at the root of the tongue, which in contracting abu against the posterior roof of the mouth, and forces the pel through the isthmus faucium into the pharynx. At one and t same moment, the velum pendulum palati recedes backwar and upwards, to guard the posterior nares, the vocal cords co tract the glottis, while the food forces down the epiglottis up arytenoid cartilages, effectually precluding it from the laryn finally, the pharynx advances upwards and grasps the pabulu The passage of food into the larynx is purely voluntary; but soon as it enters the œsophagus, the act of deglutition is entire involuntary, the mass travelling home by a vermicular or peri taltic motion, the circular muscular girdles contracting with su cessive regularity.

The ABDOMEN, or belly, is a large and somewhat oval cavit bounded superiorly by the muscles of the sublumbar region; i fero-laterally by the abdominal muscles; anteriorly, by th diaphragm; and posteriorly, continuous with the pelvic basi In it are contained the essential organs of digestion, viz., t *stomach* and *intestines*, with their *accessories*. It is lined l the *serous peritoneum*, which is reflected over the viscera, an divided by two imaginary transverse lines into three prima artificial regions—anterior, middle, and posterior. The first li is drawn from the cartilage of the last false rib on one side, that of the other; the second unites the anterior spinous pr cesses of either ilium. These divide the cavity into three regio —the anterior or epigastric, middle or umbilical, and posteri or hypogastric. These primaries are each subdivided into thr regions, by two longitudinal lines, extending from both sides the ensiform cartilage to both sides of the pubis, thus completi the division, which is tabulated.

Division.	Region.		
Anterior.	Right hypochondriac.	Epigastric, or Scrobiculus cordis or pit of the stomach.	Left hypochondriac.
Middle.	Right lumbar.	Umbilical.	Left lumbar.
Posterior.	Right iliac.	Hypogastric or pubic.	Left iliac.

The Stomach (Pl. XIV. figs. 2, 3, 5) is the dilatation of the imentary canal between the œsophagus and small intestines, in hich conversion of the food into chyme by the action of the astric juice takes place. In the Horse it is small in proportion the size of the animal, and rests in the left hypochondriac gion, stretching when full into the epigastric; when distended, resembles a bent tube with two lateral dilatations divided by e central constriction into a *left* or *cardiac*, and a *right* or *loric* portion. The former is the larger, and called the *greater l-de-sac* or *fundus;* the right portion is the *lesser cul-de-sac* or *trum pylori*. It has one opening at the left, for the reception the œsophagus, through which the food enters—this is the *rdiac orifice;* and another at the right, which communicates ith the duodenum—*pyloric orifice*. Between the pyloric orifice id duodenum, is a constriction, the *pyloric ring*. Between the o openings there are two *curvatures;* the superior or lesser is ncave, the inferior or greater convex. The stomach has two rfaces—an *anterior* and *posterior*. The anterior is related to e diaphragm and liver, the posterior to the small intestines and aphragmatic flexure of the colon. The spleen lies along the ferior border of its greater cul-de-sac, with its base towards the ft aspect of the stomach, where it is also connected with the left tremity of the pancreas, and, indirectly, with the left kidney; e lesser curvature is related to the right lobe of liver and intes- nes. The walls are composed of three tunics—an external

serous, middle muscular, and internal mucous. The *serous coat* from the peritoneum, is smooth and elastic, adhering intimately to the muscular, except at its lesser curvature, where, strengthened by doubling of yellow elastic tissue, it forms two ligaments the *gastro-hepatic*. Between these folds a space is left, which is filled with nervous ganglia, fat, blood-vessels, and lymphatics. Around the cardiac orifice it forms a circular fold, the *coronary ligament*, which passes to the diaphragm, forming the *gastro-phrenic ligament*. The peritoneal coat passes from the greater curvature to the spleen, as the *gastro-splenic;* from the pyloric orifice to the duodenum, as the *gastro-colic;* and from the lesser curvature to the liver, as the *gastro-hepatic omentum*. In the *muscular coat* are three sets of fibres—external longitudinal, middle circular, and internal oblique. The longitudinal are continuous with those of the œsophagus, and radiate from the cardiac orifice; they abound at the curvatures, and are thinly scattered over the surfaces; towards the pyloric end they again converge and form a uniform layer, which is continuous with that of the duodenum. The middle layer consists of circular fibres, which cover the entire organ near the pylorus; they thicken into a circular ring, which projects into the orifice, and forms with a doubling of the mucous membrane a sphincter, called the *pyloric valve*, which by contraction prevents crude food passing into the intestines. The inner layer is composed of oblique fibres continuous with the circular œsophageal ones; these abound at the cardia, descend obliquely over either surface and disappear towards the central constriction. These fibres are involuntary; the longitudinal ones, by contracting, enable the stomach to dilate; the circular induces the vermicular motion, while the oblique carry this vermiculation forwards or backwards, thus producing a churning motion, which brings each portion of the food into contact with the digestive surface. The *internal mucous tunic* is divided into right and left portions. The former is the cuticular coat, continuous with the mucous membrane of the œsophagus, which it resembles; it is

overed by a thick layer of epithelium, terminating in an abrupt lentated margin; when empty, the stomach is thrown into folds, which disappear as it dilates. At the cardiac orifice, there is no rue valve—merely a temporary spiral folding of mucous membrane. The latter, the villous or true digestive coat, is red, soft, ulpy, longitudinally wrinkled, vascular, and velvety-looking. When examined with a lens, it appears honey-combed, and overed by small shallow polygonal depressions or *alveoli*, separated from each other by projecting intervals, which near the pylorus appear like villi. Into these alveoli the *gastric follicles* pen; they lie in the sub-mucous tissue, perpendicular to the urface with their deep end closed; at the pyloric end some of hese follicles terminate in dilated sacs, or divide into two or nore tubes. They consist of a basement membrane, lined by olumnar epithelium; some of them secrete gastric juice, others mucous: the latter are lined throughout with epithelium, while he gastric juice follicles have their lower part filled with nucleated cells and granules. The villous coat is also covered with umerous simple or *lenticular follicles*, which are umbilicated ke cowpox vesicles. The supply-arteries arise from the cœliac xis, and are the two branches of the gastric—the left gastro-piploic and branchlets, from the splenic, and the right gastro-piploic and pyloric, from the hepatic; the blood is returned by atellite veins, which terminate in the venæ portæ. The nerves re from the pneumo-gastric and solar plexus of the sympathetic.

The Intestines are divided into *small* and *large*, the small eing that portion of the canal where the fluids of the pancreas nd liver mix with the chyme, and where the chyle is formed nd fitted for absorption by the lacteal vessels.

The *small intestines* commence at the pylorus, and terminate t the cæcum. They consist of a cylindrical convoluted tube, ttle more than an inch in diameter, gradually diminishing roughout, and measure about 71½ feet in length. They pre-nt two curvatures, the greater one, convex and free, the lesser, oncave and attached, occupying the central region of the ab-

domen. They are surrounded by the large intestines, an suspended from the spine by the mesentery; they are arb trarily divided into duodenum, jejunum, and ileum. The *du denum*, continuous with the pylorus, is the shortest, most cap cious, and vascular. It is the only attached portion of th gut. In the HORSE it measures about 21 inches, presenting dilatation at its origin resembling a miniature stomach, with it curvatures reversed. On leaving the pylorus it dilates, runs for wards, then bluntly backwards, forming an elbow. It nov crosses from right to left, and becomes attached to the vertebral terminating at the anterior mesenteric artery in the jejunum The first portion is free, the latter firmly fixed. It has no mes entery, and only a partial covering of peritoneum. The *jeju num* follows duodenum, and includes $\frac{2}{3}$ths of the remainder o the small intestines, the *ileum* occupying $\frac{1}{3}$ths; both are floating and supported by the mesentery. The jejunum occupies par of the umbilical and left iliac regions, the ileum part of th umbilical, right iliac, and hypogastric regions, terminating i the right iliac region in the large intestine.

The walls of the small intestines, in common with all hollow viscera of the abdomen, consist of an external serous or middl muscular, and an internal mucous. The latter two are joine by areolar tissue, which is sometimes regarded as a submucou coat. The serous coat envelopes the small intestines, except a its attached border, where it is reflected from, and becomes con tinuous with the mesentery. The muscular coat consists of tw layers of fibres—an outer longitudinal, which is very thin, esp cially at the attached border, and an inner circular, which i thicker, and rings the gut; both are pale, and involuntary. Th mucous coat, soft, spongy, red, and vascular, covered by numer ous minute villi and follicular openings, the whole being clothe by a transparent columnar epithelium. It is thrown into tem porary folds, which disappear when dilated in man. These ar known as *valvulæ conniventes.*

There are three kinds of glands in the small intestines

Brunner's, which are numerous, small, round, compound glands, resembling the salivary, are arranged in groups in the duodenum, abounding at its pyloric end. The *crypts* or *follicles of Lieberkühn*, small, resemble the tubuli of the stomach, and are found throughout the smaller intestines, between the villi and around the larger glands. The *glands* or *patches of Peyer* are oval or circular groups of solitary glands, forming agminated glands, and are found in the jejunum and ileum. They are most numerous near the termination of the ileum. Each gland is a simple vesicular ductless sac, containing an opaque white secretion, and each patch is ringed by the crypts of Lieberkühn. Singular vesicular sacs, similar to those forming Peyer's patches, called *solitary glands*, are scattered throughout the intestines, and surrounded by Lieberkühn's crypts. The surfaces of the solitary glands are villous.

Villi are small, conical, vascular processes, closely packed over the mucous surface, and consist of a net-work of capillaries and lacteals, fine muscular fibres, small granular corpuscles, and fat globules, with a mucous layer covered by columnar epithelium. The small intestines are fed by the anterior mesenteric and duodenal branch of the hepatic arteries, and is returned by the satellite veins to the portal system. The nerves are from the solar plexus.

The *large intestines* (Pl. XIV. fig. 4) extend from the ileum to the anus, and commence by a large cul-de-sac, the *cæcum*, blind gut, or *caput cæcum colli*, in the right iliac region, which passes obliquely downwards and forwards, terminating in the left hypochondriac region by a blind extremity. It measures about 30 inches. Its capacity is four gallons. It is somewhat conical and curved at its supero-posterior extremity, and pointed at its infero-anteriorly, presenting on its outer surface a number of circular furrows, and certain longitudinal muscular bands. Near its termination are 3, about the middle 4, of these, which are continued to the colon. These permit elongation and distension. The superior extremity is called the base or arch, and presents a con-

vex curvature looking backwards, and a concave one forwards. In the concave curvature the ileum terminates, and from it originates the large colon. It is situated in the right lumbar region and related posteriorly to the right kidney and flank. The middle part of the cæcum is related with the small intestine and cartilages of the false ribs, the apex being free, and prolonged to the sternum. It is fixed to the abdominal walls posteriorly by cellular tissue, and to the origin of the colon by a fold of peritoneum, constituting the meso cæcum. The interior of the gut presents a number of transverse ridges, corresponding to the external transverse furrows. Two orifices, placed one above the other, are found in its concave curvature; the inferior one is the terminal of the ileum, and is guarded by the ileo-cæcal valve formed by a doubling of the mucous membrane, within which is a band of muscular fibres. The superior opening is puckered and communicates with the colon. The cæcum has three coats —serous, muscular, and mucous—which are thicker than that of the small intestines, having neither Brunner's gland nor Peyer's patches. The follicles of Lieberkuhn, solitary glands, and a few scattered villi, are, however, present. Blood is supplied by cæcal branches of the anterior mesenteric artery, and returned to the venæ cavæ. The nerves are from the mesenteric plexus.

The *colon* is divided into two, which differ in volume and arrangement—the large or double colon, and the small single or floating colon. The *large colon* originates from the cæcum, and terminates near its origin in an abrupt contraction, whence arises the single colon. Taken out of the abdomen, it presents a voluminous canal, with successive dilatations and contractions; like the cæcum, it is marked throughout by longitudinal bands and transverse furrows. It measures 10 feet, and will hold 10 gallons. It is folded, forming two branches of equal length joined together by peritoneum, placed one on the other, and so disposed that the terminal end reverts to the origin. When *in situ*, these portions are redoubled, forming 4 branches, joined two and two, a right and left being above, and a right and left

elow ; the first doubling is against the origin and termination. n tracing its course, these 4 portions present themselves *seria-im*. Leaving the arch of the cæcum in the right lumbar region, passes obliquely forwards to the posterior surface of the diaphragm in the epigastric region, where it turns downwards to ne left, forming the *first flexure* or *substernal*. Here the second ortion originates. In contact with the inferior abdominal walls, runs backwards to the hypogastric region, where it is again nflected to the left, forming the *second* or *pelvic flexure*. This rms the centre of the two large branches, and is related to the ectum, bladder, and vas deferens, in the male, to the uterus and varies in the female. From this flexure, the third portion passes rwards above and to the left of the second, to which it is atached by cellular tissue and peritoneum, reaching the centre of ne diaphragm, and is inflected upwards to the right, forming the *ird* or *diaphragmatic flexure*, which is in relation with and bove the liver and stomach. From this curvature proceeds the *urth* and last part of the large colon, which is attached, as e second is, to the third by cellular tissue and peritoneum ; it asses backwards, and, at the base of the cæcum, is constricted nd continued as the single colon. The attachments of the large lon are at its origin to the cæcum by the meso-cæcum, by llular tissue to the terminal portion of pancreas and arch of ecum, and by the meso-colon, which binds together several rts. The diameter of the canal varies. Narrow as it leaves e cæcum, it soon measures 2 feet in circumference; at the lvic flexure, it diminishes to 10 inches in circumference ; at e third flexure, it again enlarges to 2 feet ; and is terminally nstricted as it forms the origin of the single colon. Exterlly, it has numerous transverse furrows and longitudinal bands. he bands vary in number. Up to the pelvic flexure, there are ; at it, only 3 ; along the narrow third portion, 1 ; at the third xure, once again 3, which persist. The internal surface rembles the cæcum. The tunics are also 3 ; the external serous, om the peritoneum, envelopes the gut, unless at its junction

with other viscera, and passes from the lumbar region to the last portion of the colon, forming the *meso-colon*. The muscular and mucous coats resemble the cæcal. Its two colic arteries supply blood, which is returned to the venæ portæ; the nerves are from the sympathetic. The *single* or *floating colon* succeeds the large colon.

The *rectum*, or straight-gut, extends in a direct line from the entrance of the pelvic cavity to the anus, and resembles the single colon, only its walls are thicker, and more dilatable. It is related superiorly with the floor of the sacrum; inferiorly, with the bladder, vasa deferentia, vesicula seminalis, Cowper's glands and prostate in the horse; in the mare, with the vagina and uterus, laterally, with the walls of the pelvic basin. Anteriorly it is fixed to the colon by a continuation of the colic mesentery called the *meso-rectum*, to the sacrum by a circular fold of peritoneum and the suspensory ligaments of the penis, which, uniting at the posterior extremity, ring the rectum; finally, by two triangular fasciculi of pale muscular fibres, which pass up above the anus, and are inserted into the inferior surface of the coccyx between its depressor muscles. The serous coat is a reflection of the peritoneum; the muscular is very strong, consisting of longitudinal spiral-like bands, with circular fibres below them. The mucous coat is similar to that of the colon. Its internal surface presents a number of transverse ridges, similar to those of the cæcum and large colon. In the spaces between these ridges the dung-balls are formed. Blood comes from posterior mesenteric, and small branches of the internal iliac arteries; the nerves from the hypogastric plexus.

The large intestine is convoluted, like the small intestines, but is twice the size, and regularly crumpled by transverse folds and longitudinal bands. The latter are two—one on the greater or convex, the other on the lesser or concave curvature. It leaves the large colon to the left of the cæcum, in close relation with the termination of the ileum, and receives the insertion of the greater omentum, a fold of peritoneum de-

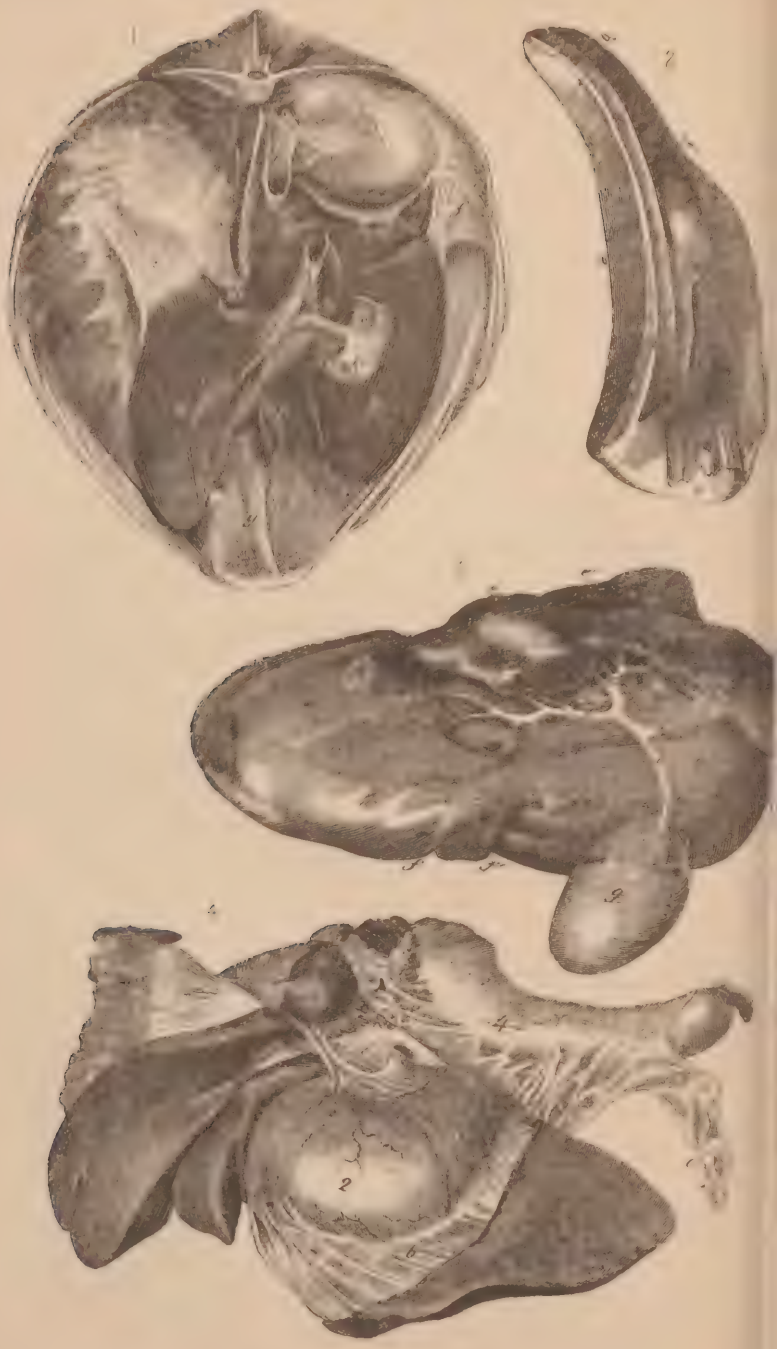

PLATE XVI.

DIGESTIVE ORGANS.

Fig. 1.—The Liver, seen in Position with the Posterior Surface of the Diaphragm.

a. Left lobe of liver. *b*. Right lobe. *c*. Middle lobe. *d*. Spigelian lobe. *e*. Left ligament of liver. *f*. Right ligament. *g*. Suspensory ligament. *h*. Bile-duct. *i*. Part of the duodenum cut out, with the excretory ducts of the liver and pancreas. *k*. Opening of small pancreatic duct. *l*. Elevation in the duodenum, containing the openings of the bile and large pancreatic ducts. *m*. Portal vein. *n*. Posterior vena cava.

Fig. 2.—The Spleen, its Inner Surface.

a. Upper end. *b*. Lower end. *c*. Inner surface. *d d*. Splenic hilus. *e*. Anterior border. *f*. Posterior border. *g*. Suspensory ligament.

Fig. 3.—Liver of an Adult Ox, Posterior Surface.

a. Left lobe. *b*. Right lobe. *c*. Spigelian lobe. *d*. Quadrate lobe. *e*. Upper border. *e'* Groove for posterior vena cava. *f*. Lower border. *f'*. Depression in which is the groove for the umbilical vessels. *g*. Gall-bladder. *h*. Hepatic ducts. *i*. Cystic duct. *k*. Common bile-duct.

Fig. 4.—The Liver, Stomach, Spleen, and Colon, with Omenta.

1. Liver. 2. Stomach. 3. Spleen. 4. End of colon, with commencement of rectum. *a*. Small or gastro-hepatic omentum. *b*. Gastro-splenic omentum. *c*. Great omentum. *c'*. Its margin, which lies free in the abdominal cavity.

ending from the left iliac region. The small colon principally cupies the left flank or lumbar region, its convolutions mixing ith those of the small intestines, and at the anterior part of the lvis, terminates in the rectum. Floating like the small intes- ies, it is suspended by the *colic mesentery*, which is larger, it resembles that of the small intestines.

The *anus* is the posterior opening of the alimentary canal. ying below the root of the tail, it forms a round projection, hich becomes less prominent as age advances. It consists of in, hairless skin externally, and of mucous membrane inter- lly. Between them, is the sphincter and retractor, terminal ores of the rectum, and fat.

Accessory Organs of Digestion.

The Liver (Pl. XVI. fig. 1) is a conglomerate gland situated in e abdomen, and reaches from the right through the epigastric to e left hypochondrium. It is the largest secreting gland in the dy, is irregularly elliptical, thick in the centre, gradually thin- ng out at the borders, and presents numerous clefts, which par- lly divide it into 3 principal and 1 accessory lobe. It has two rfaces and a circumference. The anterior surface is smooth, nvex, and cleft by a deep fissure, through which passes the sterior vena cava, and where it leaves to enter the diaphragm e the principal hepatic veins. The posterior surface is smooth, ncave, and marked with the large transverse fissure by which e venæ portæ, hepatic artery, and nerves enter, and the hepatic nals leave the liver. The fissure runs in the same direction the organ itself. The circumference has two borders, a supe- r left and an inferior right, uniting either extremity of the nd. The superior border presents from right to left the in- tion of the ligament of right lobe, the origin of the anterior sure, a deep notch for the transit of œsophagus, and the inser- n of the ligament of left lobe. The inferior border is cleft by issures, which divide the organ into 3 lobes—a right superior,

middle, and left inferior. The right lobe is medium sized, a
has on the upper part of its posterior surface a secondary py
midal lobule, the *lobulus Spigelii*, with its base in relation
the transverse fissure. The apex of this lobule is enclosed with
the folds of the right ligament, is variable in size, and is son
times called *lobulus caudatus*. The *middle lobe*, the smalle
is placed below the transverse fissure, and consists of seve
small lobules; sometimes, from its square shape, it is called t
lobulus quadratus. The middle lobe of the liver is related wi
the centre, its left lobe with the inferior part of the cordifor
tendon and fleshy periphery of the diaphragm. The right lo
contacts the superior right part of the diaphragm, its upp
border touching the right kidney; posteriorly, it is related wi
the stomach, duodenum, diaphragmatic flexure of colon, a
base of pancreas. It is attached by vessels and ligaments, t
latter are 5 in number, 4 are formed by the peritoneum, t
fifth is the *round ligament* or fibrous remains of the umbili
vein, which ascending from the umbilicus to the anterior fissu
is embedded in the folds of the broad ligament. The *corona
ligament* consists of fibres covered by peritoneum, and pass
from the superior border of the anterior fissure to the diaphrag
attached to the posterior vena cava. The broad, falciform,
suspensory ligament, consists of two adherent layers of pe
toneum, one border being attached to the anterior surface of t
middle lobe, the other to the posterior surface of the diaphrag
linea alba, and inferior abdominal walls; the round ligame
nestles in these folds. The *right lateral ligament*, in comm
with the coronary and left lateral, consists of a double layer
peritoneum, strengthened by white fibrous tissue; it stretch
from the superior border of right lobe and lobulus Spigelii
the diaphragm and walls of sublumbar region, partly covered
right kidney. The *left lateral ligament* passes from the left lo
of the liver to the left side of foramen sinistrum of the diaphrag

The *serous coat* of the liver is an expansion of the peritoneu
and is only awanting at ligamentous attachments, and at the b

several fissures, especially the transverse and longitudinal. *Glisson's capsule* is the proper fibrous capsule, strongest where the former coat is deficient. It consists of a thin fibrous membrane adherent to the serous coat and glandular substance. It invests the entire organ, and passes into several openings in the posterior transverse fissure; numerous plates from it penetrate and separate the hepatic lobules. After entering the transverse fissure, it lines the portal canals, which are drilled in the substance of the liver enveloping the branches of the portal vein, the hepatic artery, and biliary ducts, and which run in these canals. It also forms a web in which these vessels ramify, and surrounds every lobule, binding them together. It is divided into three portions—the *vaginal*, loose and abundant, lining the portal canals; the *interlobular*, which forms the capsules of the lobules, supports the ramification of the vessels, and is the bond of union with contiguous surfaces; and the *lobular*, which enters the lobules with the minute vessels, forming a cellular parenchyma.

The *hepatic substance* is variably reddish, depending upon the quantity of blood and bile in its vessels. In an animal that has died from hæmorrhage it is a bleached, yellowish grey; from general congestion, a purplish-brown or chocolate; from obstruction of biliary ducts, yellow. It is more or less marbled, and easily lacerated, the rupture being granulated, and consists of very minute lobules, varying according to position, and separated from each other by interlobular tissue, which is continuous with the surface fibrous capsule. A *lobule* is divided externally into a base and capsular surface or periphery. The base is polygonal and flat, resting upon a small branch of the hepatic vein—the *lobular*, and in its centre is the orifice of the *intra-lobular* vein. The periphery or capsular surface is developed into blunt processes, giving the lobule, when cut longitudinally, a foliated appearance. These surfaces are imperfectly isolated from the surrounding lobules by a thin layer of Glisson's capsule, and by the smaller vessels—the intervals being the interlobular spaces. Each lobule consists of numerous minute cells, biliary ductlets,

a plexus of the portal vein, the intra lobular branch of t
hepatic, a small artery, and probably minute nerves and also
ents. Hepatic cells form the bulk of each lobule, and
generally yellow and spheroidal, averaging $\frac{1}{1600}$th of an in
in diameter, and containing a *nucleus*, *nucleolus*, *granular*
vesicular matter, and *fat cells*. They are arranged in ro
radiating from the centre, and lie in a tabular net work with
the interspaces of the plexuses.

The *biliary ducts* originate within the lobules in a plex
around the hepatic cell, called the lobular biliary plexus, whi
on the capsule of the lobule forms an *interlobular plexus*. Th
gains the portal canal, constituting the vaginal branches, a
these ultimately become two canals, which leave the liver at t
transverse fissure, and unite to form the hepatic duct.

The *portal vein* enters the liver at the transverse fissure, th
divides into right and left. Each primary subdivides in t
portal canals until it is lost in the lobules, giving off *vagin*
branches, which inosculate to form a plexus, whence in the int
lobular spaces spring the *interlobular branches*. These ramify
the interlobular fissures on the capsules of the lobules, wh
they give off *lobular branches*, that penetrate the lobules, formi
an *intralobular plexus*, whence arises the intralobular branch
the hepatic vein.

The *hepatic artery* enters the liver at the transverse fissure,
company with the portal vein and biliary duct. With them
ramifies in the portal canals, giving off vaginal branches
Glisson's capsule, to the portal vein and biliary duct; from t
vaginal also arise *interlobular* branches, which pass to the c
sules of the globules, a twig or two going to the lobules, a
terminating in the capillary plexus of the portal vein.

The *hepatic vein* commences in the interior of each lobule
twiglets which converge to a centre, and from the intra-lobu
vein which leaves the lobule in the middle of its base, and ent
the sublobular vein. These unite to form large and still lar
veins, finally passing out at the anterior fissure.

The principal function of the liver is to separate a fluid called
le, which contains certain elements that act chemically upon
ie chyme, and separate the chyle. It stimulates the section of
ucous membrane, and the contractile action of muscular coat,
ually combining with the residue to form fæces; bile thus
parates certain impurities from the venous blood of the chylo-
ietic viscera, previously to its return into the general circula-
on. *Bile* is a very complex, greenish-yellow, sweetish-bitter
auseous fluid, with an alkaline reaction. It does not coagulate
y heat, and has a specific gravity of from 1026 to 1030. In
lipedes, the secretion of bile is constant, there begin no gall
ladder. It is poured out directly into the gut.

Most animals are, however, provided with a *gall-bladder*,
dged in a fissure in the posterior surface of the gland, in
hich the bile accumulates during the period of abstinence,
nd from which it passes into the intestinal canal when diges-
ion commences.

The *excretory canal*, or *ductus choledochus*, results from the
nion of the branches of the hepatic ducts in the posterior fissure
f the liver. On leaving the liver, it passes between the folds
f the gastro-hepatic omentum, and reaches the walls of the duo-
enum, whence it unites with the canal from the pancreas; both of
hich, in the horse, enter the duodenum five inches from the py-
orus, as the *ductus communis choledochus* et *pancreaticus*. The
pening of this duct is guarded by a prominent circular fold of mu-
ous membrane, which serves as a valve, preventing the entrance
f air and food from the duodenum. The ductus choledochus con-
sts of an external fibrous and an internal mucous coat, lined
ith columnar epithelium, and studded with numerous glands.

The Pancreas is a compound conglomerate gland, and resembles
ne salivary in structure and physical properties, but it is looser
nd softer, and is of a reddish cream colour. It is situated
n the epigastric and hypochondriac regions of the abdomen,
ehind the stomach and liver, and in front of the kidneys,
parated from the loins by the posterior aorta and posterior

vena cava. Its shape varies with the animal; in the horse it triangular, elongated from side to side, slightly curved upo itself, and flattened from above downwards. An oblique oper ing, the ring of the pancreas, passes from the inferior to th superior surface, through which the vena porta runs, in it passage to the liver.

The *duct of Wirsung* lies near the superior surface of th gland, and consists of numerous lobular branches which leav the right extremity, and in the Horse join the hepatic duct, t form the *ductus communis*. There is sometimes an accessor canal which enters the primary duct; in the Ox the pancreati hepatic ducts enter singly. The *pancreatic secretion* is clear an colourless, with a variable acid and alkaline secretion. It differ from saliva in containing albumen and caseine, and in having n sulpho-cyanogen. It mixes with the chyme, emulsifies the fat and thus assists in chylification. It is supplied by all th branches of the coliac axis and anterior mesenteric artery.

The Spleen is a soft, dark, reddish blue organ, situated on th left side of the great curvature of the stomach, in the left hypo chondriac region. It is a vascular, ductless gland, having n excretory canal. In the horse it is scythe-shaped, and directe obliquely downwards and forwards. It has 2 surfaces, 2 borders and 2 extremities. The surfaces are flat and lobulated; th superior one is partly covered by peritoneum and attached b cellular tissue to the aorta, coliac axis, splenic blood-vessels posterior cava, solar plexus, right kidney, and supra renal capsule The inferior surface is attached to the base of the cæcum and ter minal portion of the double colon by cellular tissue. The anterio border presents two concavities, and contacts with the duodenum and left cul-de-sac of the stomach. The posterior is convex, especi ally on the right side; about the centre, is the groove for the ven porta, before it enters the pancreatic ring. It has also a base and a apex. The inferior or external surface is somewhat flat, and con tacts with the left crus of the diaphragm. The inferior or inter nal is slightly concave, and contacts with the large colon. Th

posterior border is convex, thin, and sharp; the anterior thick, concave, and grooved by the *splenic fissure* or *hilum*, in which lie nerves and vessels: the gastro-splenic omentum is attached to this border. The base or superior extremity, large, thick, and straight, is related to the left kidney and left end of the pancreas; the suspensory ligament, formed of a double fold of peritoneum with a central layer of yellow elastic tissue, proceeds hence to the anterior border of the left kidney and abdominal walls; the apex or inferior extremity is thin, and terminates in a blunt point. The spleen is soft, elastic, tenacious, distensile, and consists of serous and fibrous coats, and tissue proper, or parenchyma. The serous coat envelopes all the organ but the hilum, and is an expansion of the peritoneum. Beneath this is the proper capsule, a thin resisting fibrous coat, formed by areolar tissue and elastic fibres. A number of white glistening bands or *trabeculæ* pass into and traverse its substance, forming a cellular net-work, in the meshes of which is contained the splenic pulp, a red-looking material, resembling grumous blood, which brightens in colour on exposure to the atmosphere. The splenic artery is very large, and gives off numerous branches, which enter the organ enclosed in sheaths formed by the fibrous capsules. These ramify and give off branchlets, which run along the trabecula, and terminate in the pulp in capillary tufts, supported by minute trabeculæ. From these tufts spring various capillaries which ingravesce, and finally leave the spleen at the hilum, where they join the splenic vein, which is likewise very large. Some of the small arteries terminate in *lacunæ*, whence veins issue, as in erectile tissue. Embedded in the spleen pulp are numerous white bodies, the *splenic vesicles* or *Malphigian corpuscles*, which cluster in groups of 6 or 8, and are attached to the smaller arteries. They consist of a transparent colourless membrane, and contain a soft, whitish semi-fluid matter, nucleated cells, and an albuminous fluid, and are supposed to be analogous to the intestinal vesicular glands. The nerves come from the solar plexus. The spleen is regarded as a diverticulum

or safety-valve, affording an internal refuge for blood when cold is applied to the superficies of the body. Some maintain it manufactures blood corpuscles—Kolliker, that it is the agent of their destruction.

The abdomen and pelvis are lined by the PERITONEUM. Like all serous membranes, it is composed of a *parietal* and *visceral* portion, which together form a complete sac, with the organs situated on its outer side. The internal surface is smooth, free, moist, and covered by scaly epithelium; it exhales a serous lubricating fluid. The external or attached surface adheres to the inner parietes of the abdomen and pelvis, but not to the centre of the diaphragm and the outer surfaces of the different viscera, the former constituting the parietal, the latter the thinner visceral portion. The serous doubling, besides covering the external surface of the viscera, forms the hepatic, splenic, and other ligaments, as well as mesenteries and omenta.

The *mesenteries* are the *mesentery proper*, attached by its superior border to the inferior part of the vertebral column, and by its inferior to the concave curvature of the small intestines; the *meso cæcum*, or the fold which travels from the iliac region to the cæcum; the *meso colon*, which unites the four portions of the large colon; and the *meso rectum*, which suspends the anterior portion of the rectum from the floor of the sacrum. The *omenta* are the great or *gastro-colic omentum*, which attaches the stomach to the colon; the *gastro-hepatic* or small omentum, which stretches from the lesser curvature of the stomach to the liver and œsophagus; and the *gastro-splenic omentum*, which passes from the greater curvature of the stomach to the hilum of the spleen.

In tracing the peritoneum, it simplifies matters to divide it into two layers—a superior one, leaving the abdominal parietes above, and an inferior one, leaving the parieties below—both travelling down the posterior part of the diaphragm, at the centre of which they surround the venæ cavæ, and pass on to the liver, forming its ligaments. They then surround the organ, one going up, the

other down the anterior surface, and round the posterior surface, meeting at the posterior fissure to form the gastro-hepatic or lesser omentum, which proceeds from the liver to the lesser curvature of the stomach. The two layers now surround the stomach, and again meet at its greater curvature, forming on the left the gastro-splenic omentum, which passes on to the hilum of, and surrounds, the spleen. On the right or fundus, the two layers form the gastro-colic or large omentum, which surrounds the colon and advances upwards to the vertebræ, forming the meso-colon. The two layers now separate; the superior passes forwards below the pancreas and aorta, and again returns to the posterior part of the diaphragm. The inferior layer, on leaving the vertebræ, descends to and envelopes the small intestines; it returns once more to the vertebral column, the double layer constituting the mesentery. It now passes backwards to the iliac region, which it again leaves to suspend the cæcum, and form the meso-cæcum, returning to the vertebræ. It reaches back to the pelvis, and again descends to form the meso-rectum and recto-vesical folds, between the bladder and rectum, finally returning along the inferior walls of the abdomen to the diaphragm. In the female, the peritoneum, after leaving the rectum, passes to the anterior surface of the vagina and uterus, forming the *broad ligaments*.

Special Variations in the Digestive Apparatus of Ruminants.— The *lips* of the Ox are thicker and more rigid, and only indirectly prehensible. A large part of the outer centre of upper lip is devoid of hair, is prolonged between the nasal openings, and constitutes the muzzle. It varies in colour with the animal, but is always moist. In health, it is covered with papillæ and foramina, which are the terminals of subcutaneous glands, which moisten the part and prevent insects from annoying. The lips of the Sheep are thin and movable agents of prehension, the superior one being fissured. The *cheeks* of the Ox and Sheep present on their inner surface, behind the commissures of the lip and opposite the first molar, numerous large soft conical papillæ,

which point backwards. A second range is placed posteriorly. The *hard palate* of the Ox is large, its posterior third smooth; the anterior two-thirds are covered with transverse bars, which do not form arches, but are denticulated, the teeth projecting backwards. Behind the pad of cartilage which replaces the upper incisors there is a letter T in the middle line with the normal directed backwards, and at each extremity of the transverse the buccal opening of Jacobson's canal.

The *tongue* of the Ox being prehensible, its muscles are well developed, and have great mobility. It is much rougher, shorter, and thicker than in the horse, and pointed at the tip. The papillæ are better developed, the filiform being very large and numerous near the apex. The circumvallatæ are arranged in two rows, one on each side of the base, and number about ten on either side. Between the lower border of the tongue and sides of the lower dental arch, are a row of conical papillæ, similar to those on the cheek. The tongue of the Sheep is very delicate.

The *soft palate* of the Ox and Sheep is not so complete and pendulous as in the horse. The isthmus faucium is always open, thus permitting them to breathe through the mouth and allowing the upward passage of food.

The *parotid* is small and red, the *submaxillary* very large and yellow. The canal of Wharton opens close to the incisors, and is guarded by a strong crenulated plate lodged in an elliptical fossa. The *sublingual* is divided into two portions, the anterior opening by a single duct close behind Wharton's, the posterior by a row of ducts as in the horse.

The Ox *has two sets of teeth*, a temporary and permanent, the former 20 in number, consisting of 8 incisors and 12 molars; the latter 32—8 incisors, and 24 molars (Pl. XI. figs. 1–16).

$$\text{Formula, } \frac{\text{M.}}{4}\ \frac{\text{C.}}{0}\ \frac{\text{I.}}{8}\ \frac{\text{C.}}{0}\ \frac{\text{M.}}{8} = \frac{12}{20} = 32.$$

The incisors are confined to the lower, being replaced in the upper jaw by a cartilaginous pad, covered by a continuation of the buccal membrane which forms a *point d'appui* for the incisors. The teeth

Plate XI

DENTITION OF OX.

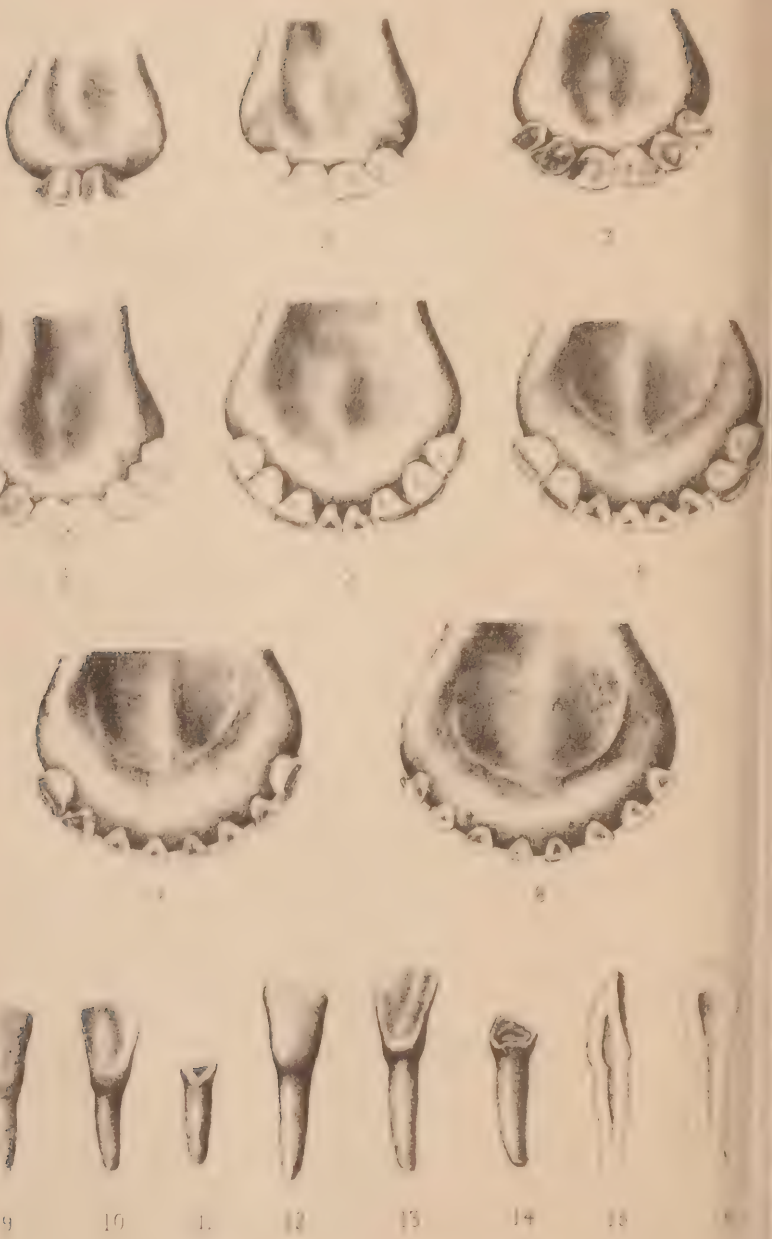

PLATE XI.

DENTITION OF OX.

Fig. 1.—Lower Jaw of a new-born Calf.
Fig. 2. ,, from 8 to 10 days.
Fig. 3. ,, ,, 15 to 20 ,,
Fig. 4. ,, ,, 20 to 25 ,,
Fig. 5. ,, ,, 7 to 8 months.
Fig. 6. ,, ,, 10 to 11 ,,
Fig. 7. ,, ,, 14 to 15 ,,
Fig. 8. ,, ,, 15 to 18 ,,
Fig. 9.—Anterior Surface of an Entire Temporary Incisor.
Fig. 10.—Posterior ,, ,, ,,
Fig. 11.—Temporary Incisor Worn Down.
Fig. 12.—Anterior Surface of a Permanent Incisor.
Fig. 13.—Posterior ,, ,, ,,
Fig. 14.—Worn Permanent Incisor.
Fig. 15.—Central Section Antero-posteriorly.
Fig. 16.—Central Bilateral Section.

constituents are the same as in the horse, but the arrangement varies. The incisors are not fixed in the alveoli, but have a degree of mobility which is frequently taken for disease. This looseness prevents cutting of the cartilaginous pad in the upper jaw. They are called the nippers, first middle or internal lateral, second middle or external lateral, and the corner incisors. Each tooth has a body and fang, and is shovel-shaped, the fang being the handle. The body is very flat, presenting 2 surfaces—inferior or external and superior or internal; and 3 borders—anterior and two lateral. The external surface is slighty convex each way, very white, and when young marked with undulating longitudinal striæ, which disappear as the tooth wears. The internal surface is smoother than the external, having a small conical eminence with its base towards the gum. The internal border is somewhat convex, the external slightly concave, giving the body of the tooth a twisted appearance. The anterior border of the cutting edge is sharp and convex towards the face of the next tooth. The neck is round and constricted; the fang is also round, conical, shorter than the incisor root of the horse, and retained in the alveolus by thick gums. In the young tooth an opening at its extremity communicates with the pulp cavity, which is prolonged into the interior of the body. The bodies only are covered with enamel, which is thickest in front. Crusta petrosa envelopes the dentine of the fangs; the temporary incisors differ from the permanent ones in being smaller, whiter, and more curved; outwards, the molars are much smaller, but placed as in the horse, 6 on each side of either jaw, the anterior 3 being deciduous.

Teeth as indicative of Age (Pl. XII. figs. 1–6).—The appearance of the incisors in a calf varies very much at birth. Sometimes none are up; usually, however, 4 or 6, and occasionally 8 are, more especially if the cow has carried a few weeks longer than usual. Any way, 8 incisors are up by the first month. The period of second dentition varies with the breed, the well bred short-horn having a full mouth of permanent incisors at a much earlier age

than a coarse bred animal. In attempting to distinguish the age of a cow or ox by its teeth, *breed must be considered*. This has given rise to tables of early and late dentition. A well bred short-horned bull may have a full mouth of broad teeth at three years, while a coarse bred animal will not have a free mouth until four or five, a good deal depending upon how the animal has been reared. To avoid confusion, *it is better to adopt an average*, from which three months should be deducted for early and three added for late dentition. At *two years old*, the *central incisors* or *nippers appear*; at *two and a half*, the *second* or *internal lateral*; at *three*, the *third* or *external lateral*; and at *three and a half*, the *corner incisors are up*; so that on an average there is *a full mouth of permanent incisors or broad teeth at four years*. After this age, it is better to depend upon the rings of the horns, reckoning one for each year after three. The calf is usually born without any molar teeth, but the 12 temporary ones are generally up and in wear in one month. The first permanent molars—that is, the fourth on either side of each jaw—appear in six, and are in wear by eight months. The second permanent molars, the fifth, are up at fifteen, and in wear by eighteen months. The third permanent molars, the sixth, are up at two years, and in wear by two years and three months. At two and a half years, the first and second temporary molars are replaced by permanent ones, and are in wear at two years and nine months. At this period, the third temporary molar is replaced by the permanent one, which is in wear by the third year. At *three* years of age, then, there is a full set of permanent molars.

The TEETH OF THE SHEEP resemble those of the ox, but are smaller and whiter (Pl. XII. figs. 7–12). They are the same in number—20 temporary and 32 permanent, 8 of each set being incisors, all of which are in the lower jaw.

$$\text{Formula, } \frac{\text{M. } 6}{6}\ \frac{\text{C. } 0}{0}\ \frac{\text{I. } 8}{8}\ \frac{\text{C. } 0}{0}\ \frac{\text{M } 6}{6} = \frac{12}{20} = 32.$$

A lamb is usually dropped without any incisor teeth. The first 4 are generally up in a week, the next 2 in ten days, the remain-

Plate XII DENTITION OF OX & SHEEP.

1

2

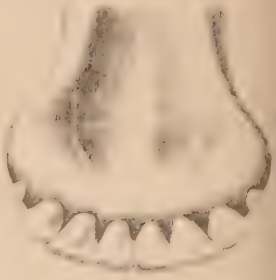

3

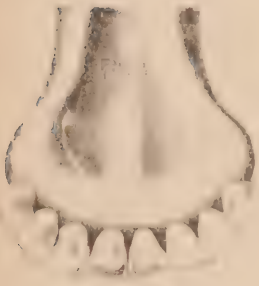

4

5

6

7

8

9

10

11



12

PLATE XII.

DENTITION OF OX AND SHEEP.

Fig. 1.—Lower Jaw of the Ox at Two Years of Age, showing the Development of Central, Permanent, and Breeding or Lateral Incisors. (The teeth are exposed from below.)

Fig. 2.—Buccal View of an Ox Jaw aged 3 years.

Fig. 3. ,, ,, 4 ,,

Fig. 4. ,, ,, 5 ,,

Fig. 5. ,, ,, 8 ,,

Fig. 6. ,, ,, 12 ,,

Fig. 7.—Buccal View of Lower Incisors in Jaw of a Lamb.

Fig. 8. ,, ,, of a Sheep aged 18 months.

Fig. 9. ,, ,, ,, 30 ,,

Fig. 10. ,, ,, ,, 4 years.

Fig. 11. ,, ,, ,, 5 ,,

Fig. 12. ,, ,, at an advanced age.

Sheep Lose all their Incisors by 7 years of age.

ing 2 by the fourth or fifth week, in most perfect development in two months or nine weeks.

Teeth as Indicative of Age.—The changes that take place in the incisors are at *one year*. The *nippers* are replaced by permanent ones, and at *fifteen months are in wear;* at *one year and a half* the *internal laterals* are replaced, and three months later are in full wear. At *two years and six months* the *external lateral pair change*, and at *two years and a half are in wear*. At *three years* the corner incisors are replaced, and in *three years and three months all the broad teeth are up and in full wear*. In coarse bred sheep the permanent teeth are generally three months later in developing. The change in the molars varies little from those of the ox, but is somewhat earlier.

The *pharynx* does not differ materially from that of the horse, the anterior opening being more perfect. The *œsophagus* differs in the arrangement of the internal muscular fibres. Instead of being circular, as in the horse, they are doubly oblique, or spiral. The fibres are red throughout, and induce both a downward passage or peristaltic, and an upward or anti-peristaltic motion.

The *stomach* of the Ox and other ruminant animals is a very complex organ (Pl. XV. fig. 1). In the horse there is only one dilatation, a tube bent on itself. In the ox there is a true digestive stomach, preceded by three dilatations. These are regarded as stomachs, and vary in size, form, and disposition of their mucous coats. The first stomach is the *rumen*, or paunch; the second, the *reticulum*, honeycomb, or king's hood; the third; the *omasum*, many-plies or many-folds; the fourth, the *abomasum* reed, or true digestive stomach. The first three have little to do with the essential process of digestion, being principally concerned in macerating and preparing the food, and are analogous to the uticular portion of the stomach of the horse. The *rumen* in the adult is very large, occupying $\frac{3}{4}$ths of the abdomen. It is situated on the left side, inclining obliquely downwards from left to right, and elongated from before backwards. It has 2 surfaces, 2 sides, and 2 extremities. The surfaces are smooth,

flat, and divided into two lateral regions by slight grooves, which deepen towards the extremities. The sides are smooth, thick and rounded; the extremities are divided by a deep fissure into two lobes, the anterior being concealed. These two fissures, continued by the grooves, divide the rumen into a right and left sac, which is most manifest in the interior. The right sac is the shortest, being covered in the major part by the peritoneal omentum; the left is prolonged beyond, and at either extremity curved on the right, receiving superiorly the insertion of the œsophagus, which is also continuous anteriorly with the second stomach. The anterior extremity is bounded by the second and third stomachs, and lies near the diaphragm; the posterior occupies the entrance of the pelvic cavity, where it contacts with the genito-urinary organs. In the female, the uterus is prolonged over this surface. The superior surface is related with the intestines; the inferior rests upon the abdominal floor; the left side, to which the spleen is united, is in contact with, and is attached by cellular tissue to the upper flank in the lumbar region, cœliac axis, and anterior mesenteric artery. The right side is related to the fourth stomach in the right hypochondriac and lumbar regions, and is surrounded by convolutions of the intestines. The interior of the paunch is divided into 4 sacs by fleshy pillars. The principal ones are the anterior and posterior, which correspond to the anterior and posterior fissures. The anterior pillar sends over the floor of the paunch a continuation backwards, and to the left this passes over the superior wall by two branches, which leave at right angles. The posterior pillar is the larger, and presents 3 branches at either extremity—a middle and two lateral. The middle branch passes forwards, separating the 2 sacs, and meets the left branch from the anterior pillar. The lateral branches diverge, describing a curve; the upper ones meet the lower, thus dividing the posterior part into two compartments quite distinct from the middle and large sacs of the rumen. The interior of the sacs are covered by numerous papillæ, which

A
B
B
C
C
D

PLATE XV.

DIGESTIVE ORGANS.

Fig. 1.—The Four Compartments of the Stomach of a Ruminant —the Inner Surface.

A. The Paunch.

a a a a. Muscular bundles arranged in columns. *b.* Papillæ. *c.* Opening of œsophagus.

B B. The Reticulum.

a a. Its cells. *b.* Canal communicating with œsophagus.

C C. The Psalterium.

a. Horny projections at opening of reticulum. *b.* Valve at the opening into abomasum. *c.* Large lamina. *d.* Medium sized lamina. *e.* Small lamina. *f.* Linear lamina.

D. Abomasum.

a a. Longitudinal folds. *b.* Opening of pylorus. *c.* Duodenum.

Fig. 2.—Stomach of Pig, Inflated.

a. Left sack. *b.* Blind sack attached to it. *c.* Right sack. *d.* Small curvature. *e.* Great curvature. *f.* Œsophageal opening. *g.* Duodenal opening.

Fig. 3.—Cæcum and Commencement of the Colon of Ox, Inflated.

a. Ileum. *b.* Cæcum. *c.* Commencement of colon.

Fig. 4.—Stomach of Dog, Inflated.

a. Left sack. *b.* Right sack. *c.* Œsophagus. *d.* Duodenum.

Fig. 5.—Stomach, Liver, Pancreas, and Duodenum of a Dog.

a a. Liver. *b.* Gall-bladder. *c c.* Hepatic ducts. *d.* Cystic duct. *e.* Common bile-duct. *f.* Pancreas. *g.* Its excretory duct.

bound on the right side, and are largest on the floor; the maller ones only secrete; the papillæ are awanting on the olumns. The gut is cuticular throughout, and covered by thick pithelium. It has two openings, both of which enter the anerior extremity of the left sac. The superior, or œsophageal, s prolonged over the small curvature of the second stomach by he œsophageal canal; the inferior large, and communicating vith the reticulum, is circumscribed laterally and below by the ree border of a partition, a kind of semilunar valve, formed y the leaning back walls of the rumen, along with the cells of he second stomach. The *rumen* consists of three coats: an external serous, a continuation of the peritoneum, which enelopes the entire organ, excepting where it contacts with umbar region and pillars of the diaphragm, the base of fissures, nd junction with other stomachs; the thick muscular middle oat is an extension from the œsophageal (circular, oblique, and ongitudinal) fibres—the latter form the pillars; the internal nucous coat is cuticular, papillated, and vascular.

The second stomach, or *reticulum*, the smallest of the four, is lightly bent upon itself, and placed transversely between the posterior surface of the diaphragm and the anterior extremity f the left sac of the rumen. It presents 2 surfaces, 2 curvatures, and 2 extremities. The anterior surface adheres to the entre of the diaphragm by cellular tissue. The posterior is nited to the anterior extremity of the rumen. The inferior onvex curvature occupies the epigastric region. The superior oncave one is partially related to the small curvature of the hird stomach. The left extremity is separated from the rumen y a fissure, in which runs the artery of the stomach. The ight forms a round cul-de-sac, and is related with the base of he fourth stomach. The internal surface of the reticulum is didided into polyhedral alveoli or cells by folds of the mucous nembrane. These folds are studded with papillæ, and serrated at neir edges; in the alveoli are secondary ones, where mucous ollicles open. The second stomach communicates with the

left sac of the rumen, the œsophagus, and third stomach. T
communication with the latter two is by the œsophageal can
which is continued through the third and fourth stomach
The reticulum has three coats—an external serous, which
velopes the anterior surface; a mesial muscular, which is ve
thin; and an internal mucous, which is reticulated, and cover
by a thick epithelium. The œsophageal canal, the continuati
of the œsophagus, commences at the cardiac orifice, or openi
of the œsophagus into the rumen, passes along the small curv
ture of the second, and enters the floor of the third stomach
a circular opening. It runs from above downwards, and fro
right to left. It is open below; arched above, forming the ro
of the second stomach. Its sides consist of two movable lips
pillars, which commence at the entrance of the gullet into th
paunch, and are attached by one border to the superior wall
the reticulum, the others being free and bulgy. These g
gradually thicker and more projecting as they reach the openi
of the third stomach. At its entrance into the first stomach
is a sort of valve, formed by the attachment of the pillars to i
walls. The mucous membrane of this canal is wrinkled on i
free surface, but in its interior resembles the gullet, bein
white, and longitudinally folded. At its opening into the thir
stomach are a number of conical papillæ. Transverse muscula
and longitudinal fibres pass from the walls of the rumen an
reticulum, which abound at the free borders, those of th
extremities blending with those of the stomach. The long
tudinal fibres, by drawing the lips of the canal together, form
channel into the third stomach. The pillars, by contractin
from their anterior extremity, and by their circular decussatio
at the opening of the third stomach, at any moment effectuall
close the openings of the first and second stomachs.

The third stomach, or *omasum*, is situated towards the right,
the anterior extremity of the right sac of the rumen. Whe
full, it is ovoid, slightly curved, and depressed from abov
downwards, presenting 2 surfaces, 2 curvatures, and 2 e

remities. The anterior surface is in relation with and attached
the diaphragm by cellular tissue, while its posterior is
verted upon the rumen. The greater or convex curvature is
rned upwards, and fixed to the posterior fissure of the liver
y a fold of peritoneum, which is continued on to the lesser
rvature of the fourth stomach, and thence to the duodenum.
he lesser curvature looks backwards, and is related to the
ticulum. The left extremity is constricted, forming the neck,
y which it communicates with the second stomach. The right
xtremity is continuous with the base of the fourth stomach,
om which it is separated by a construction similar to, but less
arked than, at the neck. The interior presents two openings,
etween which is a continuation of the œsophageal canal. One
ommunicates with the second, the other with the fourth sto-
ach. It is filled with leaves or folds of mucous membrane,
hich follow the long axis of the organ. They are unequally
eveloped, and attached by one border to the great curvature of
he stomach. The others, free and concave, are turned towards
he œsophageal canal, which runs along the floor or lesser
rvature. In the ox these leaves number from 100 to 120,
nd are large, intermediate, and small. The stomach being
void, the central plates are the largest. Between each pair of
rge we have intermediate and small plates, which extend a
mited distance only. They consist of an inner framework of
uscular fibres, clothed with mucous membrane, and studded
ith villi. Those on the free borders of the leaves are hooked
n the sides, rounded, becoming more and more so as they
scend the plates. The rounded villi secrete mucus; the bent
es hook up portions of food, and thus further trituration and
aceration. Fluid and finer pabulum pass directly into the
urth stomach. Like the other stomachs, it consists of three
ats.

The fourth true digestive stomach, or *abomasum*, is pear-
aped, curved upon itself, elongated from before backwards,
d continuous with the third about the right sac of the rumen.

canal of Jacobson opens on the front of hard palate by a sm
opening. In both these animals the tongue is much smaller
proportion than in the horse, the pig's being fringed on its edg

In the Dog the *submaxillary* gland is much larger than in t
parotid; there is also a small accessory gland with a distinct
cretory canal opening along with the canal of Wharton; t
replaces the sublingual. A large group of molar glands are a
situated under the zygomatic arch near the eye, with a sing
sub-zygomatic duct. In the pig there are two *sublingual glan*
on either side—one long and straight, situated near the angle
the jaw, and terminating in a single duct, which opens near t
submaxillary; the other, flat and four-sided, is the true su
lingual, and lies in front of the former, opening along the lo
dental arch by 8 or 10 ducts.

The Pig is one of the few existing animals which retains t
typical number and variety of *teeth*; they are 44, consisting
12 incisors, 4 canines, and 28 molars, 7 on either side of ea
jaw, the molars being 12 premolars and 16 true molars.

	T.M.	P.M.	C.	I.	C.	P.M.	T.M.	
Formula,	$\frac{3}{3}$	$\frac{4}{4}$	$\frac{1}{1}$	$\frac{6}{6}$	$\frac{1}{1}$	$\frac{4}{4}$	$\frac{3}{3}$	$= \frac{44}{44} = 44.$

The *incisors*, 6 above and below, differ from each other in a rema
able degree; the central and lateral ones in the upper jaw clos
resemble the corresponding ones in the horse, having date cavi
in their table surfaces, while the upper corner incisors clos
resemble those of the dog, having the fleur-de-lis shape; they
isolated and small in proportion to the other four. The incis
of the lower jaw are long, nearly straight, project forwards, a
somewhat resemble the rodent incisors of the hare or rat;
lower corner incisors are also isolated, but smaller than thos
the upper jaw. The *canine* teeth, temporary and permane
are well developed, specially in the male, having the charac
of true tusks. They are generally called tushes, the lower
the largest, and curve outwards, forwards, and upwards;
upper pass outwards and downwards, are three-sided, and de
tute of enamel on the posterior surface; the tushes wear oblique

Plate XIII DENTITION OF DOG

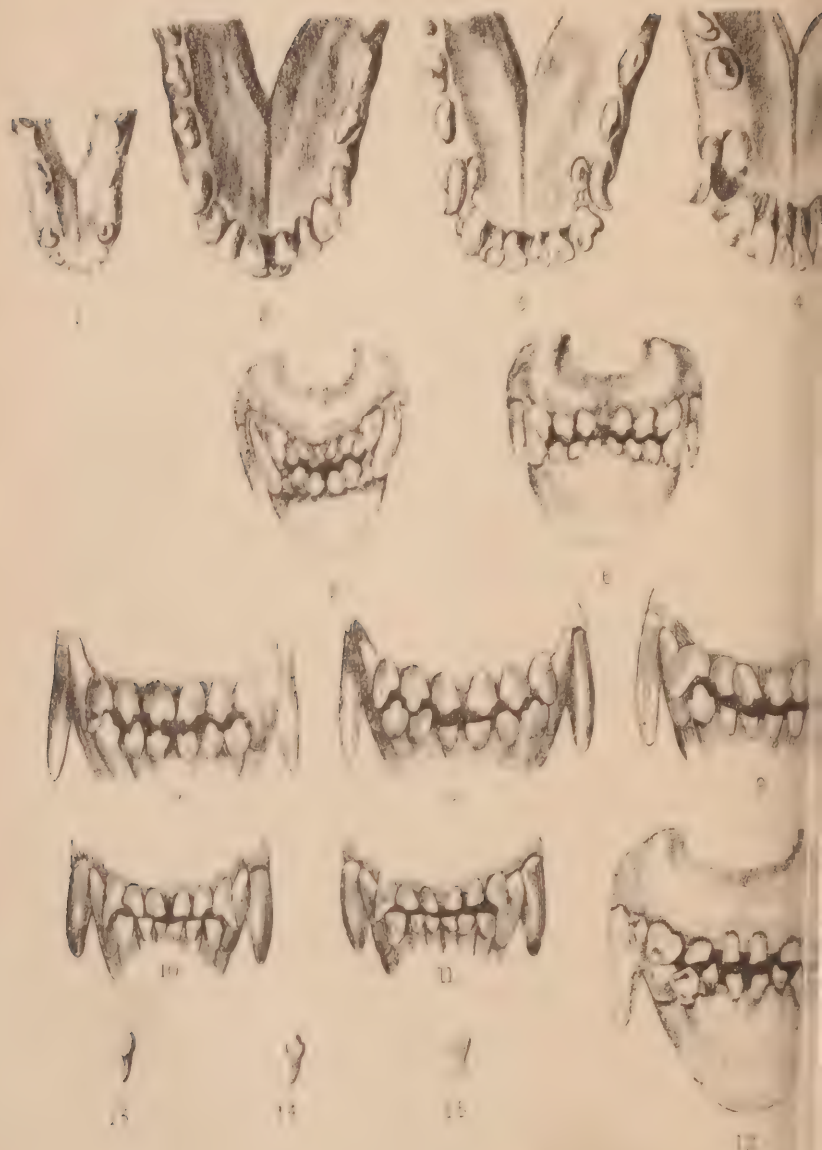

PLATE XIII.

DENTITION OF DOG.

Fig. 1.—Lower Jaw of a Puppy aged 12 days.
Fig. 2. ,, ,, ,, 4 months.
Fig. 3. ,, ,, ,, 6 ,,
Fig. 4. ,, ,, ,, 9 ,,
Fig. 5.—Upper and Lower Jaw Incisors and Canines in a Puppy under 3 months old.
Fig. 6. ,, ,, ,, above 3 months old.
Fig. 7. ,, ,, ,, of a Dog 1 year old.
Fig. 8. ,, ,, ,, ,, 2 ,,
Fig. 9. ,, ,, ,, ,, 3 ,,
Fig. 10. ,, ,, ,, ,, 4 ,,
Fig. 11. ,, ,, ,, ,, 5 ,,
Fig. 12. ,, ,, ,, over 16 ,,
Fig. 13.—Temporary Incisor.
Fig. 14.—Permanent ,,
Fig. 15. ,, ,, worn down.

rom behind upwards and forwards to a point. The molars also ary in shape, gradually increasing from the first to the last, which s large and strong; they are a *hybrid* between herbivorous nd carnivorous, somewhat resembling the human teeth. The irst on either side of each jaw is permanent, the next three leciduous, and the remaining three permanent. Those which ucceed the deciduous molars are called "premolars."

Teeth as Indicative of Age.—The Pig is born *with* 4 *incisors, the corner pair in each jaw, and* 4 *tushes.* In *a month,* he *second or central pair in each jaw are up,* and the *three temporary molars on each side above and below appear,* the first eing frequently later than the others. At *three months,* the *hird pair or lateral incisors are up,* completing the temporary ncisors; at *six months,* the *first permanent molar in each jaw,* he fifth, *comes up;* at *nine months,* the *corner incisors* and *mporary tushes are replaced by permanent ones,* and the *sixth olar in each jaw is up;* at *twelve months,* the *central permanent incisors appear,* and the *three temporary molars are eplaced by permanent ones,* which are level *three months later;* *eighteen months,* the *lateral incisors are replaced by permanent es, and the last molar is cut. At eighteen months, then, the entition of the pig is completed.*

The Dog has 42 *teeth* (Pl. XIII. figs. 1-15)—12 incisors, 4 anines, and 26 molars.

$$\text{Formula, } \frac{\text{M. } 6}{6} \; \frac{\text{C. } 1}{1} \; \frac{\text{I. } 6}{6} \; \frac{\text{C. } 1}{1} \; \frac{\text{M. } 6}{6} = \frac{42}{42} = 42.$$

he incisors are 6 in each jaw; the upper ones are the strongest, nd are known as central, lateral, and corner; the corner are e largest, the central the smallest. They are remarkable r their brilliant whiteness, and present, when not worn on eir table surfaces, three tubercles, a large central and two nall lateral ones, the tooth resembling a trefoil or fleur-de- . As the animal ages, these projections wear away. The anines, temporary and permanent, are very large, strong, conical, nd recurved outwards and backwards. The upper ones are the

largest, and have a space between them, which lodges the low ones when the mouth is shut. The molars, 12 in the upper a 14 in the lower jaw, terminate in sharp projections; the four upper and fifth lower are the largest, the former are placed l hind the latter, so that the upper meet between the lower.

Teeth as Indicative of Age.—The *milk incisors* are up by t time the *pup is a month old*. In *two months* the *central* and *later temporary incisors are replaced*, the *corner ones* and *canines* by t *fifth month*, secondary dentition being completed in *eight month* varying with the breed; large dogs teething slower than small on

The *stomach of the* Pig (Pl. XV. fig. 2) is single, and near globular; the fundus or cardiac end is very large, the œsophag terminating in it by a funnel shaped opening. About the cent of the organ, the œsophageal mucous membrane is prolonged li a hood into the stomach. It is divided by two transverse fol of mucous membrane into three portions—cardiac, pyloric, a central or œsophageal. The *stomach of the* Dog (Pl. XV. fig. is pear-shaped, the pyloric end being the stalk. The œsophag is very much dilated at the cardiac opening, the mucous me brane of the gullet forming a valve round it. It resembles t villus portion of the horse's stomach.

The *intestines of the* Pig resemble the human more than a other domestic animal. At the posterior end of the small int tines is a very large Peyer's patch. The *intestines of the* Dog short and small. The colon is somewhat larger than the small testines, and divided, as in man, into ascending, transverse, a descending; the cæcum is only a small spiral appendix. N the anus, the rectum presents on either side the duct openi of two glandular pouches, whence is secreted a strong fœtid mat

The Pig's *liver* consists of three lobes, a gall bladder, an duct opening singly. The Dog's *liver* (Pl. XV. fig. 5) is lar and provided with five lobes, a gall bladder lodged in mid lobes, and a canal which unites with a small duct from the p creas before entering the duodenum. The pancreatic duct in Pig enters singly; in the Dog the chief duct is also single.

URINARY ORGANS.

Free urinary secretion is of vast importance in the animal economy. When interrupted, death ensues by uræmia, the blood becoming poisoned by chemical products which ought to have been passed in the urine. Urine consists mainly of the surplus water of the blood, which is 93 per cent., holding in suspension about 7 per cent. of solids, the product of tissue waste. It is secreted by the kidneys, and carried off by the ureters to a special reservoir, the bladder, where it accumulates, and from which it is expelled through the urethra.

The KIDNEYS (Pl. XVII. fig. 3) are two glandular bodies, situated right and left of the vertebral column in the lumbar region of the abdomen, in contact with the crura of the diaphragm and psoas muscles. They are supported by peritoneum and cellular tissue, in which may be deposited a quantity of fat termed suet; it is very abundant in SHEEP, while in the HORSE it is rarely met with except in old animals. The kidneys are also supported by their vessels as well as by the pressure of the digestive organs; the right one is in advance of the left, lying just below the last pair of ribs, whereas the left lies just before the last rib. They somewhat resemble the heart on playing cards, the left being longer and narrower than the right. In the BEAR, the kidney is lobular, each lobule having its own blood-vessel and excretory duct. This subdivision is constant in all animals in early fœtal life; but in the majority, the surfaces of the lobules coalesce, and the organ becomes a single mass. The kidney of the Ox and SHEEP is intermediate between the lobulated of the BEAR and the solid one of the HORSE, the medullary or inner substance of the organ being united, while the cortical or outer substance is divided into lobes; from imperfect development, the kidney of the HORSE is sometimes lobulated. Each kidney in the HORSE presents two surfaces and a circumference. The surfaces are smooth, the superior one being flat, and attached to the muscles

by cellular tissue; the inferior is convex, covered by and a
tached to the peritoneum. The circumference is divided in
three borders—anterior, posterior, and internal. The two form
are convex; to the first is attached the supra-renal capsule. T
internal border is slightly concave, being deeply notched in th
centre, forming the hilum, which leads to a cavity called th
sinus. Occupying the interior of the gland are the blood-vessel
nerves, and origin of the ureter. The kidney consists of a fibro
capsule, special tissue, and pelvis. The capsule invests th
entire organ, and is reflected into the hilum lining the sides
the sinus, at the bottom of which it sheaths the vessels an
duct. It consists of thin, smooth, fibro-areolar tissue, intimate
connected with the surface of the gland by minute fibrous pr
cesses and blood vessels. On making a horizontal section of
kidney, it is found to consist of an external *vascular* or *cortica*
and an internal *tubular* or *medullary* substance. The *cortical*
situated beneath the capsule, and forms the external portion
the organ, sending prolongations inwards to the sinus which su
rounds the medullary portion. It is dark reddish-brown, du
and friable, consisting of minute blood-vessels, convolutions
the uriniferous tubes, lymphatics, and nerves, united by areol
tissue, and a transparent granular substance. On examining th
section with a lens, numerous minute red points are seen—th
Malphigian bodies or corpuscles. Each consists of capilla
blood vessels, arranged in closely-packed loops, surrounded
epithelium, and enclosed in a membranous capsule, the dilat
commencement of a uriniferous tube. The small branch of th
renal artery, entering these tufts, is the *afferent vessel* when
proceeds a minute capillary of the renal vein. The *efferen*
vessel, which leaves the tuft near the artery, joins with th
efferents from other Malphigian bodies, forming a venous plex
round the adjacent tubes, which terminate in the renal vei
The medullary substance is denser in structure, and consists
pale, conical masses—the *pyramids of Malphigii*. These ha
their bases towards the convex border and surfaces of the orga

eir apices converging to the sinus, and are composed of minute iverging uriniferous tubes, separated from each other by capil- ary vessels and intermediate substance, similar to that of the rtical substance. The termination of the pyramids in the elvis varies in different animals. In MAN, OX, and SHEEP they rminate in conical projections, papilla, or mammary processes, rrounded by folds of mucous membrane called *calyces*. In e HORSE they terminate in a continuous ridge, which projects to the pelvis. On the surface of this ridge in the HORSE, and the papilla in other animals, are numerous minute orifices, e *outlets of uriniferous tubes*, into which the lining membrane reflected. These mark the division of the kidney into lobes aring fœtal life. Within the centre of the kidney, that is, in e sinus, and nearly surrounded by the medullary substance, an irregular cavity formed by the dilatation of the ureter, e *infundibulum*, having on either side a prolongation called the *ms*, the whole constituting the *pelvis*. The urine secreted by e tubuli uriniferi is poured into the pelvis. The tubuli iniferi pass up the pyramids in straight but slightly diverging es, subdividing at very acute angles until they reach the rtical substance, where they become tortuous and anastomose ith each other, retaining the same character and diameter to eir terminations. The *straight tubes* in the medullary sub- ance are the *tubes of Bellini;* the *convoluted ones* in the rtical substance, the *tubes of Ferrein*. At the base of the ramids the straight tubes collect into small bundles or fasci- li, which are prolonged into the cortical substance as the *ramids of Ferrein*. The tubuli uriniferi terminate in dilata- ons, which form a sort of capsule, that embraces the Malphigian rpuscles in which the urine is secreted; the tubes are lined epithelium, which occupies about two-thirds of their diame- r, being ciliated in the capsules, and spheroidal in the tubes.

Blood is supplied by the renal artery, nerves from the lar plexus, which cling round the divisions of the artery. e superficial lymphatics are situated on the external surface,

and pass into lumbar ganglia; the deep-seated ones accompa
the blood-vessels.

The Ureters, the excretory ducts of the kidneys, are me
branous canals, which convey the urine from the pelvis of t
kidney to the bladder. They consist of three coats—an extern
fibro cellular, a middle muscular, and an internal mucous, lin
with scaly epithelium. On leaving the hilum, they are direct
towards the pelvic cavity, alongside the aorta on one, and t
posterior vena cavæ on the other side. On arriving at t
terminal branch of the aorta, they cross obliquely, enveloped
folds of the peritoneum, which hold them against the late
walls of the pelvis, terminating at the postero-superior part
the bladder, which they enter on either side by narrow obliq
slits, guarded by a fold of lining membrane, which acts as
valve, preventing the return of the urine.

The Bladder (Pl. XVII. fig 1, *r*, and fig. 4, *i*), a muscu
membranous organ, serves as the reservoir for the urine, and
situated within the pelvic cavity, which it variably occupi
according to its condition, sometimes reaching the abdomi
cavity. It presents a fundus, body, and neck. The *fun*
is circular, and turned forwards, having a cavity which ma
the site of the *urachus*. The *neck* is turned backwards, a
is the commencement of the urethra; it is related abo
with the vesiculæ seminales and rectum in the male, w
the vagina and uterus in the female, which are interpos
between it and the rectum, below with the floor, laterally w
the walls of the pelvis. It consists of three coats—mucous, m
cular, and serous; the latter is only a partial covering, an
continuation of the peritoneum, being reflected from the super
part of the body, fundus, and neck, constituting the *poster*
false ligaments of the bladder. The muscular coat consists
two layers of smooth muscular fibres, an external longitudi
one, the *detrusor urinæ*, and an inner circular layer, thinly s
tered over the body, but denser at the neck, forming the *sphinc*
vesicæ. There are also two bands of oblique fibres passing fr

he posterior aspect to the openings of the ureters to the back of he prostate gland, which become inserted into the middle of hese organs by fibrous processes, constituting the *muscles of the reters*. The internal mucous coat is pale, smooth, roseate, and oosely attached to the muscular by cellular tissue, which some onsider a fourth coat. It is thrown into *rugæ* when the bladder s empty, and provided with mucous follicles, most abundant at he neck; it is lined by scaly epithelium. Upon the internal urface, between the openings of the ureters and commencement f the urethra, is a *smooth triangular surface*, the *trigone vesi-ale*, which is pale, sensitive, intimately attached to the adjacent issue, and never thrown into rugæ. Projecting from the lower osterior end into the opening of the urethra, is a slight elevation f the mucous coat, the *uvula vesicæ*. The bladder is retained in ituation by true and false ligaments; the false are 5, the 4 folds f peritoneum already described, and the *anterior false ligament* ormed by the remains of the urachus, which passes along the inea alba to the umbilical openings. The true ligaments are —2 inferior and 2 lateral, which consist of condensed cellular issue. The *inferior* spring from the back of the pubis on either ide of the symphysis, and are attached to the front of the neck. 'he *lateral* pass from the pelvic fascia to the sides of the pros-te and bladder. The principal artery is the vesico-prostatic rom the internal iliac. The nerves are from the hypogastric and acral plexuses; the lymphatics pass to the sublumbar ganglion.

The Supra Renal Capsules are two small, flat, yellowish, glan-ular bodies attached to the anterior borders of the kidneys. 'hey are ductless, larger in the fœtus than in the adult, and con-ist of an external cortical substance, and an internal medullary. 'he external is yellow and columnar; the medullary soft, pulpy, ucleated, and granular. Their function is unknown.

The Bladder in the Fœtus is longer, narrower, and more pen-ant; its relative capacity is also greater. It occupies the abdo-ien, stretching to the umbilical opening, flanked on either side y the umbilical artery. The anterior extremity forms a true

neck continuous with a tube leading to the placenta, calle the *urachus*, just as the posterior end is with the urethr At birth, the anterior neck is separated from the urachus, an transformed into a free cul-de-sac, the bladder returning into th pelvis along with the umbilical arteries, and assuming the pos tion it retains in the adult.

SEXUAL ORGANS.

Individuals possess the faculty of reproducing or propagating and this function is divided into non-sexual and sexual,—th former being accomplished in a single individual, the latter b the union of two different organs, either in one or separat individuals. There are three varieties of *non-sexual* reproductio —division, attached buds, and detached buds.

Fissiparous generation consists in the division of the paren into detached masses, each becoming a new creature, and may b bifid and symmetrical, or irregular, as in the infusoria.

Gemmiparous generation, where the new individual buds upo the parent, at first exhibiting little similarity, but graduall acquiring the parental type. When fully formed, it is detache to enjoy a separate existence, as in polypes, belonging to th class Hydrozoa.

Sporular generation, where the young are formed from small de tached germs, which are homogeneous and generally round, bearin the same relation to the off-spring as the egg of the higher animal t the fœtus, as in sponges, and other animals belonging to the sub kingdom Protozoa, where locomotion is performed by cilia.

Sexual reproduction is of two kinds—*hermaphrodite*, when th male and female sexual organs are either placed in one individua or where the union of two individuals is required, each having male and female sexual organ, producing mutual impregnation the female organ of one animal being fecundated by the male orga of the other, as in the leech; and *bisexual*, where the organs ar placed on separate individuals, of which there are three varieties—

ciparous, hatched from eggs *laid* by the parent, as in birds, many ptiles, and fishes; *ovoviviparous*, where the young are hatched om eggs *within* the mother, as in many cartilaginous, some osse- us fishes, and numerous insects,—these are liable to variation, s young birds may be born alive, or eggs hatched externally; *viparous*, where the young are born alive, and there is utero- estation, which may be *placental* or *marsupial*. In all vivi- arous and many oviparous animals copulation is necessary for ecundation, the seminal fluid of the male being introduced into ne genitals of the female, fecundation ensuing within the body f the female parent. In some ovipara, especially those with a atery habitat, fecundation takes place outside the body, there eing no sexual union, the female depositing her spawn, which s covered by the seminal fluid of the male, as in the water alamander, where the ova floats into the female.

In all domestic animals, the generation of a new being resides ith two individuals, a male and female, and is accomplished y certain determined laws, the female furnishing a germ or vule, the male a fecundating fluid or sperm, which animates he germ and renders it fit for development. The *male sperm* elaborated in the heart of two globular glandular organs alled *testicles*, each being furnished with an excretory duct, hich at its origin is folded and convoluted, constituting the *pididymis*. In the rest of its course, the duct is straight, forming ne *vas deferens* which transmits the sperm to reservoirs situated n the bladder, the *vesiculæ seminalis*. Here the sperm accu- ulates, and is expelled by its contractile walls during the act f copulation through the ejaculatory ducts into the urethra, hich is common to the urinary and generative organs. This uct is provided with three accessory glands, the *prostate* and *owper's*. The urethra is supported by an erectile tissue, the *rpus cavernosum*, with which it forms an elongated erectile gan, the *penis*, which in the act of coition is introduced within e vagina of the female.

The secretory organs or Testicles (Pl. XVII. figs. 1, 2, 3) are

two oval glandular bodies, which, in intra-uterine life, are place
in the abdominal cavity behind the kidneys and above the periton
eum. About the seventh month, they descend through the in
guinal canal into a bag suspended between the thighs, termed th
scrotum. In their descent they are guided by a soft cord, th
gubernaculum testis or pilot, which is attached to the inner part o
the bottom of the scrotum. The *scrotum* is made up externally o
a layer of the common integument continuous with that of th
flanks, thighs, and perineum. The skin covering it is soft an
thin, generally black, and clothed with fine downy hairs, an
divided in two by a longitudinal raphe. Below the skin, is a thi
layer of contractile fibrous tissue which forms the proper tunic
the *dartos*, which sends a prolongation between the testes, consti
tuting the *septum scroti*, which corresponds to the external raphe
The testicles are suspended in the scrotum by the *spermatic cord*
which is made up of the vas deferens, vessels, nerves, and tissue
it extends from the internal abdominal ring to the posterio
part of the testicle. In its descent, the cord receives certai
coverings, the *spermatic* or *inter-columnar fascia*, from the ex
ternal oblique, which is attached to the margin of the externa
abdominal ring, and passes down over the cord to the testicle
the *cremasteric fascia*, which is an expansion of the cremasti
muscle, and likewise passes down the coral to become attache
to the testicle; the *infundibuliform fascia*, which is an exte
sion of the fascia of the transversalis abdominis, and is funne
shaped, commencing at the internal-abdominal ring; it is pr
longed as a sheath on the vas deferens, spermatic vessels an
nerves, and is connected below to the posterior part of th
testicle and to its serous tunic, forming the *fascia propria* of th
cord. The coverings of the testicle are three—a double one, d
rived from the peritoneum, in the descent of the testicle, the *tunic
vaginalis*, which is a serous sac, investing the gland,—the outc
layer, the *tunica vaginalis reflexa*, united by cellular tissue t
the dartos; the inner, the *tunica vaginalis propria*, is attache
to the outer surface of the tunica albuginea. The *tunica alba*

Plate XVII MALE GENERATIVE ORGANS

1

2



3

4

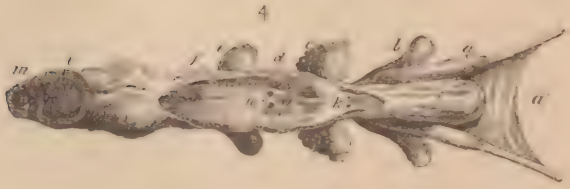

PLATE XVII.

MALE GENERATIVE ORGANS.

Fig. 1.—Male Organs of Generation, seen in position (the Abdominal and Pelvic Cavities opened from the left side).

a. Scrotum. *a'*. General investment. *a''*. Dartos. *a'''*. Tunica vaginalis. *b*. Cremaster muscle. *c c'*. Left vas deferens. *c*. Its simple portion. *c'*. Its dilated portion. *d*. Left vesicula seminalis. *e*. Prostate gland. *f*. Left gland of Cowper. *g*. Foreskin. *h*. Carpus cavernosum penis. *i*. Posterior ligaments of penis. *k*. Accelerator urinæ muscle. *l*. Erector penis muscle. *m*. Glans penis. *n*. Opening of urethra on the glans. *o*. Right abdominal ring. *p*. Fold of peritoneum, which contains the blood-vessels, lymph vessels, and nerves of the cord and testicle. *q*. Right vas deferens, where it passes from the ring into the cavity of the abdomen. *r*. Urinary bladder. *s*. Rectum.

Fig. 2.—The Spermatic Cord, detached along with the Testicle, Epididymis, and Vas Deferens.

a. Testicle. *b b'*. Epididymis. *b'*. Its head. *b*. Its tail. *c*. Ligamentum epididymis. *d*. Spermatic cord. *e*. Vas deferens. *f*. Internal spermatic artery.

Fig. 3.—Horizontal Section of the Right Kidney.

a. Capsule of kidney, separated from the cortical substance. *b*. External or cortical substance. *c*. Internal or medullary substance. *d*. Branches of blood-vessels cut through. *e*. Pelvis of kidney thrown open. *f*. Cut end of ureter.

Fig 4.—Pelvic portion of Urethra, opened from below.

a. Dilated portion of vas deferens. *a'*. Reflection of peritoneum, by which both vasa deferentia are connected. *b*. Right vesicula seminalis. *c*. Right lobe of prostate gland. *d*. Its excretory ducts. *e*. Cowper's gland of right side. *f*. Its excretory duct. *g*. Crest of urethra, with the openings of the two common ejaculatory ducts. *h*. Opening of the third vesicula seminalis. *i*. Urinary bladder. *k*. Openings of the ureters in the neighbourhood of the neck of the bladder. *l*. Transverse section of cavernous bodies. *m*. Transverse section of spongy portion of urethra.

ura, dura mater testis or proper tunic, is a dense fibrous mem-ane of a bluish-white colour, adherent to the tunica vaginalis opria. This union of a fibrous and serous tunic constitutes a ro-serous membrane. The tunica albuginea, after surrounding e testicles, is reflected into its substance, forming a septum lled the *mediastinum testis*, or *corpus Highmorianum*, from hich originate numerous fibrous cords—the *trabeculæ septulæ* -which terminate in the inner surface of the tunic. The in-rnal covering, *tunica vasculosa*, or *pia mater testis*, is the trient coat; it lies beneath the preceding one, enclosing the sticle, and gives off processes between the lobules which ramify the mediastinum testis and trabeculæ septulæ. The testicle oval, with its inferior border convex, its superior straight, nd in contact with the epididymis. It consists of a soft glandular bstance of a reddish-yellow or cream-colour, and is divided to small distinct *lobules*, varying from 200 to 300; these are onical, having their base towards the surface, and consist of veral minute convoluted tubes, the *tubuli semeniferi*, which riginate as loops or free cæcal ends, and are most convoluted at e base of the lobules, gradually straightening as they approach e apex at the corpus Highmorianum, where they unite to form rger tubes, the *vasa recta*, which enter the mediastinum and rminate in a close net-work of tubules, the rete testis. These ass upwards to the superior extremity of the mediastinum, here they terminate in the *vas efferentia*, a number of small ucts which perforate the tunica albuginea in straight lines. hey shortly become convoluted, and form a series of conical sses, the *coni-vasculosi*, from whose base larger tubes issue, nd originate the head of the epididymis. The *epididymis* is a ttened body extending from the apex to the lower end of the stis. It is divided into a *head* or *globus major* and a *tail* or *lobus minor*. The head is closely adherent to the testicle rough the seminal tubes. The body is free, and curved to the ape of the testicle, but separated from it by a pouch of the nica vaginalis. The tail is attached to the testicle by areolar

tissue. The vasa efferentia, after forming the coni-vasculosi enter the globus major, and successively join at irregular distances to form the *canal of the epididymis*, its convolutions forming the body and globus minor; from the latter the canal turns upwards, constituting the *vas deferens*, which, after leaving the globus minor, ascends the back of the testicle into the spermatic cord to the inguinal canal. On entering the internal abdominal ring, the vas deferens leaves the blood-vessels and descends into the pelvis, passing to the sides, then behind and below the bladder, where it becomes dilated, forming the bulbous portion; here it is joined by the ejaculatory duct of the vesicula seminalis, terminating at the base of the prostate. A long narrow tube, the *vasculum aberrans*, is sometimes found leaving the lower part of the canal of the epididymis, extending a short way up the back of the testis, between it and the body of the epididymis, terminating in a cæcal extremity. The vas deferens consists of three coats—an external cellular, a middle muscular, and an internal mucous, lined with columnar epithelium. The *vesiculæ seminales* are two lobulated, pear-shaped, membranous pouches situated on each side of the base of the bladder, and between it and the rectum. They are seminal receptacles, secreting also a special fluid which mixes with the semen. Their larger ends are widely separate, their narrow ones almost meet, forming a triangular space which corresponds to the trigone vesicæ of the bladder. They consist of a single tube which terminates in a blind end, and gives off several branches or diverticula, which also end in closed extremities. The tube is coiled upon itself in a complicated manner, and firmly held together by dense fibrous tissue, the narrow end terminating in a duct which at the base of the prostate is joined at an acute angle by the vas deferens; these constitute the ejaculatory duct. The vesiculæ seminalis is made up of three coats—an external fibro-cellular, a central dense fibrous and elastic, said to contain muscular fibres, and an inner pale mucous one lined by scaly epithelium. The *ejaculatory ducts*, two in number, are formed

by the junction of the narrowed extremities of the vesiculæ eminalis and the vas deferens. Just at the base of the prostate, hey pass between its middle and lateral lobes, terminating in he urethra by two slit-like orifices, one on each side of a lepression on the verumontanum, called the *sinus pocularis*.

The PROSTATE VESICLE (Pl. XVII. fig. 1, *e*, and fig. 4, *c*, *d*), r Weberian organ, sometimes called the *uterus masculinus*, s said to be analogous with the uterus and vagina of the emale. It is a canal about four inches in length, which ascends n the folds of the peritoneum between the vas deferens. ts lower end is dilated, and situated between the ejaculatory lucts. It opens into the urethra on the vera montanum, etween the openings of the ejaculatory ducts, sometimes nding in one of them. The anterior extremity divides into wo cornua, which are dilated at their blind extremities. It s placed in the pelvic cavity around the neck of the bladder nd commencement of the urethra, is connected to the pudic arch y the anterior ligaments of the bladder, and closely united to he rectum by the pelvic fascia. It varies in size, resembling a orse-chestnut in shape, and consists of three lobes—a middle nd two lateral; the middle one is the *isthmus*, and lies on the osterior part of the neck of the bladder and the anterior surface f the urethra. In old animals this lobe becomes enlarged, and ressing on the urethra causes retention of urine. It is enclosed a dense fibrous capsule, which is continuous with the pelvic scia. It is pale, reddish-grey, and very friable, consisting of umerous small follicular pouches, which end in elongated nals; these again unite to form the excretory ducts, which en on the floor of the urethra. The follicles are united gether by areolar tissue, supported by prolongations of the psule. The canals are lined with columnar, and the follicles ith scaly epithelium; it secretes a milky fluid with an acid action.

COWPER'S GLANDS (Pl. XVII. fig. 1, *f*, and fig. 4, *e*, *f*), or lesser ostates, are a pair of small bodies situated on either side of the

membranous portion of the urethra, covered by the triangular
penis muscle. They average a small hazel nut in size, and a
reddish-yellow, consisting of several minute lobules held toget
by investing cellular tissue. They have branched ducts, whic
terminate by one extremity in cellular crypts, by the other in th
floor of the urethra by oblique minute openings.

The URETHRA (Pl. XVII. fig. 1, *u*, and fig. 4) is a membranou
tube which extends from the neck of the bladder to the glan
penis in the male, and from the bladder in the meatus urinari
in the female. In the latter, it is simply an excretory passag
for the urine, but in the male it transmits the seminal fluid
It consists of two layers—an internal mucous, continuous wit
the bladder internally, and the covering of the glans penis e
ternally. The second layer is submucous, and consists of fibro
tissue, with a layer of muscular fibres. It is divided into pr
static, membranous, and spongy portions. The *prostatic*, ver
short, is the most dilatable part of the canal, commencing a
the neck of the bladder. It passes through the upper part of th
prostate gland above its middle lobe. The *membranous* divisio
extends from the prostatic portion to the bulb of the penis, an
is the narrowest part of the canal, being surrounded by fibr
from the accelerator urinæ, triangularis penis, and retractor a
muscus. It is sometimes called the muscular division. Th
spongy portion extends from the bulb of the penis to the e
ternal opening or meatus urinarius; is narrow in the body
the penis, but dilated at either end. The posterior dilation
the bulb is known as the *bulbous portion*. At the external orifice
the canal is contracted, but on reaching the glans it dilates into th
fossa navicularis. As the urethra leaves the neck of the bladd
there is an elevation of the mucous membrane, called the *uvu
vesicæ*. On *laying open* the urethra from the neck of the bladde
the first object that attracts attention is an elongated ridge on th
floor of the prostatic portion, the *caput gallinaginis vel verume
tanum*, or crest of the urethra. On each side of this, is a slig
groove, the *prostatic sinus*, into which the prostatic secretion

ured. At the most elevated portion of the ridge is the *sinus ocularis*, or opening of the prostate; just beneath this, are the penings of the ejaculatory ducts. The mucous membrane of e membranous portion presents nothing particular. At the commencement of the bulbous portion, just behind the membranous ivision, are the openings of Cowper's glands. The entire rethral mucous membrane is beset with numerous minute orices or lacunæ, which are mucous follicular terminals, all facing e external meatus of the urethra. These are most plentiful the lower part of the spongy portion, and in the fossa navilaris is a very large one, the *lacuna magna*.

The Penis (Pl. XVII. fig. 4, *l*, *m*) is the male organ, which not nly supports the greater part of the excretory urinary canal, but so transmits the sperm of the male. During erection it is very rge, at other times it is concealed in the sheath. The *sheath* a loose pendulous doubling of integument, forming a corruted bag on the infero-posterior part of the body, and extendg from the scrotum, with which it is continuous, to the nbilicus. Anteriorly it is cleft, presenting a deep raphe, which aches the umbilicus, with a rudimentary teat on either side. ithin the sheath, are two doublings of integument, known as e *internal sheath* or *vagina propria penis*. The outer one is rrugated, and encircles the inner, which is smaller and rugous. ese corruscations are so arranged as to admit of the erection d projection of the penis, during which they become effaced om the inner doubling. The skin is reflected on to the penis, vering the entire glans. Within the vagina propria are merous follicular bodies, the *glandulæ odoriferæ*, which secrete peculiar odorous matter to preserve the sensibility of the parts, d facilitate the slipping out and in of the organ. The sheath is spended from the abdominal walls by the *suspensory ligants*, which are two layers of yellow elastic tissue, passing from e abdominal fascia to the sides of the sheath. The penis conts of the corpus cavernosum and corpus spongiosum, both ectile. The *corpus cavernosum*, forming the bulb of the penis,

is divided by an imperfect partition, the *septum pectiniform* into two lateral corpora cavernosa. This septum is thick a complete behind, gradually thinning out as it proceeds to t free extremity of the penis, where it only imperfectly separat the halves. It consists of simple vertical bands, similar to t teeth of a comb, extending from above downwards. The corpo cavernosa are invested by a strong elastic fibrous tunic, when spring numerous trabeculæ, which divide it into numerous co partments, giving it a cavernous appearance. In these caver are cells, which receive blood from the pudic and bulb arteri The nerves of the wall come from the sacral and hypogastr plexus. The dorsal surface between the cavernous bodies grooved for the pudic vessels; the inferior aspect is also groove for the corpus spongiosum. The corpora cavernosa recede fro each other, posteriorly forming the *racinæ* or *crura*, which pa to the tuberosities of the ischium and pubic arch. These a crossed by the erectores muscles. The penis is attached to t symphysis pubis by two suspensory ligaments, which sprin from the corpora cavernosa. The *corpus spongiosum* encloses t urethra, and is situated in the inferior groove of the corpo cavernosa. It commences between the crura by an enlarge portion. The bulb of the penis passes down the groove un it reaches the external extremity, where it expands to form t glans. The spongiosum is enclosed in a fibrous tunic, simil to, but more delicate than, the cavernosa. The *glans* form t free extremity of the penis, and consists of the corpus spong osum. At its apex is a deep fossa, in the centre of which li the *meatus urinarius*, bounded by two prominent lips. It te minates posteriorly by a constructed part, the *cervix*, in fro of which is the projecting *corona glandis*. When the penis quiescent, the cervix is bounded by the prepuce. The muscl of the penis are the *retractor* penis, a long, flat and involunta muscle, arising from the inferior surface of the sacrum. It d scends in front of the sphincter ani, between the retractor a and walls of the rectum, where it gives off numerous she

undles, which unite below and form a suspensory ring for the
nus. It now passes along the inferior surface of the penis,
s attached to the accelerator urinæ by cellular tissue, reaching
he glans, on which it is lost. It retracts the penis within the
heath.

Accelerator urinæ, a pair, consisting of transverse fibres, en-
ircling the urethra. They arise from the ischial arch, pass
long the under surface of the penis, completely investing the
rethra, and extend as far forwards as the glans, their fibres
nutually blending. It compresses the urethra, and assists in
ne discharge of urine and semen.

The *erector penis* is somewhat conical, arising from the inferior
ortion of the tuberosity of the ischium. It is inserted into the
enis. It is a primary dilator of the bulbous urethra.

The *triangularis penis* is thin and ribbon-shaped, arising from
ne ischial arch. It passes forwards to Cowper's glands, and is
nserted into the membranous urethra, blending with Wilson's
uscle. It compresses Cowper's glands, and assists in the dis-
harge of their contents.

Wilson's muscles.—A pair, consisting of transverse fibres, which
ise from the lateral walls of the pelvis, and are attached to the
embranous urethra embracing the prostate. They compress
d aid in the discharge of the gland, contracting the mem-
anous portion.

Cremaster.—A broad ribbon-shaped muscle, situated on each
le, principally in the iliac region. It arises from the fascia
vering the psoas muscles; is attached by cellular tissue to
e psoas magnus and iliacus, passes through the inguinal
nal, and is inserted into the tunica vaginalis propria of the
ticles; it consists of pale delicate fibres, terminating in a slen-
flattened tendon. It retracts and assists in suspending the
ticle.

The Generative organs of the Female are divided into ex-
nal and internal. The *external* are the vagina and vulva.
e Vulva (Pl. XVIII. fig. 1, *f*, and fig. 3, *a*, *a*) is situated in

the perineal region, immediately below the anus; the extern opening is a long vertical split, presenting two lips and tw commissures. The *labia* or lips are formed by an external so unctuous layer of skin destitute of hair, and an inner one mucous membrane continuous with the genito-urinary apparatu between these, is a quantity of fat and areolar tissue, mos abundant in the young animal, and the erectile vaginal bul divided into two branches, which leave the clitoris, and pas along the side of the vulva, terminating in round lobes, which ar filled with blood during copulation, rendering co-aptation ver complete. The *superior commissure* is very acute, and reache almost to the anus: the space between the two is the *perinæu* The *inferior commissure* is obtuse and rounded, bounded by hollow, the *fossa navicularis*, in which rests the clitoris. Th cleft between the labia is the *fissura magna*. In the interior the vulva lies the *clitoris*, which originates as two crura from th ischial arch, and is attached to, and suspended from, the sym physis by the suspensory ligament from its origin at the crur The clitoris passes backwards, jutting towards the inferior com missure, its free extremities being lodged in the fossa navicular and enveloped by a mucous covering, the *prepuce of the clitori* The structure of the clitoris resembles that of the corpora cave nosa of the male; and, having a fibrous capsule, erectile tissu and cavernous vessels, it becomes erect during copulation. Th external opening of the urethra meatus urinarius enters the i ferior surface of the vulva four inches within the external opening it is larger than the male opening, and surrounded by a fold mucous membrane, which acts as a valve. The *hymen* is a thi semilunar fold of membrane, which separates the vulva from th vagina; it is ruptured during the first act of copulation, an gives rise to a number of small round elevations, which surroun the opening of the vagina, the *caruncula myrtiformes*. Th mucous membrane lining the vulva, is a pale rose, and covere with mucous follicles, the *glandulæ odoriferæ*, which are mo numerous near the opening of the urethra, and sebaceous gland

PLATE XVIII.

FEMALE GENERATIVE ORGANS.

Fig. 1.—Urinary and Female Genital Organs seen in position. (The Abdominal and Pelvic Cavities are opened from the right side.)

a. Right kidney. *b.* Left kidney. *c c.* Ureter of each side. *c'.* Opening of right ureter into bladder. *d.* Bladder. *e.* Right lateral ligament of bladder. *f.* Labia. *g.* Vagina. *h.* Body of uterus. *h'.* Its right horn. *h''.* Its left horn. *i.* Broad ligament of right side. *i'.* Broad ligament of left side. *k.* Fallopian tube at the right horn. *l.* Right ovary. *m.* Left ovary.

Fig. 2.—Vertical Section of Ovary.

a a. Closed Graafian follicles. *b b.* Open Graafian follicles.

Fig. 3.—Female Organs of Generation removed from their Position.

a a. Labia separated at their superior angle. *b.* Clitoris. *c.* Its prepuce. *d d.* Vagina laid open. *e.* Urinary bladder. *e'.* Its opening into the vagina. *f.* Vaginal valve. *g.* Neck of uterus. *g' g'.* Body of uterus laid open in the middle line. *h.* Right horn of uterus laid open. *i.* Fallopian tube. *k.* Ovary.

Fig. 4.—Mamma, seen from below.

a. Aponeurosis of external oblique muscle of abdomen. *b.* Skin covering the mamma, separated. *c.* Yellow fibrous investment. *d.* Milk reservoirs laid open. *e.* Nipple, showing external openings of the two milk reservoirs.

Fig. 5.—Mamma, seen from above.

a. Aponeurosis of external abdominal muscle at the lower part of abdominal wall, seen from the outer surface. *b.* Upper (dependent) surface of mamma. *c c.* Suspensory ligaments of mamma, being processes of the yellow sheath of the external abdominal muscle.

which secrete an odorous unctuous substance, and are found for the most part under the prepuce of the clitoris and on the labia majora. The vulva and clitoris are provided with two muscles, viz., erector clitoris and constrictor clitoris, sphincter vaginæ or constrictor vulvæ.

The Vagina (Pl. XVIII. fig. 1, *g*, and fig. 3, *d*, *d*) is the cylindricoid membranous canal leading from the vulva to the uterus, and is situated between the rectum and bladder. It consists of two membranes—an inner mucous and an outer fibrous—similar to the dartos in the male: between them is the vaginal bulbs; constricted at its origin, the vagina widens at its inner extremity, and surrounds the neck of the uterus. The mucous coat, clothed with filiform papillæ, and studded with follicles, presents a longitudinal ridge, the raphe, whence spring a number of transverse rugæ, which abound at the constricted opening, and which facilitate dilatation during parturition. Blood is supplied by the pudic artery; nerves by the sacral plexus.

The *internal generative organs* are the uterus, Fallopian tubes, and ovaries.

The Uterus, or womb (Pl. XVIII. fig. 1, *h*, *h'*, *h''*, *i*, *i'*, *k*, and fig. 3, *g*, *g'*, *g''*, *h*), is the musculo-membranous sac in which the impregnated ovum is retained. It is situated in the lumbar abdominal region and pelvic cavity, and presents a *body* and *two cornua*. The body is cylindrical and somewhat flattened; its superior surface contacts with the rectum, which passes between its horns, while the suspensory ligaments are attached laterally; the inferior surface and borders are related to the bladder and intestinal convolutions; the anterior extremity, *fundus*, is continuous with the cornua; the posterior passes into the vagina, constituting the *cervix* or *neck*, which is thick, hard, and projecting in the virgin-filly, and transverse in the old-mare. In the centre, is a transverse aperture or fissure, leading into the vagina, called the *os uteri* or *os tincæ*. The cylindrical cornua spring from the anterior extremity of the body, and verge upwards and forwards, presenting an inferior free convex

curvature and a superior concave one, to which are attached t
suspensory ligaments. The posterior base is continuous wi
the body; the anterior extremity, or summit, forms a cul-de-s
turned upwards, into which the Fallopian tubes are inserte
The uterus consists of three layers—an external serous, centr
muscular, and internal mucous. The serous coat, a reflection
the peritoneum, covers the body and horns, forming the *broad*
suspensory ligaments, and is continued on to the bladde
rectum, vagina, and walls of pelvic cavity. The muscular co
consists of 3 primary sets of fibres, and an intermediate on
longitudinal and transverse. The external layer is thin, an
encircles the anterior part of the body, cornua, and Fallopia
tubes; the internal rings the cervix, free ends of the cornu
and opening of the Fallopian tubes; the central are various
disposed; they are all better developed in the impregnate
uterus. The mucous coat is thin, smooth, and closely adhere
to the muscular one, more especially in the body; is pale reddis
white, clothed with ciliated epithelium, and furnished wit
numerous papillæ, mucous follicles, and glands similar to tho
of the small intestines when unimpregnated or collapsed.
net-work of rugæ exists, termed the *arbor vitæ uterinus*.
has three openings—the os uteri, and one at each end of th
horns—for the Fallopian tubes. Leading from the os uter
through the cervix to the internal cavity, is a constricted passag
—the *ostium internum*. The ligaments consist of four sets
the *broad*, which pass from either side of the uterus to pelv
walls, forming a septum across, and dividing the pelvis into tw
portions; the *inferior*, containing the bladder, vagina, a
urethra; the *superior*, the rectum. Two peritoneal folds un
the uterus to the rectum, the *superior* or *recto-uterine*; and tw
pass from the uterus to the bladder, the *inferior* or *vesico-uteri*
ligaments. Two fibrous cords, the *round* ligaments, rise from th
upper angles of the uterus, proceed to the internal abdomin
ring, through the inguinal canal, and are lost in front of th
symphysis pubis. The arteries are the uterine and utero-ov

ian. The nerves are from the sacral, inferior hypogastric, and permatic plexuses; the large lymphatics terminate in the lumar ganglion. The uterine appendages are the ovaries and allopian tubes.

The Fallopian tubes (Pl. XVIII. fig. 1, *k*, fig. 3, *i*), oviucts, or uterine trumpets, are two canals which convey the ova om the ovaries to the uterus. They are enclosed in the free orders of the broad ligaments, and run in a serpentine course om the cul-de-sac of each horn to the sides of the pelvis. The anal commences at the horn of the uterus by a very minute pening, the *ostium uterinum*, gradually enlarging into a trumpet xtremity, which is contracted at its termination, forming a small und orifice, the *ostium abdominale*, which communicates with ne abdomen, thus forming a direct communication between the ucous membrane of the uterus and serous membrane of the bdomen. The free extremity of the tubes terminate in a series f irregular *fimbria* or fringes, which are turned forwards and anged in a circle around the ostium abdominale. One of ese is adherent to the ovary, and along it is a fissure contin-ous with the external opening of the tube, which embraces the vary during sexual excitement. The walls of these tubes con-st of three coats—an external or serous one, derived from the ritoneum; a middle muscular, consisting of an external longi-dinal and an internal circular layer of smooth fibres; and an ternal mucous coat thrown into longitudinal folds, and con-nuous with the uterus. Ciliated epithelium clothe both tubes d fimbriæ.

The Ovaries (Pl. XVIII. fig. 1, *l*, *m*, and fig. 3, *k* and fig. 2) alogues of the testes, are the essential organs of generation in e female. They are oval, similar to, but smaller than the ticles, and are situated in the lumbar region of the abdomen, little behind and on a line with the kidneys; they are erted into the anterior part of the broad ligament of the rus behind and below the Fallopian tubes. In addition to ir connection through the broad ligament, they are attached

at their inner end to the uterus by a dense fibro-areolar cor the *ligament of the ovary*, and by their rounded outer end to th fimbriated extremity of the Fallopian tube. They are whit nodulated, and uneven, consisting of an external serous inves ment from the peritoneum. Below is the dense fibrous *tunic albuginea*, resembling that of the testicles, which encloses th *stroma*, a firm reddish-white vascular substance, apparently pr longations of the external coat. Within these are numerou small, round ovisacs or *Graafian vesicles*, which consist of tw coats, an external vascular and an inner one, the ovi-capsul lined by a granular epithelial layer, the *membrana granulosa* They contain a clear, colourless, albuminous fluid, and a small round vesicular body, which is the true *ovum*. When th Graafian vesicle ruptures, the ovum escapes into the Fallopia tubes, and is thus conveyed into the womb, the remains of th vesicle being converted into a yellow mass, the *corpus luteum* which shortly becomes a small puckered cicatrice. The arteri are the flexuous utero-ovarian.

The Specialities in the Generative Organs of domesti Animals.—In the Ox, Sheep, and Ruminants generally, th testicles are large and oval, the epididymis projecting beyon them. The tunica vaginalis is continuous with the abdomen The vesiculæ seminales are large, and present two lateral elon gated glandular irregular lobes, which are sometimes considere part of the prostate, and lie just in front of it. Their secretio is similar to that of the prostate. Cowper's glands are large, an placed behind the bulb of the urethra. In the Ram the vas deferentia unite to form a common duct. The penis of the Bul is long and thin, and projects far under the abdomen. It is ben upon itself, in the form of the letter S, a little anterior to the bull the inferior curvature being forwards, the superior backwards In these terminate the suspensory ligaments. The glans is smal and attenuated, the canal of the urethra ending in front by narrow whip-like process of the corpus spongiosum, which i covered by a rosy papillated sensitive integument. The sheath

the bulb extends much further forwards than in the horse, and presents at its opening a number of long stiff hairs, the prepuce being prolonged as an elastic sheath. It is furnished with four thin muscles—two anterior and two posterior. The *anterior* are *protractors*, restoring the prepuce to its original position; the *posterior*, *retractors* drawing the prepuce and sheath backwards, and assisting in retracting the penis. During erection, the curves in the penis are effaced, but when quiescent, and drawn into the sheath by the suspensory ligaments, the curvatures are re-formed. In ruminant females, the mucous membrane of the uterus presents a number of rounded vascular processes, which exhibit eminences and follicular depressions, into which are implanted the tufted filaments of the placental cotyledons or placentulæ. During gestation, in the Cow and Sow, the lateral walls of the vagina are traversed by a mucous canal, which opens into the vulva on either side of the meatus urinarius; these are the *canals of Goertner*, and their use is unknown. In the Pig the testicles lie in the perineal region, just below the anus. They, in common with the epididymis, seminal vesicles, and prostates, are largely developed. The Pig's penis consists of a single corpus cavernosum, just above the testes, about four inches from the insertion of the prepuce, and is bent twice upon itself, at intervals of about an inch, forming a sigmoid curve. It is flattened in the major part of its course, becoming round and thin as it approaches the glans, which is very long, and almost cylindrical, except at its extremity, where it is prismatic, ending in a point which is suddenly bent upon itself. In the Sow the glans clitoridis is also bent upon itself. The body of the uterus is short, but the horns are long and convoluted. Like the small intestines, the ovaries are irregularly nodulated, owing to the Graafian vesicles being prominent. In the Dog and Cat the testicles are situated in the perineal region, below the anus. The vesiculæ seminalis and ejaculatory ducts are awanting. The prostate is large, forming a conspicuous bulb around the origin of the urethra. Cowper's glands are awanting

in the Dog, but are large in the Cat. The penis of the Dog i long, and terminates in a point. In common with the hyen and other carnivoræ, a bone is found in the penis. Its anterio extremity is fixed in the glans penis. The posterior is attache to the corpus cavernosum, occupying all that portion of the peni which is lodged in the sheath. It is long, conical, and incurved presenting an inferior gutter, in which the urethra is placed which is continuous with the groove of the corpus cavernosum It favours the introduction of the penis into the vulva. In th Dog the corpus spongiosum forming the glans undergoes a very remarkable degree of tumefaction, which retains the two sexe *in coitu* for a considerable time. The female differences are un important. In the Cat the penal bone is not so well developed The penis, when relaxed, is turned backwards, consequently th urine is voided behind; when erect, it assumes the same posi tion as in other carnivora. In the female a small bone exists i the clitoris.

Mammæ, or Mammary glands (Pl. XVIII. figs. 4, 5) are char acteristic of the highest division of the animal kingdom—th mammalia, physiologically speaking. They are uterine append ages, which nature has provided for the gradual developmen and perfection of the animal. In some mammalia—the whale for instance—the teats are situated in sulci, one on each sid of the vulva, whence they are, as it were, removed in differen animals until in the human species they are placed in the pectora region. The mammæ are glandular organs, which secrete milk In the young female, as in the male, they are rudimentary, becom ing developed at puberty, when the female is fit for reproduction During gestation they gradually enlarge, and at parturition reac their greatest activity. When the period of suckling terminates they shrink, returning almost to their original state. In th Mare, these glands are two, placed one against the other, in th inguinal region, between the thighs and under the pubis, havin the same relative position in the female as in the scrotum in th male. In full activity, they present two hemispherical masse

eparated by a deep fissure, each half presenting in its centre
nipple, teat, or mammary process, pierced at its free extremity
y numerous orifices for the passage of the milk. The mammæ
re supported by the outer covering, a continuation of the com-
non integument, and by numerous short elastic plates, similar
o the suspensory ligament of the male scrotum, derived from
he elastic abdominal fascia. The outer tunic of integument is
oft, black, and covered with fine downy hair, which disappear
n the teat. Below this, is a thin elastic covering, which blends
vith the elastic plates descending from the abdominal fascia.
Besides supporting the gland, it sends into the substance
f the gland several prolongations, which form partitions
etween the principal lobes. The interior of the mamma is
nade up of yellow glandular tissue, consisting of numerous
obes, united by cellular tissue. Each of these is again made
p of small lobules, composed of minute ducts and numerous
mall cells. In these vesicular cells or *acini*, the milk is secreted
nd conveyed to the ducts, which unite to form a common
xcretory duct for each lobe—the *ductus lactiferous* or *galacto-
horus*. These increase in size, and, by repeated union, converge
o the centre of the gland, where they terminate in dilated
onical cavities—the *lactiferous sinuses or reservoirs*—which
ary in number, and freely communicate with each other. From
hese proceed a number of distinct canals, which run in a
raight course to the free extremity of the teat, where they
rminate in a cribriform manner, with contracted orifices. The
ternal surface of this excretory apparatus is lined by a fine
ucous membrane, clothed by columnar epithelium. The
ucous membrane of the ducts is united by a thick layer of
uscular fibre, which forms a doubling, and, being endowed
ith contractibility, acts as a sphincter, and retains the milk.
he teat is covered with skin, devoid of hair, and at its base is
eled by tubercles or glands, which secrete a sebaceous matter
: the protection of the teat during the suckling of the young.
he mammæ are supplied with blood by the mammary artery,

a branch of the arteria profunda femoris, corresponding to the external pudic in the male.

In the Cow, the mammary glands constitute a single mass termed the udder, which is composed of two symmetrical halves placed one against the other. Each half is again divided into two distinct glands, with its own teat, so that the udder consists of four quarters and four teats. Behind this, are two small rudimentary teats. In the centre of each quarter, just at the base of the teat, is a large galactopherous *sinus*, the general receptacle of all the lactiferous conduits. From this sinus, which is sometimes large enough to contain a quart, proceeds down the centre of the teat one definite excretory canal. In the Sheep, there are two mammæ and two teats, which likewise presents one excretory duct. There are also two small rudimentary teats. In the Pig and Dog, the teats and mammæ are arranged in two rows along the sides of the middle line of the belly. Each row is composed of from six to twelve glands, extending from the pubis to the sternum. Each teat presents at its free extremity five or six orifices, the openings of tubes leading from milk reservoirs.

Milk, the fluid secreted from these glands, although apparently homogeneous, consists of caseine matter, a peculiar sugar and fixed salts. The fatty matter forms the butter, and is composed of stearine, oleine, and butyrine—the former yielding, by saponification, oleic and stearic acids; the last, butyric, caproic and caprio-volatile acids. Milk may be regarded as a serous fluid, holding in suspension minute white globules, composed of caseine and fatty matter. It bears a striking analogy to blood, not only in its proximate elements, but also in its physical changes.

Thus, blood consists of—

Clot, { Fibrine. / Red particles, or corpuscles.

Serum, { Albumen. / Lactates. / Aqueous extract. / Alkaline salts. / Fatty matter.

Milk consists of—

Cream, { Caseine. / Butyraceous matter. }

Skim milk, { Caseine. / Albuminous extract. / Aqueous extract. / Sugar. / Salts. / Fatty matter. }

t is the only substance which contains all the elements neces-ary for support and growth. The first portion secreted is the *olostrum* or beastling, and consists of numerous cells, which ontain a large proportion of oil and sugar, and a peculiar ›urgative principle.

ORGANS OF RESPIRATION.

By the unimpaired action of these organs, the blood is nabled to maintain the vitality of every animal structure. 'ertain chemical and physical changes take place between it nd the atmospheric air, consisting in the absorption of oxygen ›y inhalation, and the giving off carbonic acid by exhalation. 'hese changes constitute the important function of *respiration* —the former act being necessary for the elaboration of the luid, the latter for the elimination of a substance which, if etained, would prove prejudicial. The organs of respiration are nvariably adapted to the wants of the animal and the medium in hich it lives. Thus, insects breathe by air tubes, opening on he surface of the body; in the oyster, breathing is performed by inges; in fishes, by gills; in other animals, by means of elastic ir bags, called lungs, which are sometimes enclosed in special ivities, communicating with the atmosphere by means of an air ibe; in birds there is no special cavity for the breathing pparatus, their lungs communicating with certain of the long ones. In mammalia, the lungs are enclosed in a special cavity, ith but one external communication.

The organs of respiration in *the* HORSE, *who breathes only rough his nose,* consists of the *nasal openings, nasal chambers,*

larynx, *trachea*, and *thoracic cavity*, with its contained viscera *bronchiæ*, *bronchial tubes*, and *lungs*.

The Nose (Pl. XIX. fig. 1, *a*, *b*, *c*, *d*, *e*, *i*; fig. 6, *a*, *b*, *c* in addition to being one of the organs of respiration, is the special organ of the sense of smell. The nasal openings or *nostrils* are two right and left lateral oblong openings, situated in the anterior part of the face at the extremity of the nose, are disposed obliquely from above downwards, and without inwards, slightly curved so as to present their concavities to the external surface. They are bounded by movable wings or alæ which are covered within and without by a thin delicate skin clothed with fine soft hairs. The external wing is concave, and its border is free; the internal convex, and attached by its minor border to that of the opposite side. The superior commissures of the alæ form a slight cross which curves inwards. The finger introduced into these commissures does not enter the nasal cavities, but a conical cul-de-sac, the false nostril, a diverticulum of the nose. This cavity is made by doublings of the skin, lined by mucous membrane, and lies in the angles between the nasal spine and the anterior extremities of the intermaxillary bones. The false nostrils communicate freely with the nasal chambers; their precise use is unknown, but they probably enlarge the nasal openings during rapid exertion. The inferior commissures are large and round, presenting a short distance within a passage sometimes double, which is the inferior orifice of the lachrymal conduit. In the Ass and Mule, this opening passes back to the deep surface of the external alæ near to the superior commissures. The nasal openings consist of a cartilaginous basis covered by muscles, and lined internally by mucous membrane. The cartilaginous basis resembles a comma, the cartilage of one side joining that of the opposite, forming the letter X. They are loosely attached to the anterior extremity of the cartilaginous septum to keep the nostrils open, permit dilatation, and protect the nasal peak. They are divided into a superior and inferior part. The former is large, nearly circular, and within the substance of the

RESPIRATORY ORGANS

PLATE XIX.

RESPIRATORY ORGANS.

Fig. 1.—Right-half of Head, the Nasal Septum having been removed and the Cavities of the Nose and Mouth opened.

a. Anterior turbinated bone. *b*. Posterior turbinated bone. *c*. Anterior meatus of nose. *d*. Middle meatus. *e*. Posterior meatus. *f*. Cavity of mouth laid open. *g*. Opening of Eustachian tube. *h*. Opening into cavity of cheek. *i*. Opening into cavity of nose. *k*. Opening into the larynx. *l*. Opening into the pharynx.

Fig. 2.—Muscles of the Larynx.

(The Thyroid Cartilage has been removed.)

a. M. Thyroideus transversus. *b*. M. Crico-arytenoideus posticus. *c*. M. Crico-arytenoideus lateralis. *d*. M. Thyro-arytenoideus.

Fig. 3.—Muscles of the Larynx.

a. M. Hyo-epiglotticus. *b*. Thyro-hyoid muscle. *c*. Crico-thyroid muscle.

Fig. 4.—The Larynx, with the Body of Hyoid-bone and commencement of Windpipe, seen from behind.

(The Glottis is nearly closed by means of a Needle and Loop.)

1. Epiglottis. 2. Arytenoid cartilage of left side. 3. Flattened portion of cricoid cartilage. *a*. Hyo-epiglottic ligament. *b*. Thyro-epiglottic ligament. *c*. Arytenoid ligament. *d d*. Crico-arytenoid ligament. *e e*. Lateral crico-thyroid ligaments.

Fig. 5.—Larynx, with Body of Hyoid-bone and commencement of Windpipe, seen from before.

1. Ala of thyroid cartilage. 2. Ring of cricoid cartilage. *a*. Middle thyro-hyoid ligament. *a'*. Lateral thyro-hyoid ligament. *b*. Middle crico-thyroid ligament. *c*. Ligament between cricoid cartilage and trachea.

Fig. 6.—Summary View of the Organs of Respiration in position. The anterior half of the body is opened from the left side, and the Respiratory Organs thereby exposed.

a. Septum of nose. *b*. Superior nasal opening. *c*. Larynx. *d*. Windpipe. *e*. Thyroid gland. *f f*. Anterior mediastinum. *g g*. Posterior superior mediastinum. *h*. Left lung. *h'*. Its anterior end. h''. Its posterior end. *h'''*. Its superior border. *h''''*. Its inferior border.

nternal alæ, and covered by the dilatator naris transversalis. The latter is crescentoid, passing to the inferior commissure; it s prolonged by a blunt point to the inferior part of the external ala, to which the orbicularis oris, dilatator naris lateralis, and evator labii superioris alæque nasi, are attached. The skin vhich covers the nostrils is very thin, containing a quantity of ›igment. It is continuous with the mucous membrane of the nterior, and adheres to the muscles by dense fibrous or by means f cellular tissue. The blood-vessels are the superior coronary asal and palato-labial arteries. The nerves are sensory and notor,—the former from the fifth, the latter from the seventh. n the Ox the nostrils are much narrower and less movable, and laced on either side of the muzzle. In the Pig the anterior extremity of the nose is the snout, which is round and flat anteriorly, and presents on either side the nasal opening: it is the rue organ of touch, and always employed in rooting and digging. Like the muzzle of oxen, it is always damp in health, and of a blackish colour. At the anterior extremity of the nasal septum of the pig is a small snout or spade bone covered by cartilage, which extends round the nasal openings. The nose of the Dog is generally black, damp, cold, slightly nodulated, and projecting in certain breeds, being divided by a deep mesian fissure. The nasal openings are somewhat of the same shape as the nasal cartilage of he horse, but are isolated appendages of the turbinated bones.

The Nasal chambers (Pl. XIX. *ut supra*) are situated above, nd in front of the palatine bones. They extend from the cribriorm plates of the ethmoid to the nostrils in a direction parallel ith the long axis of the face, and are separated from each other y the cartilaginous *septum nasi*, which in age undergoes partial ssification, and is inserted inferiorly into the groove of the vomer osteriorly. Being continuous with the perpendicular plate of the hmoid superiorly, it rests in a groove formed by the union of the asal bones. Anteriorly, it is widened out and attached to the rtilaginous base of nostrils, thus preventing any communication etween the chambers. The *internal wall* of the chambers is

smooth, and formed by the septum nasi; the *external* chiefly completed by the superior maxillary, is full of winding and divided by the turbinated bones into three passages *meati;* the *superior* lies between nasal and frontal above, an superior turbinated below; the *middle* between the two turb nated bones, reaching to the cribriform plates of ethmoid; whi the *inferior* rests between the inferior turbinated and floor of th chamber. The *roof* is formed by the nasal and part of th frontal bones. The *floor*, broader and shorter than the roof, completed by the palatine process of superior maxillary an palatine bones, and is concave from wall to wall. The *anterio extremity* is formed by the nasal openings. The *posterior* occupied above by the cells of the ethmoid; below is the ova opening of the *posterior nares*, in each chamber circumscribed b vomer and palatine bones, which communicate with the pharynx The nasal chambers are lined by a delicate, pale rose-coloure mucous membrane, the *pituitary* or *Schneiderian*, which is con tinuous with the skin on the exterior of the nose, the mucou membrane of the pharynx, the conjunctival membrane throug the lachrymal duct, and with the sinuses of the head. It i attached everywhere, and sometimes inseparably to the per chondrium of the septum and the periosteum of the bones. Th pituitary membrane is fibro-mucous and sensitive, varying in vascularity and thickness, being most vascular on the septum and turbinated bones, and thinnest in the sinuses; its free sur face is smooth, and covered by epithelium. Near the externa opening the epithelium is scaly—the remainder ciliated. It i studded with numerous follicles or crypts, which secrete mucou to keep the surface moist, preserve its sensibility, and defend i from noxious vapours. The blood-vessels come from the nasa and ophthalmic arteries. The nerves are the first pair o olfactory, the nerve of special sense. Branches of the fifth supply sensation, and the seventh pair motion. The canal o Jacobson in the Horse does not enter into the mouth, the two branches meeting and terminating in a cul-de-sac, V thus. In

'ATTLE and SHEEP, the nasal chambers do not communicate at he posterior nares below the inferior border of the vomer, but ave a third cornet or olfactory cave, and the canal of Jacobson ommunicates with the mouth. It commences in the floor of he nose, at the base of the septum, on each side of the vomer, roceeds forwards, and terminates behind the pad in front of the outh. It contains a number of mucous follicles and nerve laments. Its use is unknown.

Each nasal chamber opens into five distinct sinuses—frontal, uperior maxillary, ethmoid, sphenoid, inferior maxillary. The irst four communicate.

The *frontal sinus* is irregular, situated at the inner side of the rbital socket, and is formed by the frontal, nasal, lachrymal, thmoid, and superior turbinated bones. It communicates with ne superior maxillary sinus through a large opening, which is ierced in a thin long plate. The right sinus is separated from he left by a thick vertical plate.

The *superior maxillary sinus* is placed below the orbit, and is ormed by the superior maxillary, molar, ethmoid, and lachrymal ones. It communicates with the frontal, is continuous with ne spheroidal, and by a small slit with the ethmoidal sinus.

The *sphenoidal sinus* is very small, and formed by the phenoid and palatine, being divided by incomplete bony septæ nto numerous compartments. The anterior are between the lates of the palatine, the posterior dug out in the body of the phenoid. The sinuses are separated from each other by a late, which may be perforated.

The *ethmoidal sinus* is the cavity in the centre of the bone, nd communicates by a small chink with the superior maxillary.

The *inferior maxillary sinus is situated in the superior maxil-ry* bone, being separated from the superior maxillary by a thin ony plate. About the third molar tooth, it communicates with e inferior turbinated bone.

The LARYNX (Pl. XIX. fig. 1, *k*, fig. 4, fig. 5, fig. 6, *c*), is a ro-cartilaginous box, pierced through and through, situated at

the anterior extremity of the windpipe. It gives passage to a and contains the organs of sound. The anterior extrem opens into the pharynx; the posterior is continuous with t trachea. It lies at the posterior part of the intra-maxilla space, is directed obliquely from above downwards and bac wards, being suspended between the cornua of the os hyoid and united by one of its cartilages to the extremity of the ho like process to the pharynx. It is attached by muscles, a partly supported by the trachea.

The *cartilages* are *seven*, three single and two doublets. Th former are the *cricoid*, *thyroid*, and *epiglottis;* the latter, th *arytenoid* and *cuneiform*.

The *cricoid*, or ring cartilage, is situated at the base of th larynx; narrow and convex infero-anteriorly; deep and broa postero-superiorly. It presents two surfaces and two border The internal surface is smooth, and covered by mucous mem brane; the external postero-superiorly presents in the mesia line a longitudinal ridge, to which is attached a few longitudin fibres of the œsophagus. On either side of the ridge, is a broa concavity, in which rests the crico-arytenoideus posticus; whi on each side of the concavities is a small protuberance for ar culation with the posterior cornua of the thyroid cartilage. Th superior border is directed obliquely upwards and backward and comprised between the two branches of the thyroid. O either side of this border is a smooth lateral convex surface f articulating with the arytenoids. The inferior border is leve and encircles the upper part of the first ring of the trachea, which it is connected.

The *thyroid*, or shield cartilage, is the largest in the laryn It consists of two lateral expansions or alæ, which meet and uni antero-superiorly at an acute angle, forming a projection calle the body of the thyroid, equivalent to the pomum Adami man. Its inferior surface is smooth, giving attachment to tendon of the sterno-thyro-hyoideus. On the superior surfac is a blunt, irregular protuberance, with which the epiglott

rticulates. The alæ are quadrilateral, slightly convex exter-ally, and clothed by the attachments of the hyo-thyroid and hyro-pharyngeal muscles. They are slightly concave internally, nd covered postero-superiorly by mucous membrane. From he receding angle of the wings anteriorly, spring the vocal ords, thyro-arytenoid and thyro-epiglottidean muscles; to the nferior border the crico-thyroid ligament is attached, to the nperior the thyro-hyoidean membrane. Posteriorly, each wing erminates in two cornua. The superior inclines upward, and is tached by fibro-cartilage to the extremity of the heel-like pro-ess of os hyoideus; the inferior, the larger and more prominent, rticulates with the small protuberance on the posterior surface f the cricoid cartilage.

The *arytenoid* (Pl. XIX. fig. 4, 2), ewer-shaped cartilages, a *air*, lie in front of the cricoid, and above the entrance of the rynx. They are irregularly triangular, presenting two surfaces, ree borders, and an apex. The internal surface is smooth, and vered by mucous membrane; the external divided by a ridge to two portions; the base of the superior is turned backwards, nd covered by the arytenoid muscle; the inferior is oblong, and ceives the attachment of the crico-arytenoideus lateralis and yro-arytenoideus. The inner border unites with its fellow; the sterior one, forming the base, is turned backwards, and receives e attachment of the crico-arytenoid posticus, the outer angles ticulating with convexities on the side of the superior border cricoid cartilage. The anterior border is thick, and receives e insertion of the vocal cords. The apex formed in front by e junction of the two is prolonged by two pieces of fibro-rtilage, the cornicula laryngis, which pass outwards and back-rds, forming a spout or lip, in which rests the epiglottis.

The *epiglottis* (Pl. XIX. fig. 4, 1), pot-lid cartilage, is a soft f-like flexible appendage, situated in front of the opening of larynx, which it completely closes during the passage of food ough the pharynx into the œsophagus. Its anterior surface, newhat convex, is attached to the tongue by the glosso-epi-

glottidean ligaments and to the hyoid bone by the hyo-epiglott dean muscles. The posterior surface is rough, and studded wit numerous mucous glands. The base articulates with the po terior part of the body of the thyroid. The apex is free, an recurved forwards.

The *cuneiform* cartilages, a pair, small and inconstant, co sisting of fibro-cartilage. They are irregular in shape, and sit ated in the folds of mucous membrane which stretches fro the epiglottis to the arytenoid cartilages.

The *muscles* of the *larynx* are *extrinsic*, or those which a from neighbouring parts, and *intrinsic*, or those those actin between the different cartilages. The *extrinsic* muscles a the *sterno-thyro-hyoideus* and *hyo-thyroideus*, doublets, and on single, the *hyo-epiglottideus.*

The Sterno-thyro-hyoideus is described with the muscles.

The Hyo-thyroideus is triangular (Pl. XIX. fig. 3, *b*).

Origin: The inferior border of heel of os hyoides.

Insertion: A line on external side of wing of thyroid cartilage

Action: To depress os hyoides and elevate larynx.

Hyo-epiglottideus.—Single and fusiform (Pl. XIX. fig. 3, *a*).

Origin: The body of os hyoides, enveloped in adipose tissue.

Insertion: The antero-inferior part of anterior surface of ep glottis, partly covered by mucous membrane.

Action: To draw epiglottis forwards, and thus increase th superior glossal opening.

The *intrinsic* muscles consist of four pair and three singl muscles—*crico-thyroideus; cricoarytenoideus posticus* and *late alis; thyro-arytenoideus; arytenoideus; aryteno-epiglottideus* and *thyro-epiglottideus.*

Crico-Thyroideus.—A small muscle (Pl. XIX. fig. 3, *c*).

Origin: The surface and anterior border of cricoid, passin obliquely upwards.

Insertion: Posterior border of thyroid.

Action: To contract larynx, draw the two cartilages togethe and by rotating cricoid on thyroid, to tense the vocal cords.

Crico-arytenoideus Posticus.—The most powerful of the intrinsic muscles (Pl. XIX. fig. 2, *b*).

Origin: Concavity on posterior surface of cricoid, whence its fibres converge upwards and outwards.

Insertion: Posterior tubercle of arytenoid, covered by œsophagus and crico-pharyngeus muscle.

Action: To draw the arytenoid backwards, and thus separate vocal cords and dilate glottis.

Crico-arytenoideus Lateralis is triangular, and lies between the wing of the thyroid and arytenoid cartilages (Pl. XIX. fig. 2, *c*).

Origin: Side of anterior border of cricoid, passing upwards.

Insertion: Outer tubercle of the base of arytenoid, outside of posticus.

Action: To draw the superior angles of arytenoid outwards, contract opening of glottis, and thus antagonise the posticus.

Thyro-arytenoideus.—Situated on the inner side of the wing of thyroid; consists of two bundles, separated by the ventricles of the glottis (Pl. XIX. fig. 2, *d*).

Origin: Inner surface of receding angle of thyroid, outside of the vocal cords of anterior bundle.

Insertion: The middle line at the junction of arytenoid cartilages, the ridge dividing external surface of each cartilage.

Action: To constrict glottis.

Arytenoideus is single, and situated in front of the arytenoids, stretching from one cartilage to the other, their fibres intercrossing in the mesian line (Pl. XIX. fig. 3).

Action: To approximate the cartilages, and thus constrict the posterior part of the glottis.

Aryteno-epiglottideus.—A solitary delicate muscular band.

Origin: From the arytenoids above the insertion of false cord.

Insertion: Margin of epiglottis (Pl. XIX. fig. 3).

Action: To contract superior opening of larynx.

Thyro-epiglottideus.—A small single muscle (Pl. XIX. fig. 3).

Origin: On inner surface of thyroid.

Insertion: On margin of epiglottis.

Action: To depress epiglottis.

The *ligaments* of the larynx are also *extrinsic* and *intrinsic*. The *extrinsic* are *eight—right* and *left lateral thyro-hyoid*, *middle thyro-hyoid*, three *glosso epiglottidean*, *hyo-epiglottidean*, and *crico-trocheatis*. The *lateral thyro-hyoid* pass from the superior cornua of the thyroid cartilage to the rounded extremity of the greater cornua of os hyoides. They are elastic, and have betimes embedded in them two oblong pieces of fibro-cartilage or bone the *cartilagines tritica* or sesamoid bones. The *middle thyro-hyoid ligament* is a broad membrane, filling the space between the anterior border of thyroid and the upper border of the heel like process of os hyoides, and is slit for the passage of superior laryngeal nerve and artery. The three *glosso-epiglottidean ligaments*, or frænæ epiglottidis, are folds of mucous membrane which stretch from the anterior border of epiglottis to base of tongue. The *hyo-epiglottidean* is a band of yellow elastic tissue, running between the base of the epiglottis and body of os hyoides. The *intrinsic ligaments* are the three *crico-thyroids*, *crico arytenoid*, *thyro-arytenoid*, and *thyro-epiglottidean*. The *crico thyroids* are the *crico-thyroidean*, a pyramidal or conoid ligamentous membrane, resting in the angular space between the superior border of the narrow portion of cricoid, and the inner surface of receding angle of thyroid alæ, having a firm attachment to the true vocal cords; and the *two capsular*, for articulation with the inferior cornua of thyroid and facets of cricoid. The *crico-arytenoid*, *two capsular*, for the articulations between arytenoid and cricoid, and *two ligaments*, stretching from cricoid to the posterior basilar angles of arytenoid cartilage. The thyro-arytenoid, *false vocal cords*, or superior thyro-arytenoid ligaments, stretch from the inner side of the angle to the thyroid wings to the antero-internal border of arytenoid cartilage. The *inferior thyro-arytenoidean ligaments are the true vocal cords*, and stretch from the inner side of the angle of thyroid wing below the preceding to the angle at the base of arytenoid. The *thyro-epiglottidean* consists of a long slender bundle of yellow

elastic tissue, which springs from the angle of the thyroid on one side, just above the vocal cords, winds round the apex of epiglottis, to be inserted into the angle of the thyroid on the other. The superior opening of the larynx, which communicates with the pharynx when relaxed, is lozenge-shaped, and bounded anteriorly by the epiglottis, posteriorly by the arytenoids and cornicula laryngis, laterally by the aryteno-epiglottidean folds. It becomes constricted at the base of the arytenoids, leaving a narrow fissure running antero-posteriorly, the *glottis*, which is bounded laterally by two folds of mucous membrane on each side, in which lie the superior and inferior thyro-arytenoid ligaments or vocal cords. The false *superior vocal cords* are semilunar arched, much thinner, and weaker than the true inferior, which are straight and strong. The narrow opening between the right and left true vocal cords is called the *rima glottidis* or glottis vera. Between the true and false vocal cords, on either side is a deep oval fossa, the *sinus or ventricle* of the larynx; small cul-de-sacs run up from the anterior part of these sinuses, the *sacculi laryngis* or laryngeal pouches. The inferior opening communicates with the trachea, and is nearly circular.

The mucous membrane is continuous with that of the tongue and pharynx, forming the glosso-epiglottidean folds. It is reflected over the posterior face of the epiglottis to the anterior part of the arytenoids, forming the lateral boundary of the anterior superior laryngeal opening. In these aryteno-epiglottidean folds lie the cuneiform cartilages. It now passes over the superior vocal cords, lining the ventricles and pouches. Returning over the true vocal cords, it clothes the inner surface of cricoid cartilage and middle of crico-thyroid membrane, and is prolonged into the trachea. It is very thin and exquisitively sensitive, especially about the true glottis; is covered with a ciliated epithelium, studded with mucous glands, which moisten and preserve its sensibility. These are numerous on the posterior aspect of the epiglottis, in front of the arytenoids, and in the laryngeal pouches.

The larynx is supplied with blood from the thyro-laryngeal arteries. The nerves are from the superior and inferior laryngeal branches of the vagus. The former is sensory-motor; the latter motor; twigs also come from the sympathetic.

The Trachea, or windpipe, is a cylindrical, elastic, and flexible tube, consisting of a series of incomplete cartilaginous rings. It succeeds the larynx, and terminates at the base of the heart, where it splits into the right and left bronchi. It varies in length from twenty five inches, consisting of forty or fifty rings, which overlap posteriorly, forming a perfect expansile shield. It presents a number of transverse furrows, which correspond with the interspaces between the rings. These vary in depth, averaging half an inch, and are united by strong elastic ligaments. The first is attached to the cricoid by a band called the *crico-trachealis ligament*, within the trachea. These ligaments are transverse, pale, rosy, muscular fasciculi, attached by their extremities to the inner and posterior surface of the rings, which serve to diminish the diameter of the canal. The entire trachea is lined by mucous membrane, which is continuous with, but not so sensitive as that of the larynx. It is clothed with epithelium, and studded with glands. Blood-vessels come from the carotid; the nerves from the recurrent laryngeal (Pl. XIX. fig. 6, *d*).

About the fourth tracheal ring is the brownish-red Thyroid body, consisting of two lobes joined by a narrow isthmus. Each lobe is conical, and consists of minute vesicles surrounded by a plexus of capillaries, and connected by areolar tissue. The gland is blood-vascular or ductless, being copiously supplied by branches of the carotid, and secretes an albuminous fluid, which is absorbed by the lymphatics and conveyed into the blood. It is very large in fœtal life, and its use is unknown (Pl. XIX. fig. 6, *d*).

The Thymus is another ductless gland, situated on the inferior aspect of the trachea, and above the sternum. It consists of two halves united by areolar tissue, and composed of lobules disposed round a central canal, having no external opening. Within are vesicles similar to those of the thyroid body; in the fœtus,

t is attached to the thyroid, is large at birth, gradually dis-
.ppearing (Pl. XIX. fig. 6, *e*).

The terminal branches of the trachea are the right and left
Bronchi, which enter the lungs and subdivide dichotomously into
ranches termed Bronchia or Bronchial tubes, which finally
erminate in the interlobular cellular passages or air-cells. The
ntire ramification has the appearance of a tree, the trachea being
he main trunk, the bronchi and bronchia the branches, and the
ir-cells leaves. These terminals are accompanied throughout
y the artery vein and nerve, which have the same arborescent
istribution. The right bronchus is the larger, the left the
onger, as it passes under the aorta before reaching the lung.
The bronchi and bronchial tubes are made up of cartilaginous
ings, differing only from those of the trachea in being made up
f several pieces, which overlap and are united by an investing
ellular tissue. As the tubes diminish in size, a number of
hese pieces are curtailed, ultimately disappearing. The bron-
hia, after ramifying in the lungs, terminate in small lobules
y cellular recesses or air-cells, which are isolated by septæ.
The transverse muscular bands of the trachea are continued
long the inner face of the rings of the bronchi and larger bron-
hial tubes, gradually disappearing. These tubes are lined by
mucous membrane, which is continuous with, but more sensitive
han that of the trachea. Blood is supplied by the bronchial
rteries.

At the root of each lung there are a number of absorbent
Bronchial glands. The principal ones are closely adherent to
he bifurcations of the bronchi; are oval and dark, the largest
horacic glands receiving the lymphatics from the lungs.

The Thorax, or Thoracic cavity, is formed by the ribs, ster-
um, and bodies of the dorsal vertebra, intercostal muscles, and
iaphragm; it contains the lungs, heart and its vessels, trachea,
sophagus, and a quantity of nerves; it resembles a hollow
orizontal cone, flattened from side to side. Its base, formed by
he diaphragm, is directed obliquely downwards and forwards;

it is lined by two serous membranes, the right and left pleura which consists of parietal and visceral portions forming distinct sacs. Each *pleura* lines one side of the thorax and half of the diaphragm—the *pleura-costalis* lining the ribs and intercostal spaces, the *pleura diaphragmaticus* the diaphragm. In the vertical line it is folded, forming with the opposite pleura the *mediastinum*, whence each is reflected over one-half of the lungs forming the *pleura pulmonalis*. The mediastinum is divided into three portions: the *anterior* mediastinum lies in front of the heart, the *middle* surrounds it, while the *posterior* lies behind it. Each pleura originates on the lateral aspect of the bodies of dorsal vertebræ, extends downwards over the inner surfaces of all the ribs and intercostal spaces, forming the pleura costalis, posteriorly, it passes to the anterior convex surface of the diaphragm, constituting the pleura diaphragmaticus. At the centre of the sternum, it is reflected upwards between the lungs, enclosing the pericardial sac. Gaining the root of the lungs, the parietal portion passes on to them, forming the visceral or pleura pulmonalis, clothes their free surfaces, and again on the lung root it is reflected up to the vertebra, reaching its place of origin; from the root of each lung a fold of plura extends down the sides of the posterior mediastinum to the diaphragm, forming the *broad ligament of the lung*. The pleura is thick and loosely attached over the ribs, attenuated over the diaphragm and pericardium, and extremely so on the lungs; its surface is smooth internally, emitting a vapoury fluid, which lubricates the adjacent pleura and facilitates lung play (Pl. XIX. fig. 6, *f f g g*).

The Lungs (Pl. XIX. fig. 6, *h*, *h'*, *h''*, *h'''*, *h''''*), the essential organs of respiration, are double spongy organs of a conical shape, situated in the pleural sacs, and separated by the mediastinum, heart, pericardium, and large vessels. During life, they occupy the major part of the cavity, resting on the inner surface of the walls, and adapting themselves to its varying capacity. They are attached midway by the *root*, which consists of the bronchus, pulmonary vessels, and broad ligament. Each lung

presents two surfaces, a base, and three borders. The external costal surface is convex, corresponding to the thoracic walls. The internal, or mediastinal, forms a vertical plane in contact with the mediastinum, and presents an anterior division, which rests against the anterior mediastinum, an excavation in which the heart is lodged; a second excavation is for the root of the lungs, and a broad posterior part just behind it in contact with the posterior division of the mediastinum, to which it is mesially attached by the pleura pulmonalis. Two *fissures* here present themselves, the anterior and posterior. The former crosses towards the superior border, and receives the posterior aorta; the latter, lower down, shallower, and more distinct in the left lung, is destined for the passage of œsophagus. On the inner surface of the right, there is a small lobule awanting; on the left lung, formed by a deep fissure which originates at the lung base, the vena cava passes through it, superiorly clothed with a supplementary fold of pleura, which passes up from the floor of the thorax. The concave base is sloped downwards and forwards, fitting the convex surface of the diaphragm: the fissure above noted originates there. The summit or apex lies behind the first rib, and presents a detached appendage, the anterior lobe; the superior border is round, thick, and convex, and is lodged in the channel between the rib heads and bodies of the vertebræ. The inferior is thinner and shorter, deeply cleft near the heart, more so on the left than on the right side. The posterior border is elliptical, guarded throughout by the anterior surface of the diaphragm; it separates the costal and mediastinal surfaces. The *lung substance* is light, porous, and highly elastic, possessing considerable strength. Healthy lungs float in water, and, when squeezed or cut, crepitates; when air is admitted into the thorax, they collapse. In the adult, they are rose-coloured, with a dark irregular outline caused by the lobular division producing the familiar marbling or mottling. They consist of an external serous coat, a subserous cellular layer, and the tissue proper or parenchyma. The

serous coat is the pleura pulmonalis. The sub-serous layer composed of cellular tissue, intermixed with yellow elastic fibre It clothes the entire lung surface, and is continuous with th interlobular cellular tissue. The parenchyma is formed of man polyhedral lobules of various sizes, united by areolar tissue these are again made up of smaller ones, which are composed o the ramification of the bronchial tube and its terminal air cell in the walls of which lie the capillary vessels uniting the pul monary arteries with the pulmonary veins. Each larger lobul is provided with its own bronchial tube and air-cells, functiona and nutritive vessels, lymphatics, nerves, and interstitial cellula tissue enveloped in its own investing membrane. The inter lobular cellular tissue is very fine and continuous, with the sub serous layer; the lobular division is constant in all mammiferou animals. In the Horse it is less distinct than in ruminants where there is a larger amount of interlobular cellular tissue, ai escaping into which, after rupture of the cell-wall, constitute *interlobular emphysema*, or *broken wind*. The pneumonic func tional vessels are the pulmonary artery and vein. The artery conveys venous blood from the heart to the lungs. At the lung root, it divides into right and left branches, which are dis tributed to their respective lungs in company with the ramifying bronchial tubes, terminating in a capillary net-work around the terminal air-cells, whence arises the radicles of the pulmonary veins, which return the purified blood from the lungs to the heart. The nutritive vessels are the bronchial arteries and veins The artery is a branch of the posterior aorta. Its branches are smaller than the pulmonary, and also accompany the division of the air-tubes. Blood is returned by the bronchial and pul monary veins. The pulmonary lymphatics are numerous, and divided into superficial and deep. The former are situated in the sub-serous layer, forming a net-work; the latter, in the inter lobular tissue. Both communicate at the lung roots, and pass through the bronchial glands. The nerves are from the pul monary plexus, formed by the vagus and sympathetic.

Comparative Anatomy.—The lungs of Ruminants are remarkable for the extreme development of cellular tissue in their structure, and differ from those of the horse. The left lung is divided into two distinct lobes, and the right into four, the anterior one recurving over and almost covering the front of the heart. In the Ox and Sheep the sub-serous, as well as the interlobular cellular tissue, is very thick, the lobules being distinctly visible. *This distinctive conformation explains the peculiarity of inflammatory diseases of the lungs in those animals.* The lungs of the Pig closely resemble those of the ox. In the Dog the left lung has three lobes; the right four, which are separated by deep fissures, extending almost to the root of the lung.

The organs of respiration in Birds is interesting. The nasal openings are very small, but may be wide or awanting, placed on either side of the bill or at its base, surrounded by naked skin, a few feathers or even scales, which form alæ or wings, and open into the pharynx by two distinct apertures, which lie closely together. The air-passages present a superior larynx, trachea, inferior larynx, lungs, and air-sacs. The superior larynx is situated just behind the roof of the tongue, opening by a longitudinal slit. It consists of several bony or cartilaginous pieces, varying in number, joined by membranes and moved by muscles. The trachea winds down the neck as a single tube, composed of complete bony or cartilaginous rings, not overlapping, as in mammalia. They are round or compressed, varying in diameter. The second or inferior larynx is the organ of sound, and is best developed in song birds, varying in form and structure in different kinds of birds. In song birds it has well-developed muscles, which regulate the diameter. At its origin is a membranous tongue, composed of a doubling of lining membrane. The free portion is directed upwards, and the motion of which regulates sound. The tube divides into a pair of bronchi, which lead to the lungs. These consist of incomplete segments of bone or cartilage, completed by membrane. The lungs are spongy, bright red, long, flat, oval, and

applied against the sides of the vertebræ and ribs, to which th
are attached by cellular tissue. They present several openin
on their surfaces, which communicate with air-sacs hollow
out in the cellular tissue of the body. These sacs are conti
uous with the interior of long bones, which thus receive
constant supply of air. There are usually fifteen pair of sac
viz., inter-clavicular or cervical, anterior and lateral thoraci
diaphragmatic or hepatic, and abdominal. By means of thes
air penetrates every part of the body, enabling respiration t
proceed with great activity. Some of the blood being always i
contact with air, a high temperature persists in the sacs.

ORGANS OF CIRCULATION.

Blood nourishes all living tissue, and is the medium by whic
effete material is returned. Its physical character varies i
different animals—in vertebrata it is reddish, in invertebrat
almost colourless, with a blue, green, or yellow tint. It is a
opaque, thickish, clammy fluid, with a peculiar odour, sickl
saline taste, and alkaline reaction. Its specific gravity rang
from 1052 to 1057, its temperature, when living, from 97° t
100° Fahr. Its odour varies with the animal and sex; its shad
in different parts of the same animal, arteries being bright re
or scarlet, veins of a dark purple hue. When examined with
microscope, it is found to consist of minute blood globules and
clear transparent yellow liquor sanguinis, serum or plasma, i
which the corpuscles float. These are of two kinds, red, an
white or colourless; the former, most numerous and important
exist in the proportion of about 50 to 1. *Red corpuscles* var
in shape, but in all animals are more or less discord, the camel
idæ excepted, where they are circular; in birds, reptiles, and fis
they are oval or elliptical. Their average diameter in the horse
ox, or sheep is about $\frac{1}{3000}$th part of an inch, their average thick
ness about $\frac{1}{4}$ of this. The shape of the corpuscles allow them t
circulate more freely than if they were perfectly spherical. Th

white corpuscles float at the sides of the blood stream, the red in the centre. The *liquor sanguinis* is pale and clear, and consists of water, fibrin, albumen, fatty compounds, extracts, odoriferous and saline matters. Withdrawn from the circulation, and left to itself, blood changes into a gelatinous mass, which gradually separates into two parts, one a yellowish straw-coloured fluid or *serum*, the other a solid red portion—*crassamentum* or *clot*. The *serum* is a thin, transparent liquid, of a pale straw or yellow colour, with a specific gravity of about 1025. It is composed of 90 per cent. of water, is always slightly alkaline, and coagulates when heated, owing to the large quantity of albumen it contains. *Fibrin* is a white, stringy, elastic substance, which, when the blood is in circulation, is liquid, and cannot be distinguished from the other constituents of the plasma. When the blood is withdrawn from the system, it becomes semi-solid. It decreases in disease of a low typhoid nature, but *increases in rinderpest.*

In studying the organs of circulation, four groups of organs must be considered—the *heart*, or central organ of circulation; the *arteries*, which convey the blood to different organs; the *veins*, which return it to the heart; and the *capillaries*, minute intermediate vessels which connect the arteries and veins.

The Pericardium (Pl. XX. fig. 3, *a a*) is a fibro-serous conical sac, which encloses the heart and origin of the large vessels. It consists of a parietal and visceral portion, and is composed of two membranous layers—one external, dense, and fibrous, the other internal and serous. The outer fibrous layer only enters into the formation of the sac or free portion of the pericardium, having no direct attachment to the heart itself. It is made up of fibres, which interlace each other and form a sac, whose apex is continued on the larger blood-vessels as tubular prolongations. The basal fibres of the membrane blend with those of the diaphragm, and are also attached to the last bone of the sternum and ensiform cartilage, covered by the pleura. The serous layer is much larger than, and lines the fibrous. It is reflected over the origin

of the blood-vessels and external surface of the heart, forming close sac. Between the parietal and visceral layers, is secreted pale yellow serous fluid, the *liquor pericardii*, which prevents friction and facilitates motion. The pericardium suspends the heart, and insulates it from the other thoracic viscera.

The Heart is a hollow involuntary muscular organ, situated in the thorax between the lungs, between the layers of the pleura which constitute the mediastinum, and in the membranous pericardium, to a reflection of which it owes its external smooth glistening aspect. Its form is that of a blunt cone, slightly flattened from side to side, and consists of base and apex. The former is turned upwards, and extends from the third to the fourth dorsal vertebra, from which it is suspended by the vessels that spring from it; the latter points downwards, backwards and to the left side, hanging about the junction of the diaphragm with the last bone of the sternum; the body responds to the ribs from 3 to 6. The weight of the horse's heart is about 6 pounds, its length from base to apex about 8 inches, its antero posterior diameter about the same, its lateral diameter somewhat less.

The heart is divided by a longitudinal septum into right and left, or anterior and posterior. Each is again subdivided by a transverse constriction into two compartments, which communicate. The superior ones, resembling a dog's ear, are called *auricles;* the inferior, *ventricles*. The subdivisions are marked externally by deep grooves, in which the blood-vessels run. These are generally filled with fat. The anterior and posterior longitudinal grooves extend from the base of ventricles to the apex of heart, and correspond with the internal septum. They are called the *anterior* and *posterior longitudinal furrows*. At the base of the ventricles is a deep transverse groove, the *auriculo-ventricular*, which divides it into an upper or auricular heart and a lower or ventricular one.

Course of the Circulation.—The heart, then, is a double organ, consisting of a right and left portion. The right is

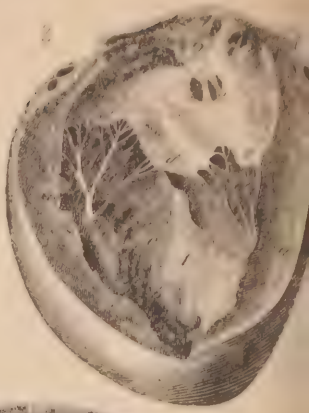

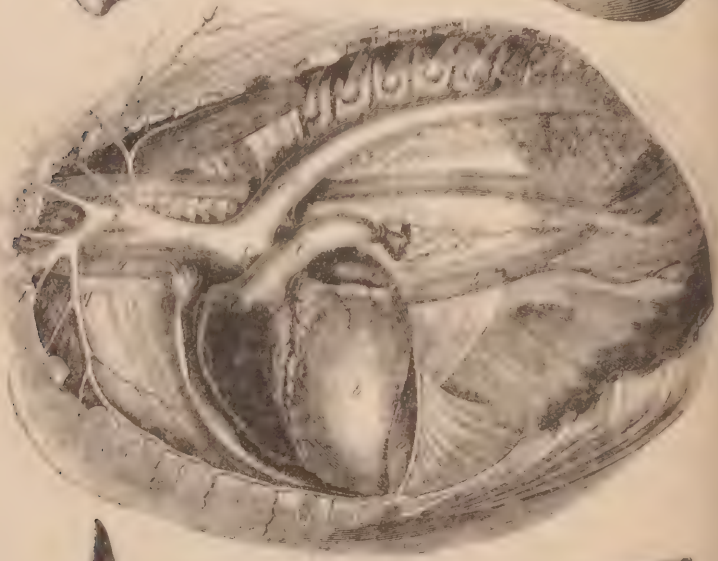

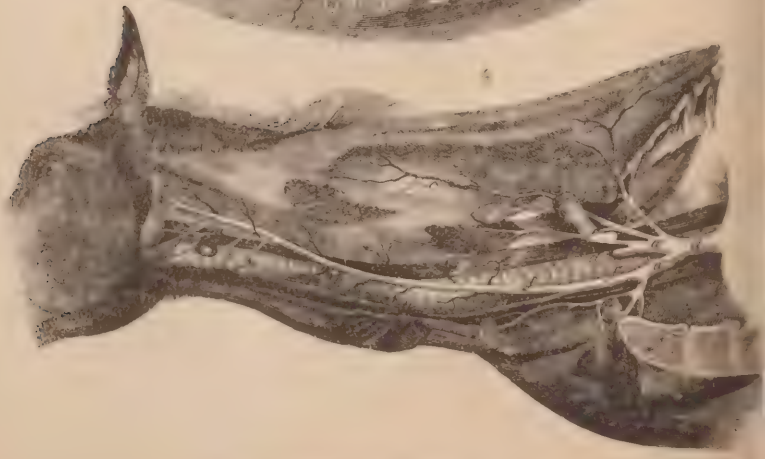

PLATE XX.

CIRCULATORY ORGANS—ARTERIES.

Fig. 1.—The Heart, with the Right Auricle and Ventricle opened.

1. Right ventricle opened. *a a*. The lateral wall divided and thrown back. *b b*. Fleshy bands with depressions between them. *d*. Opening of pulmonary artery. *c c c*. Its semilunar valves. 2. Right auricle opened. *a a*. Fleshy bands and depressions. *b*. Opening of anterior vena cava. *c*. Opening of posterior vena cava.

Fig. 2.—Heart, with Left Auricle and Ventricle opened.

1. Ventricle opened. *a a*. Its lateral wall cut through and thrown back. *b*. Fleshy bands and depressions. *c*. A transverse band. *d d d*. Mitral valve. *d' d'*. Tendons of the valve. 2. Left auricle opened. *a*. Fleshy bundles and depressions. *b*. Openings of pulmonary veins.

Fig. 3.—Heart, with large Vascular Trunks seen in position. The Chest is opened from the left side.

a a. Pericardium opened. *b*. Left ventricle. *c*. Right ventricle. *d*. Left coronary artery. *e*. Aorta. *e'*. Anterior aorta. *e''*. Posterior aorta. *f*. Pulmonary artery ligatured. *g*. Anterior vena cava. *h*. Posterior vena cava. *i*. Innominate artery. *k*. Left axillary artery. *l*. Left dorsal artery. *m*. Left superior cervical artery. *n*. Left vertebral artery. *o*. Left inferior cervical artery. *p*. Left external mammary artery. *q*. Left internal mammary artery.

Fig. 4.—Arteries of the Left Side of the Neck exposed.

a. Anterior aorta. *a'*. Left subclavian artery. *a''*. Right innominate artery. *b*. Left dorsal artery. *c c*. Left superior cervical artery. *d*. Left vertebral artery. *e*. Right inferior cervical artery. *f*. Common carotid trunk. *f'*. Left carotid artery. *f''*. Right carotid artery. *g g*. Œsophageal branches. *h h*. Tracheal branches. *i i*. Muscular branches. *k*. Inferior thyroid artery. *l*. Superior thyroid artery. *m*. Inferior parotid artery.

enous, the left arterial. The venous blood is carried into he right auricle by the anterior and posterior venæ cavæ. It hen passes through the right auriculo-ventricular opening into he right ventricle; thence through the pulmonary arteries to he lungs. It returns by the pulmonary veins to the left uricle; thence to the left ventricle, which propels it through he aorta and its branches into the system; the veins returning t to the heart. The circulation is double—the pulmonary or esser being performed by the right, and the somatic or greater by the left, side.

We consider *seriatim* the cavities of the heart according with the course of the blood.

The RIGHT AURICLE (Pl. XX. fig. 1, 2, *a a*, *b*, *c*) is the larger, nd forms the right anterior base. It consists of two cavities. The *sinus venosus* or principal cavity is quadrangular, and occupies the space between the venæ cavæ, receiving blood rom these vessels. Its walls are thin, and connected inferiorly with the right ventricle; internally, with the right auricle; nteriorly, it is prolonged to the proper auricle, its remaining surface being free. The *appendix auriculæ*, or proper auricle, s a small conical pouch, which projects forwards from the sinus between the aorta, supero-anterior part, and the right ventricle. Its walls are thick, and its edges, more particularly he outer, serrated. On laying open the interior, which is best done by a longitudinal incision from the appendix to he mouth of the posterior cava, then opening the anterior cava, and connecting the incisions, the smooth transparent endocardium, anterior and posterior venæ cavæ, coronary sinus, foramina Thebesii, and right auriculo-ventricular openings are displayed. The *anterior vena cava* returns the blood from he anterior part of the body, and opens into the supero-posterior part of the sinus venosus. The *posterior cava*, which returns the blood from the posterior of the body, opens into he postero-inferior part of the external wall of the sinus, near he auricular septum. The *coronary sinus*, the diluted termi-

nation of coronary veins, is situated below the opening of t
posterior cava, between it and auriculo-ventricular openi
Through it the blood is returned by the coronary veins, fr
the substance of the heart. The *foramina Thebesii* are min
openings on the inner surface of the auricle. Some of these a
mere depressions, whilst others are the openings of minute vei
—*venæ cordis minimæ*—which return blood directly on t
substance of the walls. The *right auriculo-ventricular openi*
is a large oval aperture, occupying the entire floor of the auric
It communicates with the right ventricle. The *tuberculu*
Lowerii is a slight projection situated between the openings
the cavæ, and is supposed to direct the blood from anteri
cavæ into the auriculo ventricular opening. The remains of t
Eustachian valve is situated at the anterior margin of the p
terior cava, stretching from it to the left side of the *annul*
ovalis. It is simply a semilunar doubling of the lining mem
brane, its convex border being attached to the walls of t
venæ cavæ, its concave one being free. It terminates in tw
horns—the left being attached to the annulus ovalis, the rig
to the wall of the auricle. The convex surface looks to t
wall of the auricle, the concave one to the opening of the vei
It is largest in the fœtus, serving to direct the blood from t
vein to the foramen ovale. In the adult it is generally sma
and imperfect, frequently cribriform or awanting. The *coron*
valve or *valvula Thebesii*, is a fold of the endocardium, and m
be double. It covers the coronary sinus, preventing regurgit
tion during the contraction of the auricle. The *fossa ova*
vel *vestigium foraminis ovalis* is an oval depression, the remai
of the fœtal foramen. At birth this opening is closed. Som
times it remains patent, producing *cyanosis*, the animal bein
of a blue tint, owing to the admixture of arterial with veno
blood. This fossa, situated on the septum auriculæ, is smoot
sometimes reticulated. Its lower borders are indistinct; i
upper thick and projecting, forming the *annulus ovalis* o
isthmus Vieussenii, which is most decided above the fossa. Th

musculi pectinati are columns of muscular fibres which cross the inner anterior surface of the auricle to the edges of the auriculo-ventricular opening. They abound in the appendix, and are called pectinati, from their resemblance to the teeth of the comb. Smaller bundles cross the large ones, giving the whole a reticulated appearance, between which are cul-de-sacs, which vary in size.

The blood leaves the right auricle through the auriculo-ventricular opening, and enters the RIGHT VENTRICLE, which occupies the antero-inferior part of the right heart. It is somewhat conical, with its base uppermost, and extends from the auricular furrow to near the apex. Its outer walls, although thicker than the auricle, are thinner than the left ventricle. The inner wall is convex, and formed by the ventricular septum; on laying it open, by an incision along its right edge, and a second one from the root of the pulmonary artery, joining the other at the apex, two openings present themselves.

The *auriculo-ventricular* is the large oval opening, situated at the base of the ventricle. It communicates with the auricle, and is guarded by the *tricuspid valve*, which is formed by a redoublicature of the endocardium, strengthened by an intermediate layer of fibrous tissue. It consists of three triangular segments, which, connected at their bases, ring the auricular opening. The flaps are attached to each other for a short distance, their apices freely project into the cavity of the ventricle; the largest is placed between the auriculo-ventricular and the opening of pulmonary artery, a second rests against the septum of the ventricles, the third between the other two; the free edges of these flaps are clothed by tubercles. To their ventricular surfaces and free margins are attached a number of delicate tendinous cords, or *chordæ tendineæ*, which spring from the inner surfaces of the ventricle. The majority of these arise from the free blunt extremities of a variety of *carneæ columnæ*, the *musculi papillares;* the remainder from the walls of the ventricle. The chordæ tendineæ diverge, subdivide, and cross. Some terminate

in the free margins and apices of the flaps, others in t
central thick portion; while a few reach the attached borde
and become continuous with the fibrous ring of the auricu
ventricular opening. This valve prevents the regurgitation
blood into the auricle when the ventricle contracts.

The second opening in the right ventricle is the origin of t
pulmonary artery. It is situated above and to the left of t
auriculo-ventricular opening, is circular, and arises from t
summit of a conical prolongation called the *conus arteriosus*,
infundibulum, whose smooth inner surface is destitute of carn
columnæ. The entrance of the pulmonary artery is guarded
three *semilunar* or *sigmoid valves*, which consist of semicircul
folds of the lining membrane; they are transparent, and
tached by their convex margins to the tendinous ring whi
surrounds the origin of the artery. Their free edges are almo
straight, and thinner than the attached ones, presenting a mes
triangular tubercle, the *corpus aurantii*, or *corpusculum Morgagn*
When blood passes from the ventricle to the pulmonary arte
the valves are laid against the sides of the vessel; when t
current is checked, a portion of it falls back towards the ve
tricle, and the valves are now thrown inwards, overlap, and co
pletely close the tube. When the valves are shut, the surfac
next the vessel are concave, the ventricular one convex.

The *corpora aurantii* are said to fill up triangular spa
that would otherwise be left in the axis of the canal by t
meeting of the circular valves; but these bodies are frequen
indistinct, especially in the pulmonary artery, and rarely proj
beyond the free margins of the valves. Behind each valve,
the commencement of the artery, is a dilatation or pouch, m
apparent in old animals, the *sinuses of Valsalva*.

From the inner surface of the ventricular walls project fles
columns, or *carneæ columnæ*. They are of three kinds, attac
by their external surface and extremities, their internal surfa
being free, forming prominent ridges attached by both or o
one extremity, betimes dividing and subdividing; they termin

a short blunt processes. The last variety, three or four in umber, constitute the *musculi papillares*, whence the chordæ endineæ spring. These carneæ columnæ form an intricate net-ork on the inner surface of the ventricle, occasionally crossing ; ne cavities near the apex forming what are called the moderator ands.

The blood, after being purified in the lungs, re-enters the heart t the LEFT AURICLE (Pl. XX. fig. 2, 2, *a*, *b*), which is smaller an the right ; its walls are, however, thicker. It is situated at ne left postero-superior part of the heart, and consists of two arts, a *sinus* and *auricular appendix*. The sinus is separated om the right one by the auricular septum. The *appendix* is nger, narrower, more curved and serrated than the right one, nstricted at its junction with the sinus. It is the only portion f the auricle visible when the heart is removed. It runs along ne left side of the origin of the pulmonary artery, which separates from the right. On laying open the cavity, we find the *open-ngs of the pulmonary veins*, usually two pair, one pair on the ght, the other on the left of the sinus, separated from each other y the breadth of the auricle ; they are not guarded by valves. he remaining opening in the left auricle is the *auriculo-ventri-lar*, which occupies the floor, and communicates with the left ntricle, its upper margin being surrounded by a white tendinous ng. The *vestigium foraminis ovalis* on the septum is indistinct. t the upper part of the fossa there is often an oblique slit, which mmunicates with the right ventricle, which from its valvular xture quite prevents any admixture of blood. The inner surface this auricle is much smoother than the other, the musculi pec-nati fewer, and confined to the appendix. The *appendix* com-unicates with the sinus, through a round constricted opening. The blood leaving the left auricle enters the LEFT VENTRICLE l. XX. fig. 2, 1, *a*, *a*, *b*, *c* ; *d*, *d*, *d* ; *d'* *d'* ; fig. 3, *b*), which conical, and occupies the posterior left of the heart. It is nger, rounder, and more prominent than the right, extend-g from the auricle to the apex, which it forms, projecting

beyond the right. The external walls are thicker than the rig
the base and apex thinner than the centre, those of the ap
being the weakest. After death, the walls of this cavity rema
apart, those of the right collapsing; on laying open the cavi
by an incision close upon the anterior fissure, from the apex
near the origin of aorta, and another from the base midw
between the posterior fissure and left edge of the ventricle to t
apex, meeting the first, two openings present themselves, t
left auriculo-ventricular and the aortic. The *left auriculo-ve*
tricular is guarded by a valve with two flaps, the *bicuspid*
mitral. These consist of doublings of the lining membran
strengthened with fibrous tissue, and, according to some, by mu
cular fibre. One flap rests between the auriculo-ventricular an
aortic opening; the other, larger and freer, is opposite. The
ring the opening, their sides being attached for a short distanc
their apices more separate. The musculi papillares of the le
side are two, corresponding to the valve segments. They a
large and prominent, one anterior, the other posterior, near i
junction with the septum. The chordæ tendineæ are fe
stronger, and more powerful than those of the right; they a
attached to the flaps in a similar manner, and spring fro
prolongations of the musculi papillares.

The *aortic opening* is situated at the root of the sinus in th
supra-anterior part of the ventricle, a little to the right of t
auriculo-ventricular opening, from which it is separated by o
of the segments of the mitral valve. It is guarded by three sem
lunars, which are similar in shape and appearance, but thick
and stronger than the right; the corpora aurantii are larg
and better developed, the sinuses of Valsalva deeper. From tw
of them spring the coronary arteries, which supply the hea
with blood.

The *septum of the ventricles* is triangular, and extends to t
apex of the heart. It is thick at the base, thinner at the ape
convex in the right ventricle, concave in the left.

The cavities of the heart are all lined by the serous endoc

lium, which is continuous with the lining membrane of the blood-vessels. It is thin, smooth, and glistening, giving to the inside of the heart its polished appearance, to which it adheres by cellular tissue. It enters into the formation of the valves; is thickest in the auricles, and more opaque on the right side.

The heart consists of muscular and tendinous textures, cellular tissue, blood-vessels, nerves, and lymphatics, the whole being covered by one, and the cavities lined by another, serous membrane. The *tendinous texture* is placed around the auriculo-ventricular and arterial openings, within the doubling of lining membrane, which forms the valves and chordæ tendineæ. These are strongly developed on the left side. The *auriculo-ventricular rings* divide the heart into two distinct parts, an auricular and ventricular part. These are thicker on their lower edge, whence spring the muscular fibres of the ventricles, the mitral and tricuspid valves. From the upper edge arise the muscular fibres of the auricles. The right margin of the left auriculo-ventricular ring is connected with the ring surrounding the aortic opening. Between the aortic ring and auriculo-ventricular openings, is a fibro-cartilaginous mass, connected with the several rings to which the muscular fibres is attached, which in the Ox is replaced by a triangular bone or *os cordis*. A second bone is sometimes found between the pulmonic and auriculo-ventricular rings. The arterial tendinous rings gird the arterial openings, and serve for the attachment of the vessels, semilunar valves, and some of the ventricular muscular fibres. They seem to consist of three semilunar portions united, which gives them a festooned border, to which is attached the middle coat of the artery. The other edge is straight, affording attachment to the muscular fasciculi of the ventricles.

The mass of the heart is composed of *complex muscular fibres*, connected by filamentous areolar tissue. These fibres are involuntary, and of a deep red colour, differing from other involuntary muscles, the œsophagus excepted, in being transversely and longitudinally situated. They are smaller than

voluntary fibre, and so interwoven as to appear anastomati
The *muscular fibres of the auricles* are distinct, and arrange
into superficial and deep; the former common to both auricles
the latter proper to each. The superficial, common, or trans
verse fibres surround the base of the auricles, and are mos
abundant on their anterior part. They cross from one auricle t
the other, diverging to enclose the appendices and the opening
of the large veins. They are also prolonged into the auricula
septum, to assist in forming the circular band which surround
the fossa ovalis. The deep fibres proper to each auricle con
sist of two sets, looped and annular, which are superficia
when the external circular fibres are deficient. The loope
fibres are attached by their extremities to the auriculo ventricu
lar tendinous rings; passing over, they embrace each auricle
forming right and left loops. The annular fibres are arranged i
rings, forming a continuous layer. They abound in the appen
dices, are scant over the sinuses, and again abundant around th
coronary sinus and pulmonary veins, extending some distance
along the course of the cavæ and pulmonaries. Like the muscu
lar fibres of the auricles, they are arranged in two sets, one com
mon to both, and another proper to each ventricle, thus formin
as it were two muscular sacs enclosed in a third. The fibres
whether common or proper, are attached directly or indirectly b
both extremities to the tendinous rings at the auriculo ventricu
lar and arterial openings. The common fibres are arranged i
successive layers, arising from the auriculo-ventricular ring. The
extend spirally from above downwards on the anterior surface
from right to left, on the posterior from left to right. They ar
thin and broad at the upper part of the ventricles, becomin
thick and narrow as they reach the apex, where they encoi
forming a whorl, then penetrate beneath the layers, and pass u
the anterior of the ventricles, forming walls, septum, &c., te
minating on the auriculo-ventricular ring. The common fibre
form a superficial set, passing downwards, and a deep set re
flected upwards, between which are enclosed those special t

ach ventricle. The deep fibres form circular or curved bands, ome common, others special. Some of the circular fibres form mbricated bands, the lower one disappearing internally below he higher. They are inserted by both extremities into tenlinous rings.

The heart is supplied with blood by the coronary arteries vhich arise from the sinuses of Valsalva. The blood is returned y the coronary veins which pass to the coronary sinus and venæ ordis minimæ, which terminate in the foramina Thebesii. The ierves of the heart come chiefly from the sympathetic ganglia, runk, and recurrent branch of the vagus. The lymphatics are livided into superficial and deep; the former lie below the periardium, the latter below the endocardium. They follow the ourse of the veins, and terminate either in the thoracic duct or ight lymphatic vein.

ARTERIES.

General Anatomy.—The systemic and pulmonic arteries eave the heart by a single trunk, which subdivide and terminate n capillaries, whence the venous radicles originate. The volume of the secondary arteries exceeds that of the primitive trunk, and similar relations exist between the dimensions of the branches and their ramifications, as far as the ultimate divisions of the artery, the volume of the canal increasing to its termination. Arterial branches arise at variable angles—at right in the lumbar arteries, obtuse in the superior intercostals, and acute in the spermatic arteries. The originating angle exerts a decided influence over the course, and a velocity of the circulation. Blood passing from a primary through the opening of a secondary vessel which arises from it at an obtuse angle, must have its speed slackened; on the contrary, the velocity is not modified in vessels which eave the parent trunks at a very acute angle. In the interior of arteries, there is a special mechanical contrivance for facilitating or retarding the passage of blood. On a portion of the circum-

ference of the main artery, at the opening of a branch, there is nearest the heart, a channel-like slope into the branch, and a the side of the opening most remote from the heart, a ridge o semilunar valve, consisting of a doubling of the inner with a portion of the middle tunic; the ridge increases with the acute ness of the angle. Branches given off at an obtuse angle have this valve on the side of the opening nearest the heart, thus pre venting too great rush of blood into the branch.

The large arteries have a peculiar tendency to leave the super ficies, and pass to deep-seated parts, where they are less exposed to injury. They occupy the cavities of the trunk and the deep interstices of the inner surfaces of limbs. When they pass over an articulation, they are always found on the flexor side. In general, the direction of the larger arteries is perfectly straight; in some parts they are tortuous, as in the stomach, intestines bladder, uterus, and lips; in fact, wherever the circulation might be interrupted by sudden functional change in the form or volume of the organ. Sometimes this tortuosity is assumed for the purpose of breaking the impulse, thus moderating the energy with which the fluid is propelled into delicate structures, such as the brain and testicle; small arteries which run amongst loose structures, generally become tortuous during the contrac tion of the left ventricle. Arteries freely communicate with each other, forming *anastomoses*—by *convergence*, where two branches join at an acute angle to constitute a single trunk, as the vertebrals to form the basilar; by *inosculation*, where two vessels of nearly equal size form an arch from which spring smaller vessels, as in the arteries of the intestines, and the neighbourhood of joints; by *transverse branches*, where two parallel arteries are joined by a small communicating transverse as between the umbilicals as they approach the placenta. In the smaller arteries, anastomoses are frequent in the capillaries they form a close net-work which pervades almost every tissue of the body. They are of great importance, circulation being carried on by them after the main artery has been obliterated.

The smaller arteries terminate in a system of minute vessels—
ne *capillaries*. They are interposed between the termination of
ne arteries and the commencement of the veins. Their average
ameter is $\frac{1}{3000}$th of an inch, varying in different textures,
mallest in the brain and mucous membrane of the intestines,
rgest in the skin and interior of bones. All arteries do not
rminate in capillaries, the exception being in erectile tissue,
here they end in cells placed at the origin of veins.

Arteries are dense and elastic, possessing great power of resist-
nce. When empty, they are of a pale buff colour, and preserve
heir cylindrical form. Their walls consist of three tunics—an
nternal, middle, and external. The *internal serous*, or *tunica
ntima*, is the thinnest, and continuous with the lining membrane
f the heart. It is made up of two layers—an inner, consisting
f a layer of epithelial scales; and an outer, transparent, whitish,
ighly elastic, and perforated. When the artery is empty, it is
hrown into folds longitudinal in the large; transverse in the
nall arteries, and, when distended, it is smooth, glistening, and
ighly polished. The *tunica cellularis*, or *contractile middle coat*,
s elastic, dense, and of a reddish-yellow colour, consisting of
on-striated, muscular, and elastic fibres; thickest in the larger
rteries, it thins out in the smaller. The *tunica cellularis, pro-
ria*, or *external coat*, is made up of areolar tissue and elastic
bres, very thin in the large, as thick as the middle coat in the
naller, while in the smallest arteries it is awanting. The ex-
erior surface is loose, and connected by laminæ to the sheath.
he arteries of the brain and spinal cord have very thin
unics.

The *arterial sheaths* consist of cellular tissue intimately con-
ected with the surrounding textures. The artery has only a
oose attachment to the sheath, so as to allow of free gliding on
ts inner surface. Owing to this loose attachment and contrac-
ility of the artery when cut across, it retracts into the sheath
nd prevents hæmorrhage. Arteries are usually accompanied by
vein, which may be enclosed in the same sheath; it is, how-

ever, generally placed beneath it, the vein being most superfi cial. Sometimes an artery is accompanied by two veins, in whic case the artery is as a rule central. Arteries are generally ac companied by a nerve, which may lie in the same sheath; the are supplied with nutrient blood-vessels, the *vasa vasorum* which come from neighbouring vessels, and ramify in the loos areolar tissue which connects the artery to the sheath; they ca be traced into the middle tunic, but do not penetrate the inne coat; they are also provided with absorbents, which are only visible on the larger trunks, and plentifully supplied with nerves chiefly by the sympathetic, which form intimate plexuses on th large, the smaller ones being accompanied by single filaments The cerebral and umbilical arteries are supposed to be nerve less. The physical properties of arteries are firmness, power o resistance, and elasticity: the former chiefly resides in th middle tunic, to which they owe their circular form. Whe empty, their power of resistance is due to the external an middle coats in the longitudinal, to the outer coat in a circula direction. The external coat is very tough, while the middl and internal are very brittle. On ligaturing an artery, the in ternal and middle coats give way, while the external one is lef unbroken. To the power of resistance possessed by the externa coat, we are enabled to stop haemorrhage by torsion, the middl and internal coats giving way in several places; the external which remains unbroken, forming a spiral ligature round th others so tight that it cannot be unravelled by twisting in a opposite direction. In studying the arteries we consider thei *situation*, *direction*, *relation*, and *anastomoses*.

ARTERIAL SYSTEM.

The Pulmonary artery (Pl. XX. fig. 3, *f*) springs from th conus arteriosus of the right ventricle, curves upwards and back wards until it reaches the upper part of the left auricle, where i divides into *right* and *left*, which penetrate the substance of thei

spective lungs along with the bronchii, ramifying in its substance along with the bronchial tubes. They subdivide more frequently than the tubes, terminating by capillary branches, which form a dense net-work on the walls of the smallest bronchial and air cells beneath the mucous membrane; the branches are independent in the different lobules, and do not anastomose; from these capillaries spring the radicles of the pulmonary veins. The pulmonary at its origin is joined by its right side to the aorta, the vessels being enclosed in a serous tube formed by a continuation of the visceral layer of the pericardium. Above this is attached the fibrous layer of the same membrane, which is carried forwards for a short distance as a tubular sheath; it is related on its right with the aorta, being flanked on each inferior side by the two auricles; it is likewise related to the vessels springing from the heart. About its centre, it is united to the posterior aorta by a short dense fibrous cord, the remains of the fœtal ductus arteriosus; its walls are thinner than the aorta. The pulmonary is the only artery that conveys venous blood.

The Aorta (Pl. XX. fig. 3, *e;* fig. 4, *a*) is the main trunk of the arterial system. It arises from the supero-anterior part of the left ventricle, being attached to the aortic fibrous ring; it passes upwards and forwards for three inches, then divides into two, the *anterior* and *posterior aorta*—the former supplying the fore extremity and head, the latter the trunk and posterior part of the body; its superior part is on a line with the third dorsal vertebra. The aorta has on its right side the right auricle, and on its left the pulmonary artery, to which it is joined by cellular tissue, the two lying in one sheath. The trunk is transversed by the cardiac nerves. In addition to its terminal divisions, the aorta gives off the *right* and *left coronary arteries.* The right arises from one of the sinuses of Valsalva, at the antero-inferior part of the aorta; thence it passes to the right of the pulmonary artery under the right auricle, and along the auriculo-ventricular furrow; on reaching the right longitudinal furrow, it divides into vertical and transverse branches. The vertical

descends the right longitudinal furrow, yielding branches to th ventricular walls, rounds the apex, and anastomoses by co vergence with the corresponding left branch; the small trans verse branch passes along the transverse furrow, anastomosin with its fellow. The left coronary artery arises as the righ passing out behind and between the pulmonary and apex of th left auricular appendix, and immediately divides into vertica and transverse, with a distribution similar to the right one.

The Posterior aorta (Pl. XXII. fig 1, *a*, *a*; fig. 2, I.) i larger and longer than the anterior. It commences at the fourt dorsal vertebra, arches upwards and backwards, reaching th left side of the spine opposite the seventh dorsal vertebra thence along it to the hiatus aorticus, entering the abdome between the pillars of the diaphragm, and terminating in th external and internal iliacs. It is divided into thoracic an abdominal. The arch of the *thoracic* is crossed on the right b the trachea and œsophagus, having the pulmonary artery o the left; along the spine it lies in the posterior mediastinum guarded on the right by the œsophagus and vena azygos, on th left by the thoracic duct. The *abdominal* is embraced by twig of the sympathetic nerve, with the reservoir of Pecquet above and the posterior vena cava to its right. The posterior aort furnishes parietal and visceral branches.

The *parietal* consists of posterior intercostal, phrenic, an middle sacral.

The Posterior intercostals (Pl. XXII. fig. 1, *d*, *d*) ar doublets seventeen in number, thirteen of which spring fro the aorta, the first arising from the superior cervical, the nex three from the dorsal branches of arteria innominata. The leave the superior part of the trunk at right angles, skirt th dorsal vertebræ, and at the upper margin of the intercosta spaces divide into inferior or intercostal and superior or dorso spinal. The *intercostal* branch is the larger, and travels in th grooved posterior border of the rib to the front of the thorax associated with the vein and nerve. The anterior nine anasto

III.
II.

PLATE XXII.

CIRCULATORY ORGANS—ARTERIES.

Fig. 1.—Thoracic Portion of Posterior Aorta, with the Vessels arising from it.

(The Cavity of the Chest is opened from the Left Side.)

a a. Thoracic portion of posterior aorta. *b*. Bronchial artery. *c*. Œsophageal artery. *d d*. Intercostal arteries. *e*. Anterior phrenic arteries.

Fig. 2.—Branches of Abdominal Portion of Posterior Aorta.

(The Abdominal Cavity is opened from the Left Side, and the Diaphragm on this side removed.)

I. Aorta. II. Liver. III. Stomach. IV. Spleen. V. Left kidney (depending). VI. Rectum. 1. Cæliac artery. *a*. Coronary artery of stomach. *a'*. Its superior branch. *a''*. Its inferior branch. *a'''*. Its œsophageal branch. *b b*. Hepatic artery. *b'*. Pyloric artery. *b''*. Duodenal artery. *b'''*. Right gastro-epiploic artery. *c c*. Splenic artery. *c'*. Branch to the pancreas. *c''*. Short arteries of the stomach. *c'''*. Left gastro-epiploic artery. 2. Cut trunk of anterior mesenteric artery. 3. Left renal artery. 4. Left spermatic artery divided. 5. Posterior mesenteric artery. *d d*. Middle hæmorrhoidal artery. *d' d' d'*. Its vascular arches. *d''*. Posterior hæmorrhoidal artery. 6 6. Lumbar arteries. *e e*. Their spinal branches.

nose with asternal and anterior abdominal branches of internal horacic; while the last four traverse the abdominal muscles, and nnosculate with the posterior abdominal and circumflex ilii, upplying the pleura, ribs, intercostal and thoracic muscles. The *lorso-spinal* branch is distributed to the dorsal muscles and nteguments, supplying the cord and its coverings through the ntervertebral foramina.

The Lumbar arteries (Pl. XXII. fig. 2, *b*, *b*, *c*, *c*), five or ix pair, originate like the intercostals, dividing in the inter-ransverse spaces into *superior* or *lumbo-spinal*—the larger—vhich are distributed to the muscles and integument of the oins, furnishing spinal branches to the cord and its membranes; nd *inferior*, which pass to the psoæ, transversalis abdominis, nd internal oblique, and there anastomose with the circumflex lii. The last lumbar may arise from the internal iliac.

Phrenic or Diaphragmatic (Pl. XXII. fig. 1, *e*), two or hree small vessels which arise at the hiatus aorticus; one goes o the left, the other to the right diaphragmatic crus, terminating n the cordiform tendon. The right gives twigs to the pleura and right lung.

Middle sacral, inconstant and variable in size, arises between he internal iliacs, and is chiefly distributed to the sacral perios-teum.

The *thoracic visceral* branches of the posterior aorta are bron-hial, œsophageal, tracheal, mediastinal, and pleura-pulmonic.

The Bronchial arteries (Pl. XXII. fig. 1, *b*) spring from the urved portion of the trunk, pass between it and œsophagus to he bifurcation of the trachea, dividing into right and left, which nter the lungs with the bronchii, ramifying in an aborescent nanner, and sometimes terminating in the pulmonary arterial apillaries.

The Œsophageal (Pl. XXII. fig. 1, *c*) arises just behind the ronchial, and proceeds backwards to the posterior mediastinum; eaching the œsophagus, it divides into two. The large superior s distributed to the upper, the inferior to the under surface,

anastomosing with the gastric, and supplying the posteri
mediastinum.

The *abdominal visceral* branches of the posterior aorta a
cœliac axis, anterior mesenteric, renal, spermatic, and posteri
mesenteric.

The Cœliac axis (Pl. XXII. fig. 1) is a short trunk aris
from the lower surface of the aorta as it enters the abdome
After coursing an inch it divides into gastric, hepatic, an
splenic.

The Gastric (Pl. XXII. fig. 2, *a*, *a'*, *a''*, *a'''*), the central an
smallest division, passes the cardiac orifice of the stomach, an
divides into *right* or *anterior*, *left* or *posterior*, and *pleural*: th
latter rises into the thorax, bifurcates and anastomoses with eithe
œsophageal and pleura pulmonalis artery of the thoracic. Th
right gastric passes to the œsophagus over the lesser curvature o
the stomach, and is distributed to the anterior aspect of the greate
cul-de-sac; the *left gastric* runs to the posterior aspect, and ter
minates in the right cul-de-sac; both are tortuous, and anasto
mose with the splenic under the serous coat.

Splenic (Pl. XXII. fig. 2, *c c*, *c'*, *c''*, *c'''*), the largest cœlia
division, passes to the left over the fundus of the stomach, enter
the hilum of the spleen enveloped in gastro-splenic omentum
and at the splenic apex becomes the *left gastro-epiploic*, whic
reaches along the greater curvature as far as the lesser cul-de-sac
finally anastomosing with the right gastro-epiploic branch of th
hepatic; it supplies omentum pancreas, spleen, and stomach.

The Hepatic (Pl. XXII. fig. 2, *b b*, *b'*, *b''*, *b'''*) passes to the right
drilling the pancreas, crosses obliquely under the posterior ven
cava, enters the transverse fissure of the liver, dividing into righ
and left, which are distributed to the viscus with the vena
portæ; it gives off *pancreatic* twigs to the pancreas and the
pyloric, which passes over the duodenum to the pyloric an
lesser curvature, anastomosing with the left gastric, and termi
nates as the *right gastro-epiploic* and *duodenal*. The former
crosses the duodenum, gains the greater curvature of the stomach

PLATE XXIII.

CIRCULATORY ORGANS—ARTERIES.

Fig. 1. Mesentery spread out along with the Arteries to the Small Intestine.

1. Trunk of anterior mesenteric artery cut through. *a a.* Arteries to the small intestine. *a' a'.* Their vascular arches.

Fig. 2.—Branches of Posterior End of Aorta.

(The Pelvis is opened from the Left Side.)

1. Spermatic cord divided. 2. Septum scroti. 3. Penis. 4. Urinary bladder. 5. Left seminal vesicle. 6. Posterior end of rectum. *A.* Posterior end of abdominal aorta. *a.* Right internal spermatic artery. *b.* Right iliac artery. *b'.* Circumflex iliac artery. *b''.* Branches to internal iliac glands. *b'''.* Branches to external iliac glands. *b''''.* External spermatic artery. *c.* Epigastric artery. *c'.* Posterior epigastric artery. *c''.* External pudic artery. *B B.* The two hypogastric arteries. *d.* Left ilio-lumbar artery. *e.* Left internal pudic artery. *e'.* Umbilical artery. *e''.* Internal hæmorrhoidal artery. *f.* Left lateral sacral artery. *g.* Right anterior gluteal artery. *h.* Right posterior gluteal artery. *i.* Right inferior gluteal artery. *k.* Right obturator artery.

d inosculates with the left gastro-epiploic ; the latter proceeds ng the curvature of the duodenum, and anastomoses with the terior mesenteric, supplying the mesentery.

The Anterior, or Greater mesenteric (Pl. XXII. fig. 2, 2 ; l. XXIII. fig. 1, 1, *a a*, *a' a'*), arises an inch behind the eliac axis, and splits into left, right, and anterior divisions. he *left* consists of a score of branchlets, which pass to the esentery, inosculating over the lesser curvature of small in- stines. The *anterior* branch anastomoses with the duodenal the hepatic. The *right* arises singly, but divides into ilio- cal superior, and inferior cæcal, and right or direct colic. he *ilio-cæcal* passes along the mesentery to the ileum, and osculates with the left division. The *superior* or *internal cal* goes to the upper, the *inferior* or *external cæcal* to the wer fissure of the cæcum. As it crosses the junction of the lon and cæcum, it supplies the artery of the arch which goes the colon and ileum. The *right colic* supplies the first and cond portions of the large colon, anastomosing with the retro- ade at the pelvic flexure. The *anterior* division consists of ft or retrograde colic, and a branch to the floating or single *lon*. The *retrograde* runs parallel with the right, supplying he third and fourth portions of the gut, anastomosing *ut supra*. he *artery of floating colon* anastomoses with the posterior esenteric.

Renal or Emulgent arteries (Pl. XXII. fig. 2, 3), right and ft, leave the aorta at right angles. The former comes off farther ack than the latter, whose origin almost corresponds with the nterior mesenteric ; the right, having to cross the vena cava, is e longer. They pass straight to the hilum of the kidneys. eaching the cortical substances, they form an intricate capil- ry net-work, and constitute the Malphigian tufts, surrounded y the origins of the uriniferous tubes. The anterior branch pplies the supra-renal capsules (*vide* Kidney).

The Spermatic arteries (Pl. XXII. fig. 2, 4), right and left, come, in the female, the utero-ovarian. In general they spring

from the under surface of the posterior aorta, just behind t renals; the right may come from the posterior mesenteric, both arise in common. The spermatic, their diameter considere are the *longest arteries in the body*, giving off no lateral branch but pursue a diverging, tortuous course through the abdomin ring, and become a constituent of the spermatic cord lying a terior to the vas deferens, and are finally distributed to the tuni vascula of the testicle. The UTERO-OVARIAN pass to the bro ligament of the uterus, dividing into *ovarian* and *uterine*. Th former is tortuous, supplying the ovaries; the latter passes the cornua of uterus, anastomosing with the uterine artery.

POSTERIOR MESENTERIC (Pl. XX. fig. 2, 5), longer but le capacious than the anterior, comes off near the spermatic, an divides into five or six branches, two or three of which supp the colon and mesocolon, anastomosing with the anterior mese teric. The posterior twigs reach the rectum, cling to the ant and, along with the external pudic and artery of the bulb, co stitute the hemorrhoidal. After giving off the last lumbar, th aorta divides into external and internal iliacs.

The INTERNAL ILIAC (Pl. XXIII. fig. 2, *b*), continuations the abdominal aorta, are short trunks diverging outwards an backwards from the last lumbar vertebra, and terminating ne the sacra iliac articulation, in the obturator, gluteal, and late sacral. At its external inferior origin arises the *artery of th bulb*, which passes between the parent trunk and external ili vein, to gain the superior border—the pyriformis muscle, it the pierces the sacro-sciatic ligament, clings to and rounds th ischiatic arch, and terminates in the bulb of the penis. Th internal iliac gives off the umbilical, vesico-prostatic, and intr pelvic muscular vessels, as well as branches to Cowper's gland perineum, triangularis penis, and anus. In the female it su plies the vaginal bulb and membrane. The UMBILICAL ARTER large in the fœtus, is a mere fibrus cord in the adult, constitu ing the round ligament of the bladder. The VESICO PROSTAT arises by a common or separate branch, and supplies the bladde

esiculæ seminalis, vas deferens, and prostatic gland. In the male it becomes the *vaginal*, and passes to the uterus, anastomosing with the utero-ovarian. The largest terminals of the ternal iliac are the OBTURATOR (Pl. XXIII. fig. 2, *k*), which asses backwards to its satellite vein and crural nerve between ne peritoneum and ileum, along the lower border of the pyriformis, between the obturator internus and ligament, leaving the elvis through the obturator foramen, rounds the ischial ramus, nd there splits into ischiatic pudic and internal pudic. Near s origin, the obturator gives off the iliaco-femoral, or *arteria nominata*, which proceeds outwards across the iliacus and soas, and terminates in the rectus femoris, vasti, and tensor aginæ. The ISCHIATIC, which passes behind the hip joint, and upplies the triceps abductor, anastomosing with the popliteal nd arteria profunda. The PUDIC (Pl. XXIII. fig. 2, *c''*, *e*), hich clings to the ramus of the ischium, and terminates in the iceps, and the *internal pudic*, which rounds the ischial arch, nd at the root of the penis divides into two branches—one for ne crus, the other for the dorsum. The latter supplies the corus cavernosum, and anastomosing with the external pudic from ne profunda. The middle terminal of internal iliac is the large LUTEAL (Pl. XXIII. fig. 2, *g*, *h*, *i*) artery, which leaves the pelvis rough the sacro-sciatic ligament along with the sciatic nerve, nd is distributed to the gluteal muscles, anastomosing with the moral. The last terminal of internal iliac is the LATERAL ACRAL artery (Pl. XXIII. fig. 2, *f*), which passes along the side f sacrum, sends twigs to the cord, and gives off five or six and its overings. The large PERINEAL artery, arising near its posterior ivision, is sometimes considered the continuation of the vessel. supplies the gluteal muscles, anus, and perineum. The terminals of the lateral sacral are the *lateral* and *inferior coccygeal*, ng and slender arteries, which go to the lateral and inferior pects of the tail, supplying the vertebral muscles and skin. he inferior coccygeal passes to the anus.

The EXTERNAL ILIACS are the anterior bifurcations of the abdo-

minal aorta, arising below the last lumbar vertebra. They cur
obliquely outwards, over the true pelvic brim, and adown t
psoas parvus, covered only by peritoneum. Midway betwe
the symphysis pubis and anterior iliac spine, they become t
femorals. They give off the circumflex ilii artery of the co
and profundi femoris. The *circumflex ilii* springs from t
outer side, crosses the psoas magnus and iliacus to the anteri
iliac spine, where it divides into two branches—the anteri
which ramifies in the transversalis and internal oblique, anast
mosing with the abdominal branches of the intercostal a
lumbar arteries; and posterior, which crosses the abdomen ju
below the external iliac spine, between the iliacus and internal o
lique, loosing itself in the tensor vaginæ and muscles of the thig

The artery of the cord, the uterine in the female, is small a
inconstant, usually arising from the external iliac, but som
times from the abdominal aorta or circumflex, courses to, tern
nating in the spermatic cord. The *uterine* is larger, and is d
tributed to the body and cornua of uterus, anastomosing wi
the utero-ovarian and vaginal.

The Arteria profunda femoris (Pl. XXIV. fig. 3, *a*, *a*, *a*) aris
at the origin of the femoral. Some regard it as a bifurcatio
of the iliac. It passes directly backwards between the iliac
and pectineus, and the pectineus and obturator externus, gai
the border of the abductor brevis and longus, winds round t
neck of the femur, supplying the hip joint and adjacent musc
and is lost in the biceps rotator tibialis and triceps abduct
femoris, anastomosing with branches of the ischiatic and
turator. The profunda gives off the epigastric, subcutaneo
abdominal, and external pudic or mammary.

The *epigastric*, or *posterior abdominal* (Pl. XXIII. fig. 2, *c*,
arises just before it dips into the thigh. It proceeds dow
wards, between the peritoneum and tendon of the transversa
through the inguinal canal, and is distributed on the inter
aspect of the rectum, vastus internus, and cremaster, anastom
ing with the circumflex.

The *subcutaneous abdominal* passes forward through the guinal canal over the abdominal fascia, reaching the anterior tremity of the suspensory ligament of the sheath, where it rminates by numerous subcutaneous twigs, supplying the eath, superficial inguinal ganglia, scrotum, and corresponding ructure in the female, one twig circling round the umbilicus to osculate with its fellow from the opposite side.

The *external pudic* descends to the dorsum penis through the guinal canal, where it divides into anterior and posterior. he anterior is long and flexuous, so as to allow retraction of the nis. It runs along the dorsum penis to its anterior extremity, rminating in the erectile tissue. The posterior also passes to e dorsum penis, and anastomoses with the internal pudic, pplying the scrotum and tunica vaginalis. In the female, the *ammary* replaces the external pudic; it is much larger, and mifies in the substance of the mamma. As it dips between the ighs it passes a twig to the inferior commissure of the vulva.

The Femoral artery (Pl. XXIV. fig. 2) is the continuation of the xternal iliac. After giving off the profunda, it occupies a triangu- r space between the iliacus pectineus and adductor brevis, over- pped by the sartorius and gracilis, and related to the crural erve and satellite vein along the entire length of pectineus and astus internus. Leaving the posterior border of the sartorius, enters a ring formed by the adductor longus, magnus, and moral bone, and passing between the bifid origin of the gas- ocnemius externus, terminates in the popliteal. It sup- lies *seriatim* the inguinal, muscular, articular, and saphenic ranches. The *inguinal* comes off at the groin, under the in- inal glands, crosses the sartorius, supplies the iliacus, psoas agnus, vastus internus, and rectus femoris. The *muscu- r* supply adjacent muscles. The *anastomatic* or *articular* escends to the vastus internus, passing between it and the lductor. It supplies them, as well as the stifle joint, anas- mosing with the popliteal. The small *saphenic* passes back- ards, between the adductor magnus and longus, terminating

in the recurrent and a twig, which inosculates with the profund tibial, and femoro-popliteal.

The Popliteal artery (Pl. XXIV. fig. 4), continuation the femoral. Arising between the heads of the gastrocnemi externus, it passes under the popliteal muscle, and, at t upper third of tibia, bifurcates into anterior and posterior tibia Its branches are femoro-popliteal, articular and muscular.

The *femoro-popliteal* springs from its posterior aspect, a passes under the tendon of adductor magnus, between t biceps rotator and adductor longus, supplying them, and, leavi the subcutaneous or posterior aspect of the haunch, it term nates in ascending and descending branches, which inosculat with profunda, ischiatic, and posterior tibial, supplying the ski on the back of haunch. The *articular* branches supply the stif joint; the *muscular* go to the gastrocnemii. One slender twi descends in front of fibula, along with the popliteal nerv and forms a terminal anastomoses with recurrent tibial o gastrocnemius externus tendon.

The Posterior tibial (Pl. XXIV. fig. 4. 2, 2) lies beneath t popliteus, flexor pedis, and accessorius, behind the tendon of t latter. It is directly covered by fascia. It travels down t side of the leg to the crest of the os calcis, where it terminat in the tarsal arch, whence spring two *recurrent* branches, whi inosculate with the popliteal and saphenal, and two *descendi* branches, which supply the hock joint, and near the fetlo inosculate with the metatarsal nutrient. Tibial and muscul branches are also supplied.

From the convex arch formed at the hock by the union the posterior and anterior tibial, two unimportant and two de branches arise; the latter are the *internal* and *external inte osseous plantar* arteries. Each clings to its relative side of t inner metatarsal bone, the external providing the nutrient met tarsal; both inosculate at the fetlock with the metatarsal.

The Anterior or Internal tibial (Pl. XXIV. fig. 4. 3, 3), t largest terminal of the popliteal, winds forwards between t

bia and fibula to the fore part of the thigh, gaining it midway between the stifle and hock. It lies between the outer border of the metatarsal flexor tendon and tibia. At the hock it again passes outwards, and becomes metatarsal at the proximal end of the metatarsus. It gives off *twigs to the stifle* and adjacent muscles, which anastomose with the popliteal, and the *peroneal*, near the origin of the tibial, which supplies and runs under the peroneus, finally giving *branchlets to the hock* joint, below which it divides into *metatarsal* and *metatarsal perforans*.

The Perforans or Collateral metatarsal passes through a groove between the cuboid and cuneiforme magnum down the dorsum of the leg to the arterial arch, on the fetlock, formed by the deep branch of the posterior tibial and metatarsal.

The large Metatarsal originates at the anterior distal aspect of the hock, on the upper external aspect of the large metatarsal bone; coursing in the groove between it and the external metatarsal, it again insinuates itself between them, gains the back of the large bone between the bifurcation of the suspensory ligament, and finally anastomoses with the perforans and deep interosseus branch of the posterior tibial—the *three* forming the *sesamoideal arch*, whence spring the *right* and *left plantars*, which gain the outer aspect of the fetlock, after passing over the corresponding surface of the sesamoid bones, supplying the surrounding parts.

The Anterior aorta (Pl. XX. fig. 4, *a*) is about one inch in length, and passes obliquely upwards and forwards between the layers of the anterior mediastinum, over the right auricle, under the trachea, and to the left of the anterior vena cava, furnishing twigs to the pericardium, mediastinum, and trachea; between the second and third dorsal vertebra, it divides into right and left arteria innominata or brachial arteries.

The Arteria innominata (Pl. XX. fig. 3, *i*) separate at an acute angle, the left being uppermost, and pursue a diverging course towards the anterior aperture of the thorax, whence they are continued as the *axillary*, the right giving off the common

carotid. Both pass forward between the layers of the anteri mediastinum, the right below, the left to the side of the trache and almost under the œsophagus.

The Left arteria innominata, within the thorax, gives o the dorsal, posterior cervical, and vertebral from its upper, an the internal thoracic from its lower aspect.

The *dorsal* (Pl. XX. fig. 3, *l*) runs to the outer side of th trachea, œsophagus, thoracic canal, sympathetic and longus coll muscle, under the mediastinum through the second intercosta space, reaching the withers. It supplies the muscles of tha region. The anterior branch goes to the splenius and complexu major, anastomosing with the terminal twigs of the cervical Within the thorax, the dorsal gives off a few twigs to th mediastinum, and a large branch which furnishes from th second to the fifth anterior intercostal arteries.

The *posterior cervical* artery (Pl. XX. fig. 3, *m*) arises anterio to the dorsal, sometimes along with it, having the same rela tions until it passes through the first intercostal space. It now runs upwards along the ligamentum nuchæ, covered by th complexus major, as far as the vertebra dentata, distributing branches to the muscles of the neck, and anastomosing with th dorsal and vertebral. Within the thorax, it gives off the firs intercostal artery, and a twig to the mediastinum.

The *vertebral* (Pl. XX. fig. 3, *n*) arises opposite the first rib gains the outer side of the trachea and œsophagus, leaving th thorax, passing under the transverse process of the seventh through the foramina in the transverse processes of the sixth to the second cervical vertebra, covered by the transversalis colli. On reaching the atlas it anastomoses with the retrograde branch of the ramus anastomoticus, which comes through the posterior foramen on the wing of the atlas. Here it is covered by the obliquus capitis inferioris. It supplies branches to the muscles of the neck, also to spinal cord and its membranes.

The *internal thoracic*, pectoral, or mammary, originates at the first rib, opposite the vertebral. It descends perpendicularly to

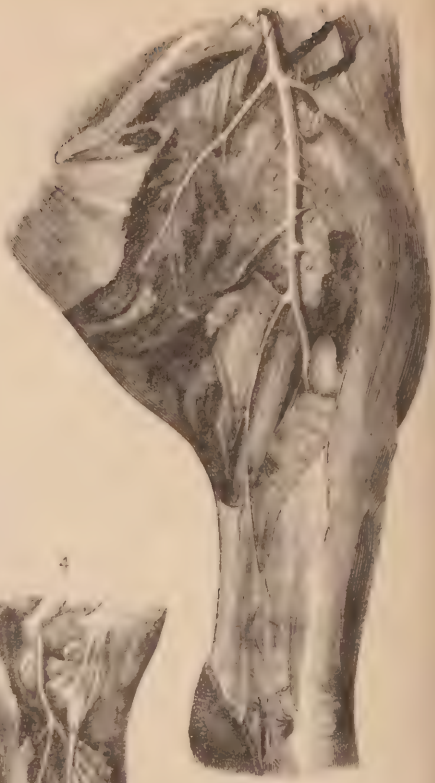

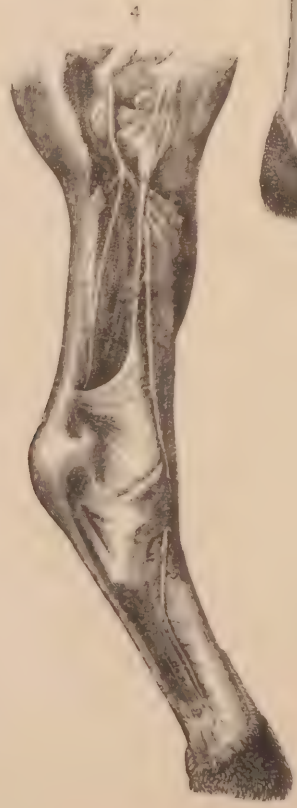

PLATE XXIV.

CIRCULATORY ORGANS—ARTERIES.

Fig. 1.—Arterial Branches exposed on the inner side of the left Fore-leg.

1. Axillary artery. *a*. Anterior scapular artery. *b*. Middle scapular artery. *b′*. Posterior scapular artery. *b″*. External scapular artery. *b‴*. Internal scapular artery. *b⁗*. Subscapular artery. 2. Brachial artery. *c*. Circumflex artery. *d*. Arteria profunda. *e*. Ulnar artery. *e′*. Nutritious artery of humerus. *e″*. Branches to the glands. *e‴ e‴*. Posterior subcutaneous artery. 3. Anterior radial artery. 4. Posterior radial artery. *f*. Interosseous artery. *f′*. Artery to the posterior carpal anastomosis. *g*. Muscular branches. 5. External volar artery. 6. Deep volar artery. 7. Internal volar artery.

Fig. 2.—Arterial Branches exposed on the inner side of the lower part of left Fore-leg.

5. External volar artery. 6. Deep volar artery. 7. Internal volar artery. 8. Internal digital artery. 9. External digital artery. *h*. Anterior pastern artery. *i*. Posterior pastern artery. *k*. Artery of the frog. *l*. Anterior coronet artery. *m*. Posterior coronet artery. *n*. Anterior coffin artery. *o*. Posterior coffin artery.

Fig. 3.—Arteries exposed on the inner side of the left Hind-leg.

1. Main trunk of femoral artery. *a a a*. Deep femoral artery. *b*. Anterior femoral artery. *c*. Internal subcutaneous artery. *d d d d*. Muscular branches. *e*. Nutritious artery of femur. *f*. Inferior femoral artery. *f′*. Its ascending branch. *f″*. Its descending branch. *g*. Internal malleolar artery. *h*. Recurrent tibial artery. *i*. Posterior plantar artery.

Fig. 4.—Arteries of lower part of left Hind-leg exposed on the outer side.

1. Popliteal artery. 2 2. Posterior tibial artery. 3 3. Anterior tibial artery. *a*. Peroneal artery. *b*. Muscular branches. 4. Deep plantar artery. 5. External plantar artery.

ne second bone of the sternum, passing over the sternal cartilage to the ensiform, where it splits into anterior abdominal, nd asternal, giving supply branches to the pericardium, mediasnum, and intercostals, which are distributed to the pectoral nuscles, anastomosing with the external thoracic and seven first ntercostals. In the young it supplies the thymus gland. The *nterior abdominal* leaves the thorax at the ensiform cartilage, enetrates the rectus abdominis, and anastomoses with the posrior abdominal. The *asternal* creeps along the inner border of ne cartilage of the seventh, then round those of the false ribs, rossing the digitations of the transversalis abdominis, terminatng in the thirteenth intercostal space by anostomising with the ntercostal artery. It supplies the diaphragm, transversalis, and ectus abdominis.

As the innominata leaves the thorax, it gives off the *anterior r inferior cervical* (Pl. XX. fig. 3, *o*), which passes between the ulf of the jugular and pectoralis parvus, and divides into scending and descending. The former runs between the levator umeri and subscapulo-hyoideus, supplying the axillary glands nd adjacent muscles. The latter lies between the pectoralis nticus and levator humeri, terminating in the pectoral muscles.

The *innominata* passes from the thorax, between the first ribs, nd becomes the *axillary*, which winds round the first rib just elow its middle, passing between the scapula and trunk to the nner head of the humerus, where it ends as the *humeral*.

The Axillary (Pl. XXIV. fig. 1, 1, &c.) gives off the *external horacic*, or *mammary*, which arises close to the inferior cervical, turns round the anterior border of the first rib, along he interior aspect of the pectoralis magnus and parvus, its terminal branch accompanying the spur vein to the panniculus; he *anterior scapular* (Pl. XXIV. fig. 1, *a*), which arises from the xillary in front of the tendon of subscapularis, passing between t and the antea-spinatus, and is accompanied by a vein and nerve o the dorsum scapulæ, supplying the shoulder joint, pectoralis parvus, scapular muscles, and flexor brachii tendon; and the *sub* or

posterior scapular (Pl. XXIV. fig. 1, *b'*), which arises at right angles from the axillary, just before it becomes humeral, near the interstice, separating the subscapularis and teres internus muscles. It passes up to the inner side of the caput magnum, and terminates at the dorsal angle of the scapula, supplying a branch to latisimus dorsi, scapular, and lateral thoracic muscles, as the *nutrient scapular* and *scapulo-humeral* or *posterior circumflex* which passes behind the shoulder joint, under the caput magnum and postea-spinatus, terminating in the muscles of the shoulder joint.

The Humeral or Brachial (Pl. XXIV. fig. 1, 2), the continuation of the axillary, descends along the inner side of the arm, crossing the humerus obliquely. It divides into ulnar, spiral or anterior radial, and posterior radial, accompanied by the spiral radial and ulnar nerves, and two humeral veins. Its principal branches are the anterior circumflex and deep humeral. The *prehumeral* or *anterior circumflex* (Pl. XXIV. fig. 1, *e*) passes between the two heads of the coraco-humeralis, reaches the front of the humerus, and terminates in the levator humeri, giving twigs to flexor brachii, coraco-humeralis, and shoulder joint, and anastomising with the posterior circumflex.

The Arteria humeralis profunda (Pl. XXIV. fig. 1, *d*) arises near the conjoined tendon of latisimus and teres internus, is distributed to the caput magnum, medium, elbow joint, anconeus, humeralis obliquus, and extensor metacarpi magnus, anastomosing with the posterior radial. Muscular branches pass to the flexor brachii, and it also gives off the *nutrient* artery to humerus. The smallest terminal artery is the Cubital or Ulnar, which passes beneath the scapulo-ulnaris to the distal end of the middle head of the triceps extensor, adown the arm between the external and middle flexors of the metacarpus, and inosculates at the knee with the posterior radial. It gives off branches to the caput medium, scapulo ulnaris, pectoralis transversus, brachial fascia, the flexors of the leg, one nutrient artery to the humerus, and twigs to the elbow joint.

The Spiral or Anterior radial (Pl. XXIV. fig. 1. 3) leaves the posterior at an acute angle, just above the condyle of the humerus. It descends over the anterior surface of the elbow, insinuates itself beneath the caput muscles and origin of extensor metacarpi magnus, where it meets the radial nerve. They travel together in front of the radius, and approach the knee below the extensor pectis. It divides into numerous branches, which are distributed to the capsular ligament of the knee, elbow joint, and extensors, anastomosing with the posterior radial.

The Posterior radial (Pl. XXIV. fig. 1, 4) is the continuation of the humeral. It passes down the inner side of the arm, along with a vein and nerve, inclining backwards beneath the flexor metacarpi internus, dividing at the distal end of the radius into large and small metacarpal. It *can be felt just below the insertion of flexor brachii.* It supplies twigs to the elbow joint, which anastomose with those of the ulnar, and gives muscular branches to the posterior surface of arm. The *interosseous* artery of the fore-arm comes off near the radio-ulnar arch, through which it passes outwards, crossing the posterior surface of the radius below the perforans. It then descends in the radio-ulnar groove, covered by the extensor suffraginis, and inosculates with the anterior radial, forming a plexus above the knee, yielding branches to the elbow joint, flexor muscles, also the *nutrient radial*, and the *recurrent radial*, which passes to inosculate with the ulnar.

The Small metacarpal artery is given off at an acute angle. It passes along the inner back of the knee, external to the posterior annular ligament, which separates it from the large one about the head of the metacarpus. It crosses from the inner to the outer side at the back of the leg, inosculating with a descending branch of the ulnar, forming the *subcarpal arch*, whence originate two anterior and two posterior interossei. The *anterior* ones round the head of the smaller splints, passing along the grooves between the large and small splints, and anas-

tomose with the spiral above, and the large metacarpal below. The *posterior interossei* descend on either side of the suspensory ligament, inosculating near the distal end of the small splint with branches from the large metatarsal.

The LARGE METACARPAL is the continuation of the posterior radial. It runs beneath the posterior annular ligament in company with the tendo perforatus, afterwards descending to the inner side of the flexor tendons, along with the internal metacarpal nerve and vein above the fetlock. It passes between the tendons and suspensory ligament, forming the *external* and *internal plantars*. At its bifurcations it constitutes the TRANSVERSE ARCH, from which *three recurrent* branches spring. These mount up between the bifurcations of the suspensory one on the *inner*, another on the *outer lateral* aspect, anastomosing with the small metacarpal and ulnar. The third supplies the *nutrient* artery. From the arch likewise arise the *external* and *internal*, and *lateral transverse*, which encircle the fetlock joint. The metacarpal gives off numerous branchlets to the tendons and ligaments, finally anastomosing with the spiral.

The terminal divisions of the metacarpal are the EXTERNAL and INTERNAL PLANTARS (Pl. XXIV. figs. 1 and 2, and description), or digital arteries, which are alike in fore and hind. These separate at an acute angle below the bifurcation of the suspensory ligament in front of the flexor tendons, passing over the fetlock joint to the right and left of the outer side of the sesamoid bones, accompanied by satellite veins and nerves. The artery is central, and the nerve posterior. They run down the lateral sides of the os suffraginis and os coronæ, and pass behind the lateral cartilage to the fatty frog, through which they descend to the superior border of the alæ of os pedis, thence along the plantar groove in the tendinous surface of the bone, terminating at the plantar foramina on either side of the insertion of the flexor pedis perforans. They supply numerous branches to the flexors and extensors, fetlock pad and joint, and give off the following five branches:—

The *perpendicular artery*, which arises at right angles below the middle of the os suffraginis, descends on its sides, inclining forwards, and terminates above the coronary ligament by anastomosing with its fellow, their union forming the SUPERFICIAL CORONARY ARCH, whence spring about 20 branchlets, which descend to the coronary ligament.

The *transverse artery*, detached with the preceding, passes down and between the front of the bone and extensor tendon, and anastomoses with its fellow, forming a second arch—the SUPERIOR CORONARY CIRCLE—from which spring several branches to the neighbouring parts, some passing on to the superior coronary arch.

The *artery of the frog* arises behind the pastern joint at the superior part of the lateral cartilage, entering the fatty frog. It divides into anterior and posterior, supplying the lateral cartilage.

The *lateral laminal*, given off at the posterior aspect of the ala of coffin bone, passes through the notch between the rostral and basilar processes, and along the preplantar groove in the wall of the hoof, accompanied by a nerve, at the anterior extremity of which it terminates by several branches, which enter the pedal bone, and anastomose with the circulus arteriosus. At its origin, a *retrograde branch* passes to the bulb of the frog. After passing through the plantar groove, it gives off a *second retrograde*, which supplies the external part of the lateral cartilage, one twig inosculating with the circumflex artery. It supplies numerous ascending and descending branches, which ramify in the sensible laminæ, anastomosing with those of the coronary arch and circumflex artery.

The *terminal branch* of the digital is the *plantar proper*, which passes through the foramen on the tendinous surface of the pedis, enters the bone within, which it inosculates with its fellow, forming the *circulus arteriosus*, or PLANTAR CIRCLE, from which spring ascending and descending branches. The former are the *anterior laminal*, which leave the bone through numerous

apertures on its wall, and ramify among the sensible laminæ. The latter are the *inferior communicating* arteries, which average 14. They travel through the osseous foramina just above the edge of the os pedis, and unite to form the *circumflex artery*, which runs round the toe, giving off *ascending branches* to the sensible laminæ, and 14 descending ones—the *solar arteries*—which supply the sensible sole, uniting posteriorly to constitute the *inferior circumflex*.

The RIGHT ARTERIA INNOMINATA, having supplied branches corresponding to the left, viz., dorsal, superior cervical, vertebral, internal thoracic, inferior cervical, external thoracic, and axillary, becomes the COMMON CAROTID or CEPHALIC (Pl. XX. fig. 4, *b*), which is detached at an acute angle, and directed forwards under the trachea and above the anterior vena cava. On reaching the anterior opening of the thorax, it bifurcates, forming the RIGHT and LEFT CAROTIDS, which pass up the side of the neck, diverging as they ascend, at first below, afterwards on the side of the trachea, to which they are attached by areolar tissue. At the middle of the neck, they reach the posterior tracheal aspect, and are continued to the upper part of the larynx, where they divide into EXTERNAL and INTERNAL CAROTIDS and *ramus anastomoticus*. Throughout their course, they are accompanied by the par vagum, recurrent, and cervical portion of sympathetic nerves—all in the same sheath, the par vagum being external. The arteries are covered at the lower part of the neck by the scalenus and levator humeri; in the middle, by subscapulo-hyoideus; and by the rectus capitis anticus major superiorly. The carotid and jugular are usually separated by slips of the subscapulo-hyoideus, but at the entrance to the thorax they contact the artery, lying superiorly. The carotids give off several small branches to the muscles of the neck, twigs to the trachea and œsophagus, and, near their termination, the thyro-laryngeal and thyroid accessory. The *thyroid accessory* enters the inferior part of the thyroid gland, to which it is distributed. The *thyro-laryngeal* arises just above

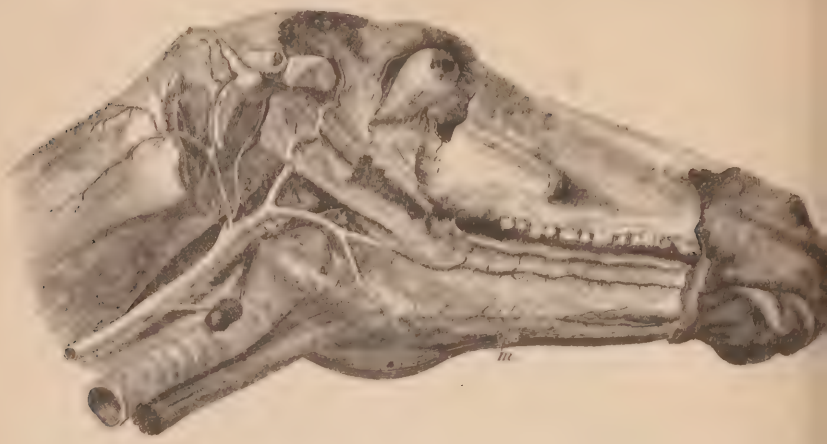

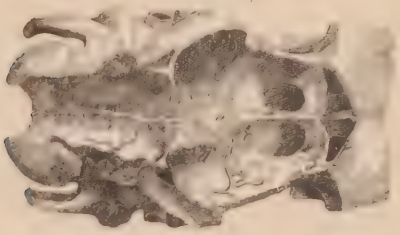

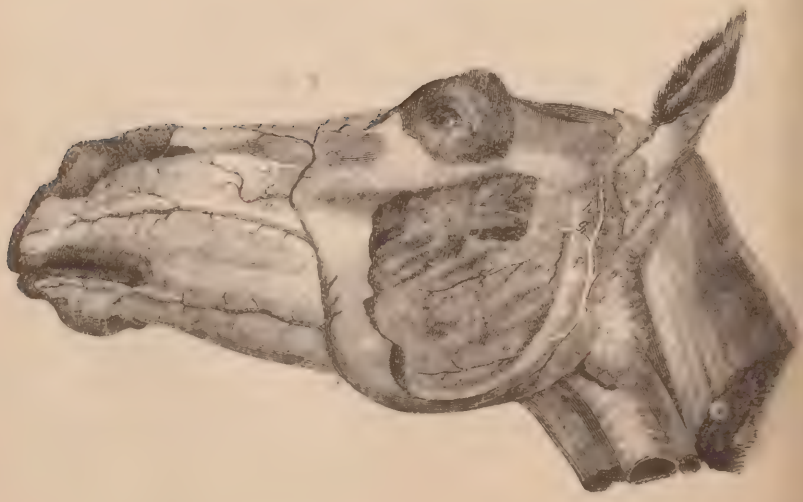

PLATE XXI.

CIRCULATORY ORGANS—ARTERIES.

Fig. 1.—The Three Divisions of the Carotid, and their Branches exposed on the Right Side of the Head.

(The Right Ramus of the Lower Jaw is removed.)

1. Occipital artery. *a.* Superior sub-maxillary artery. *b.* Inferior meningeal artery. *c.* Superior meningeal artery. *c' c'.* Muscular branches. *d.* Posterior branch. *e.* Anterior branch. 2. Internal carotid artery. 3. External carotid artery. *f.* Middle sub-maxillary artery. *g.* Superior laryngeal artery. *A.* External maxillary artery. *h.* Superior pharyngeal artery. *i i.* Lingual artery. *k.* Inferior sub-maxillary artery. *l l.* Sublingual artery. *m.* Branch to tracheal glands. *B.* Internal maxillary artery. *n.* Middle meningeal artery. *o o.* Anterior temporal arteries. *p.* Ophthalmic artery. *q.* Buccinator artery. *r.* Inferior palpebral artery. *s.* Anterior alveolar artery. *t.* Posterior nasal artery. *u.* Palatine artery. *v.* Artery to the velum palati.

Fig. 2.—Cavity of Skull laid open with the Basilar and Internal Carotid Arteries.

a. Anterior branch of right internal carotid. *a'.* Anterior branch of left internal carotid. *b.* Posterior branch of right internal carotid. *b'.* Posterior branch of left internal carotid. *c.* Place of junction of the two anterior branches. *d d.* Points of junction of the two posterior branches with the two branches of the basilar artery. *e.* Basilar artery.

Fig. 3.—External and Internal Maxillary Arteries, with their Branches on the Face.

Branches of Internal Maxillary Artery.

a. Masseteric artery. *a'.* Posterior branch of masseteric artery. *b.* Superior parotid artery. *c.* Posterior auricular artery. *d.* Anterior auricular artery. *e.* Inferior auricular artery. *f.* Temporal artery. *f'.* Transverse facial artery. *g'.* Anterior branch of masseteric artery. *g''.* Middle branch of masseteric artery. *h.* Posterior temporal artery.

Branches of External Maxillary Artery.

i i. Facial artery. *k k.* Coronary artery of lower lip. *l l.* Coronary artery of upper lip. *m.* Lateral nasal artery. *n.* Dorsal nasal artery. Angular artery.

the accessory opposite the upper tracheal ring, winds round the trachea, and divides into terminal branches to the thyroid body, pharynx, and larynx.

The *ramus anastomoticus* or Occipital (Pl. XXI. fig. 1, 1) comes off at the angle formed by the external and internal carotids. At first it accompanies the internal, then crosses it, and reaches the under surface of the wing of atlas at the back of the guttural pouch. It now penetrates the submaxillary gland and anterior straight muscles of the head, passes between the rectus anticus minor and inferior border of atlas, through the external anterior foramen of atlas, and at its upper surface divides into the *cerebro-spinal* and *musculo-occipital*. It is crossed by the par vagum and spinal accessory nerves and the cervical portion of sympathetic chain, and accompanied by divisions of the inferior branch of the first spinal nerves. In its course it communicates with the submaxillary, terminating in the prevertebral, mastoid, and retrograde.

The Prevertebral comes off as it crosses the internal carotid, and divides into muscular and meningeal, the *muscular* going to the anterior straight muscles of the head and occipito-atloidean articulation. The *meningeal* are small *superior* and *inferior* branches, which are distributed to dura mater through the foramen lacerum basis cranii, and condyloid foramen.

The Mastoid artery leaves the trunk opposite the prevertebral, is directed to the mastoid foramen of temporal bone, creeping over the styloid process of occipital, under the obliquus capitis superioris. It enters the parieto-temporal conduit, and inosculates with the meningeal branch of internal maxillary. It supplies the poll, temporal muscle, and dura mater.

The Retrograde or Recurrent, inconstant and variable, is detached at the under surface of the wing of atlas; it passes backwards through its posterior foramen under the obliquus capitis inferioris, and anastomoses with the vertebral. It supplies numerous muscular twigs, furnishing a direct communication

between the carotid and vertebral, which *par excellence* is the ramus anastomoticus.

The Musculo-occipital arises from the occipital, in the gutter which joins the anterior external and internal atloid alar foramina, covered by the obliquus capitis inferior, thence it passes transversally outwards to the posterior straight muscles and divides into *ascending* muscular and cuticular branches for the occipital region, and *descending*, which anastomose with the superior cervical.

The Cerebro spinal springs from the occipital in the alar gutter, and enters the spinal canal through the internal atloid foramen, traverses the spinal dura mater, dividing on the superior surface of the cord into an *anterior branch*, which passes forwards, anastomoses with its fellow from the opposite side forming the *basilar* trunk and *posterior*, which, after a short backward course, likewise anastomoses with its fellow from the opposite side, constituting the *middle spinal artery*.

The Internal carotid artery (Pl. XXI. fig. 1, 2; fig. 2), the second terminal of the common carotid, is directed upwards towards the base of the skull to the outer side of the anterior straight muscles, accompanied in the first part of its course by the ramus anastomoticus. The carotid being most posterior at the origin of the prevertebral and mastoid branches it is inflected forwards, crossing the anastamoticus behind the greater cornua of os hyoideus; it passes to the foramen lacerum basis cranii, at first lying in a fold of the guttural pouch along with the superior cervical ganglion and a branch of the sympathetic which enters the cranium; it is crossed by nerves leaving the foramen and going to the guttural plexus. After passing through the foramen lacerum, it enters the cranial cavity, gains the cavernous sinus, and there describes two remarkable curves—the first, with its convexity forwards, occupies the carotid fossa on the surface of the body of the splenoid: the second has its convexity backwards, which is joined by the *posterior communicating* from the basilar. The carotids are here

nited by the *transverse anterior communicating*, after which ach passes under the edge of the pituitary gland to the inner ide of the superior maxillary nerve, terminating at the optic ommissure by two branches, one forming the *posterior*, the ther bifurcating to form the *middle* and *anterior cerebrals*.

The External carotid (Pl. XXI. fig. 1, 3; fig. 2) is a con-inuation of the common carotid, being deeply buried between he guttural pouch and parotid gland. It courses forwards nd upwards, until it reaches the posterior border of the greater ornua of os hyoides, passes between it and hyoideus magnus, nd curves upwards to the neck of the condyle of lower jaw, vhere it divides into *superficial temporal* and *internal maxil-ary*. In the first part of its course it has the parotid gland, losso-pharyngeal, and superior laryngeal nerves on its outer, nd the superior belly of digastric and hypo-glossal nerve on its nner aspect. From it spring three lateral branches—submaxil-ary, maxillo-muscular, and posterior-auricular; also twigs to sub-naxillary and parotid glands, guttural pouch, and sympathetic anglia.

The Submaxillary or Glosso-facial (Pl. XXI. fig. 1, b, and ig. 3) arises just as the carotid plays between the hyoid bone nd hyoideus internus. It passes the anterior extremity of the ubmaxillary gland, runs along the upper border of digastricus nd pterygoideus internus, crosses the outside of Wharton's anal, reaches the ramus of lower jaw within the submaxillary pace, and, while subcutaneous, winds round it, reaching the ace, where it ascends in front of the external masseter muscle, nd at the maxillary spine terminates in ascending and de-cending branches; the latter pass to the nasal region, while he former supply the orbicularis palpebrarum, inosculating with he superior dental. In addition to twigs supplied to sub-naxillary glands, sympathetic and facial muscles, five branches re given off—pharyngeal, lingual, sublingual, inferior, and uperior labial or facial. The *pharyngeal*, or *ascending pharyn-eal* (Pl. XXI. fig. 1, *h*), is given off near the origin of

submaxillary, from the external carotid passing obliquel upwards between the greater cornua of os hyoides and hy pharyngeal muscle. It takes a flexous course to the pterygoi bone, and is lost in the velum palati, giving off *ascending* an *descending* branches to the walls of the pharynx. The *lingu* (Pl. XXI. fig. 1, *i i*) almost as large as the parent artery, originat near the greater cornua of the hyoid bone, passes under th hyo-glossus brevis in company with the glosso-pharyngeal nerv crosses the lesser cornua, and is thence prolonged almost to th free extremity of the tongue in a very tortuous manner. Th artery, sometimes called the *ranine*, is buried in the interstic between hyo-glossal and genio-hyo-glossal muscles, in compar with branches of lingual and hyo glossal nerves. The *sublingu* (Pl. XXI. fig. 1, *l l*) leaves the submaxillary at the anterior extr mity of submaxillary gland, passes to the external surface the mylo-hyoideus, on which it runs to the posterior extremit and along the inferior surface of the sublingual gland, supplyin it as well as the genio-hyo-glossal and genio-hyoideal muscle it is then continued to the frænum, along the under and out border of the tongue, its branches being chiefly distributed the mucuous membrane and papillæ. At the sublingual gla the *submental* arises; it follows the course of the jaw, detachi twigs to the pterygoid and mylo-hyoid muscles. *Inferior labi* or *coronary* (Pl. XXI. fig. 3, *k k*) is the first branch given off aft the submaxillary rounds the jaw, arising at the depressor la inferioris, it travels to the under lip, supplying the buccin tor, depressor labii inferioris, glandular, cellular, cuticular, a buccal mucous membrane, anastomosing with its fellow on t opposite side. *Superior labial*, *coronary*, or *facial* (Pl. XX fig. 3, *i i*), is larger than the inferior. It springs from t trunk, near the suborbital branch of superior maxillary ner passes under the dilatator naris lateralis and levator labii ferioris, and anastomosing with the palato-labial branch of t internal maxillary, supplying twigs to the nasal tissues, upp lip, and buccinator.

The second lateral branch of the carotid is the MAXILLO-MUSCULAR, which arises near the angle formed by hyoideus magnus and greater cornua of hyoid bone, passes down behind the posterior border of the jaw, covered by the parotid gland, and divides into superficial and deep branches—the latter is the *pterygoideal* artery, which passes into the pterygoid muscles, after furnishing branches to the neighbouring organs; the former is the *posterior masseter*, which winds round the posterior border of the lower jaw, appearing at the insertion of sterno-maxillaris. It now passes into the masseter, anastomosing with the subzygomatic branch of the superior temporal.

The third lateral branch of the external carotid is the POSTERIOR AURICULAR (Pl. XXI. fig. 3, *c*), sometimes considered a terminal. It springs from the posterior surface of the artery, a little behind the maxillo-muscular, ascends under the parotid, to the back of the base of the ear, where it divides into numerous ascending branches, which run up the concha between the cartilage and skin, the terminal twigs anastomosing with each other. Besides supplying the parotid and retrahentes muscles, this artery gives off a large branch, which divides into deep and superficial. The *deep* one, after giving a twig to middle ear, which enters through stylo-mastoid foramen, passes between the auditory and mastoid processes of temporal bone, dips into the adipose tissue below the ear, and supplies the deep conchial muscles. The *superficial* branch passes to the external side of the concha, gaining the anterior of the cartilage with the middle auricular nerve.

The first terminal branch of external carotid is the SUPERFICIAL TEMPORAL or TEMPORAL (Pl. XXI. fig. 3, *f*). It ascends between parotid gland, guttural pouch, and the neck of inferior maxilla, after a short course dividing anterior auricular and subzygomatic. The *anterior auricular* passes upwards to the anterior root of ear behind the temporo-maxillary articulation, and the under part of the parotid gland. After giving off twigs to the temporal muscle, and to the interior of the concha and its cuticle, it is lost in the attolentes muscles. The *sub-zygomatic*, or *temporal proper*, is

much larger than the anterior auricular. Passing under th parotid, it rounds the posterior border of the inferior maxill just below its condyle, and then terminates by two branches o nearly equal volume, the one being superior and superficial, th other inferior and deep. The former is the *transverse facial* (Pl XXI. fig. 3, *y*), which runs under the zygomatic ridge to th anterior border of masseter, where it is lost, anastomosing wit maxillary muscular and external maxillary arteries. The latte is the *masseter artery*, which at once plunges into the substanc of the masseter muscle, anastomosing with the maxillary muscu lar and posterior deep temporal.

The second terminal branch of the external carotid is th Internal maxillary (Pl. XXI. fig. 3), which commences at th inner side of the temporo-maxillary articulation just below th condyle, passes between the neck of lower jaw and greater cornu of os hyoides, where it describes two successive curves—the firs convex forwards, the second convex backwards. It now passe through the pterygoid foramen in the sphenoid bone and th external orbital hiatus; crossing the floor of the orbit, it enter the palato-maxillary foramen, maxillary hiatus, and palatine con duit, where it takes the name of the *palatine artery*. Th internal maxillary gives off several branches before entering th pterygoid foramen: two below—the inferior maxillary and ptery goid, and three above—tympanic, meningeal, and posterior deep temporal, within the pterygoid foramen, and from its uppe surface, the anterior deep temporal and ophthalmic; fro the lower part of the orbit, two below—the buccal and staphy line, and two above—the superior dental or infra-orbital an spheno-palatine.

The *inferior maxillary* or *dental*, given off from the middle o the first curve of the internal maxillary, passes downwards an backwards between the internal and external pterygoids, enter the posterior dental foramen on the inner surface of the ascend ing ramus of the lower jaw, accompanied by the inferior maxillar division of the fifth, passes onward in the bone supplying th

nolars and alveoli, dividing at the neck of the jaw into two branches—one supplying the tush and incisors, the other making its exit through the inferior maxillary foramen—anastomosing with the inferior coronary, and terminating in the gums and lower lip.

The *pterygoideal artery* arises from the second curve, and is distributed chiefly to pterygoid tensor and levator palati muscles.

The *tympanic artery* is a small branch which passes through the Eustachian tube to the walls of the tympanum.

The *meningeal* (Pl. XX. fig. 1, *n*), which enters the cranial cavity through foramen lacerum basis cranii, passing under the dura mater, to which it supplies numerous branches, coming out of the cranium again through the parieto-temporal conduit, and inosculating with the mastoid branch of the ramus anastomoticus.

The *posterior deep temporal* arises just as the main artery enters the pterygoid foramen; it passes directly upwards, ramifying in the substance of the temporal muscle, and anastomosing with the posterior masseter.

The *anterior deep temporal*, given off in the pterygoid foramen, passes upwards along the anterior border of the temporalis, supplying, in addition, the attolentes and neighbouring tissues.

The Ophthalmic (Pl. XX. fig. 1, *p*) is a large branch, which leaves the internal maxillary in the pterygoid foramen. It passes through the foramen lacerum orbitale, external orbital hiatus, gains the lower part of the optic fossa, then enters the cranial cavity through the foramen orbitale internus, and terminates in *meningeal* and lateral nasal. The former, after distributing branches to dura mater, falx cerebri, anastomoses at the base of the crista galli with its fellow and anterior cerebral. The *lateral nasal* passes through the cribriform plates of the ethmoid, enters the nose, and is distributed over the ethmoid cells and septum nasi. The ophthalmic gives off *muscular branches* to the muscles of the eye; the *ciliary arteries*, which

go to the globe, and are chiefly distributed to the choroid coat, ciliary processes, and iris; the *arteria centralis retinæ*, which leads through the centre of the optic nerve; the *supra-orbital*, which passes up the external wall of the optic fossa in company with the supra-orbital nerve, through the supra-orbital foramen, to be distributed to the skin of the forehead and muscles of the frontal region; the *lachrymal*, which runs between the muscles and upper wall of the socket, and terminates in the lachrymal glands and upper eyelid; finally, *cranial* branchlets, which pass into the cranium, and are distributed over the anterior lobe of cerebrum, anastomosing with the anterior cerebral.

The branches given off by the internal maxillary, after the ophthalmic, are *buccal* and *staphyline*, to supply the buccal glands and soft palate. Then comes the *dental* or *infra-orbital*, a large branch, which leaves the orbit through the posterior maxillary foramen, enters the superior maxillary bone, passing along the tops of the molar fangs, and, at the infra-orbital foramen, divides into two branches—one passing through the foramen, to be distributed over the cheeks, anastomosing with the superior labial, the other terminating in the tusk and incisors of upper jaw. The last branch of the internal maxillary is the *spheno-palatine*, which passes through the spheno-palatine foramen, and divides into branches which are distributed over the walls of the nose.

The terminal branch of internal maxillary is the *palatine* (Pl. XXI. fig. 1, *r*), which makes its exit at the posterior part of hard palate, through the palatine foramen; runs in a furrow on the lateral side of palate, through the foramen incisivum in front of the intermaxillaries, and anastomoses with its fellow, forming the *palato-labial*, which supplies the gum and lips.

VEINS.

General Anatomy.—Veins are vessels which return blood to the cardiac auricles, and consist of two sets—the pulmonary, which transmit arterial blood from the lungs to the left auricle; and systemic, which convey venous blood from the capillaries to the right auricle. They are more numerous and larger than the arteries, having an aborescent appearance. The smallest veins commence at the capillaries, converge to form larger ones, terminating in trunks which enter the heart. Arteries, on the contrary, diverge from the heart, diminishing in size until they terminate in the capillaries.

Veins are superficial and deep. The former lie immediately below the skin, unaccompanied by arteries; the latter are situated deeply, and usually related to arteries, hence called satellite. Two veins sometimes accompany one central artery. Veins anastomose more frequently than arteries. In the head they form dilated pouches or sinuses, and they form plexuses in the palate and foot. Sometimes arteries form plexuses, known as rete mirabile, the best example being in the meningeal branch of the ophthalmic in the ox and sheep. Veins are thinner in their coats than arteries, and collapse when cut across or emptied. After death, they are distended with blood, the walls thin, semi-transparent, and elastic. Their walls generally consist of three tunics—an internal serous, middle contractile, and external fibro-cellular. The internal tunic is similar to but less brittle than the arterial, consisting of two layers—an inner of epithelial, and an outer, containing nuclei and a dense lamellar net-work of pale yellow, longitudinal, elastic fibres. The middle tunic is composed of longitudinal and circular or transverse fibres of yellow elastic tissue, embedded in white fibres of areolar, and intermixed with involuntary muscular fibres or cells. In the smaller veins, the middle coat is more abundant than in the larger, especially its muscular tissue. Some maintain the middle coat is

awanting altogether in certain large veins, as the hepatic portion of vena cava. The muscular tissue is most abundant in the splenic and portal. The external tunic is the thickest of the three, and is composed of areolar tissue, with a few elastic fibres. These are arranged longitudinally, and adhere closely together. In some of the larger veins, there is an additional layer of smooth muscular fibres on the inner surface of the external tunic. This is well marked in the hepatic vena cava, in the trunks of the hepatic veins throughout, in the abdominal posterior cava, and can be traced in the renal vena azygos and external iliac. The outer coat is most dense where it joins the middle, becoming looser as it approaches the exterior of the vein, where it forms the sheath. In bones, as the veins do not contract, there are no muscular fibres. The majority are provided with valves, somewhat similar to the semilunar of the trunk arteries. These are folds of lining membrane, strengthened by fibrous tissue, and present an adherent and a free semilunar border when the valves are shut. They have a concave surface towards the heart, and a convex one towards the origin of the vein; they may consist of from 1 to 5 flaps, generally of 2 opposed to each other. The walls of the veins immediately above the valves are pouched into sinuses, which produces a knot or swelling. Their use is to favour the course of the blood and oppose its reflux from the heart. During its normal flow, they are placed against the walls, offering no obstacle to its onward flow. When the current is intercepted the valves are pressed back, the refluent column of blood gets between the concave surface of the flaps and dilated pouches, pressing them inwards until their edges, meeting in the centre, prevent a retrograde movement. Valves are always irregularly distributed, and are absent in the pulmonary veins, the trunk cavas, the cranial, spinal, pedal, and osseous veins, and in the fœtal umbilical vessels. They are only rudimentary in the portal, rare in the azygos, testicles, uterus, and ovaries; but numerous, large, and complete in the extremities. Their coats, like the arterial, are supplied with

capillary vasa vasorum. Their nerves, few and only traceable on the larger vessels, come from the sympathetic and spinal. Veins may originate from arteries without the intervention of capillaries, as in the erectile tissue of the penis.

The PULMONARY veins originate from the capillaries of the corresponding arteries in the walls of the air-cells and lesser air-tubes. By repeated union they become larger, ultimately converging to form eight trunks at the roots of the lungs, four in each. These again unite in their passage to the heart, forming four, which enter the left auricle by four openings. They are destitute of valves, which permits easy reflux of blood.

The SYSTEMIC veins commence in the capillaries, which by repeated union form, on entering the right auricle, three distinct groups—the cardiac or coronary, which open directly into the cavity of the auricle; and two large trunks, anterior and posterior venæ cavæ, which terminate by two openings. There is a set of systemic veins which neither go directly to the heart nor any large trunks—the veins of the abdominal digestive viscera, which unite to form the venæ portal, or which terminates in the hepatic substance.

The CARDIAC or CORONARY veins consist of one vena cordis magna and several small venæ cordis minimæ. The great coronary is formed by two branches: one is lodged in the right ventricular furrow, being a satellite of the descending branch of the right coronary artery; the other, a satellite of the left coronary artery, passes up the transverse furrow to the origin of pulmonary artery, then backwards, turning round the base of the left ventricle; finally, uniting with the right branch near the termination of the posterior cava, the common trunk enters the right auricle. At the coronary sinus, it receives branchlets from the ventricles and auricles; these have valves at their termination. The *lesser cardiac veins* are numerous, coming chiefly from the walls of the right heart, penetrating it by the foramina Thebesii in the right auricle.

The BRONCHIAL veins (Pl. XXV. fig. 3, *g''*), which return the

venous blood from the substance of the lungs, are satellites of, and disport themselves as the bronchial arteries at the root of the lungs. They form one vein, which enters the greater coronary just as it terminates in the sinus.

The Posterior vena cava (Pl. XXV. fig. 1. 1) returns the blood from the posterior extremities, abdominal, and pelvic viscera. It corresponds to the posterior aorta; it commences at the entrance of the pelvic cavity by the pair of common iliacs, runs forwards under the bodies of the lumbar vertebræ in contact with the psoas parvus, having the posterior aorta on its left. On reaching the superior border of the liver, it is inflected downwards. Leaving the sublumbar region, it enters the anterior fissure of the liver, plays through the foramen dextrum of the diaphragm, gains the thoracic cavity, passes through the notch in the right lung covered by a reflection of pleura, and enters the right auricle of the heart at its postero-external part. In the abdomen, it is related to the right kidney and pancreas. It receives the phrenic and hepatic, and through it the blood from the vena porta, renal, spermatic, and lumbar.

The Phrenic or Diaphramatic (Pl. XXV. fig. 1, *g*) commences in the fleshy portion of the diaphragm, forming two or three large branches, which finally enter the cava as it passes through the foramen dextrum.

The Hepatic (Pl. XXV. fig. 1, *f, f*) are very numerous, and commence by interlobular branchlets in the capillary terminations of the hepatic arteries and vena porta. These unite, passing upwards and forwards, unaccompanied by arteries. Leaving the gland in the anterior fissure, they enter the cava by a number of minute oblique openings, guarded by a valve. Two sets of hepatic veins are described, one returning the blood from the portal vein, the other from hepatic arteries.

The Portal vein (Pl. XXVI. fig. 2) arises in the sublumbar region near the anterior mesenteric artery, concealed by the pancreas, and is formed by the union of three large branches, which return the blood from the visceral organs of digestion.

PLATE XXV.

CIRCULATORY ORGANS—VEINS.

Fig. 1.—The Cavities of the Abdomen and Pelvis opened from the right side and the Viscera removed.

1. Posterior vena cava, so far as it lies in the abdomen. *a.* Right iliac vein. *b.* Left iliac vein. *b′.* Femoral vein. *b″.* Left hypogastic vein. *c.* Right ilio-lumbar vein. *c′ c′.* Lumbar veins of right side. *d.* Left internal spermatic vein. *e.* Right renal vein. *ff.* Hepatic veins. *g.* Right branch of phrenic vein.

Fig. 2.—Veins of Head and Neck exposed on right side.

1. External maxillary vein. *A.* Facial or labial vein. *a.* Coronary vein of upper lip. *b.* Vein from the angle of mouth. *c.* Coronary vein of lower lip. *c′.* Common trunk of both coronary veins. *d.* Angular vein. *e.* Dorsal nasal vein. *e′.* Lateral nasal vein. *f.* Superior communicating branch. *g.* Inferior communicating branch. 2. Internal maxillary vein. *h.* Superior parotid vein. *i.* Temporal vein. *k.* Posterior temporal vein. *l.* Transverse facial vein. *m.* Superior cerebral vein. *n.* External masseteric vein. 3. Inferior cerebral vein. 4. Jugular vein. *o o o.* Its muscular, œsophageal, and tracheal branches.

Fig. 3.—Cavity of the Chest opened from the right side, with the Anterior Vena Cana and the Vessels opening into it.

1 1. Anterior vena cava. *a.* Left axillary vein. *b.* Right axillary vein cut through. *c.* Left jugular vein. *d.* Right internal mammary vein. *d′.* Mediastinal vein. *e.* Right vertebral vein. *f.* Common trunk of superior cervical and dorsal veins. *f′.* Superior cervical vein. *f″.* Dorsal vein. *g.* Azygos vein. *g′.* Œsophageal vein. *g″.* Bronchial vein. *g‴ g‴.* Intercostal veins.

It is directed forwards, with an inclination to the right, crosses the pancreas below the vena cava, reaches the posterior fissure of the liver, and there divides into two branches, one for the right, the other for the left and middle lobe. Entering the gland, it is distributed like an artery, finally terminating in the hepatic vein. The branches which constitute the portal are anterior and posterior mesenteric, and splenic.

The Anterior mesenteric (Pl. XXVI. fig. 2, *b*) is large; its divisions exactly correspond with the branches of the anterior mesenteric artery. The Posterior mesenteric is made up of branches similar to those of the posterior mesenteric artery. The Splenic is very large, formed by the union of the left epiploic, splenic, and gastric satellites of the splenic artery, and the posterior gastric vein. The portal receives the right *gastro-epiploic*, *pyloric duodenal*, *pancreatic*, and *anterior gastric*, all satellites of the corresponding arteries.

The Renal veins (Pl. XXV. fig. 1, *c*) have very thin walls, and are formed by the union of the veinlets which leave the hilum of the kidney, and a branch from the supra renal capsules. The left renal having to cross the posterior aorta, is the longer.

The Spermatic (Pl. XXV. fig. 1, *d*) leave the testicles and enter the spermatic cord. On reaching the abdomen they communicate freely, forming the *spermatic plexus*, finally terminating in the cava near the renal, by one or two trunks. In the female, these become the *utero-ovarian*, which follow the exact course of the utero-ovarian arteries.

The Lumbar veins (Pl. XXV. fig. *c'*, *c'*) correspond to their satellite arteries, and result from dorsal, muscular, spinal, and abdominal parietal branches. They join the upper surface of the vena cava. The anterior ones often terminate in the vena azygos.

The Common iliacs are two large short vessels, formed by the union of the *external* and *internal iliacs* (Pl. XXV. fig. 1, *a*, *b*); the former collecting the blood from the posterior extremity, the latter from the hinder part of the trunk. They are lodged in

the angles of separation comprised between the external and internal iliac arteries, the right one, the shorter, passing above the external iliac artery to meet the left at the origin of posterior vena cava. The left one passes between the body of the last lumbar vertebra and terminal extremity of posterior aorta before it joins its fellow.

In studying the branches of the *external iliac*, it is advisable to commence at the foot. The venous plexuses of the foot unite to form two *plantar* veins, and these are succeeded by *three metatarsal*, the common origin of the four veins of the thigh, distinguished as superficial and deep. These are continued as *popliteal* and *femoral*, which end in external iliac. The veins of the foot are very numerous, and arranged in a superficial and interosseous net-work. They are valveless, allowing the blood to flow in either direction during sudden emergency. The *external* or *superficial plexus* are *solar*, *laminal*, and *coronary*. Those forming the Solar plexus are remarkable for the equality of their diameter throughout the entire extent of the plantar surface of the foot, as well as by the absolute absence of anastomoses with those of the deep seated parts. They chiefly terminate in the *large circumflex* which accompanies the artery of the same name. Receiving also descending twigs from the laminal plexus, it passes back to the wing of the bone, and thence into the *superior coronary plexus*. The remaining branches of the solar plexus reach the small central vein, situated at the semilunar ridge, on the sole surface, the central terminating in the superior coronary plexus.

The Laminal plexus rests on the wall of the os pedis. The branches, uniform in the sensitive laminæ, gradually increase in size as they approach the coronet, where the majority terminate in the *coronary plexus*, the remainder passing to the circumflex vein.

The Coronary plexus surrounds the os coronæ and upper part of the os pedis. Passing backwards below the lateral cartilages, the plexus divides into an anterior or middle and two lateral branches. The *middle coronary* lies in front of the foot,

and receives the anterior ascending branches of the laminal plexus, uniting to form the *superior coronary*. The *lateral coronary* are situated under the lateral cartilages, and formed by the posterior branches of the laminal, by veins from the coronet ligaments and tendons, all of which join and form the *deep coronary*. The *veins of the frog* extend over the external surface of the fatty frog, ascend the sides of the lateral cartilages, and unite to form a large vein, which, with the superficial and deep coronaries, run up the lateral aspect of os coronæ, uniting at its head to form the *plantars*.

The deep *internal* or *interosseous veins* of the foot form a system of satellites to the circulus arteriosus. These pass out of the bone through the plantar foramina, at each side of the tendinous surface; thence up the inner side of the lateral cartilages, finally uniting with the branches of the lateral coronary sinuses.

The PLANTAR veins, formed by the union of the deep and superficial coronary and veins from the frog, ascend the leg in company with the plantar arteries and nerves, and terminate a little above the fetlock, by uniting to form an arch between the flexor tendons and suspensory ligament. From this arch —the *sesamoideal*—spring the three metatarsal veins. The plantars receive branches corresponding to the perpendicular and transverse division of the plantar artery, as well as twigs from surrounding structures.

The METATARSAL veins are three—internal, external, and deep —originating in the sesamoidal arch, formed by the anastomoses of the plantars. The *internal* is the largest, and appears to be a continuation of the internal plantar. It passes up the cannon bone, internal to, and a little in front of, the flexor tendons, accompanied by the internal plantar nerve. Nearing the hock, it courses obliquely to the anterior surface of the joint, where it communicates by a large transverse branch with the origin of the anterior tibial. It now runs along the inner surface of the leg, forming the *anterior root of the internal saphena*. The

external metatarsal vein occupies a position on the outer side of the flexor tendons, analogous to that of the internal. Towards the superior extremity of the cannon, it anastomoses with the deep vein, then continues its course upwards, accompanied by the metatarsal artery, gains the hock, plunging deeply into the hollow on the inner and lower end of os calcis, along with the popliteal nerve, and there forms the *posterior root of the internal saphena vein.* The *deep metatarsal* vein originates below the flexor tendons, and passes up underneath the inferior tarsal ligament to the inner side of metatarsal artery. Below the hock, it receives the large anastomotic branch from the external vein, plays through the channel formed by the cuboid and cuneiform bones at the back of the joint, finally forming the principal branch of the *anterior tibial vein.*

Above the hock there are four large veins—a deep-seated pair, the anterior and posterior tibial; the other superficial, the internal and external saphena.

The Anterior tibial is a satellite of the corresponding artery. It is frequently double, arising on the anterior surface of the hock, in the centre of a venous plexus, by the deep metatarsal. Several branchlets of this plexus run up the leg, between the tibia and fibula, and at the lower end of the femur joins the posterior tibial to form the popliteal.

The Posterior tibial commences in the hollow in front of os calcis, principally by the two saphenæ. It passes up the leg, along with the posterior tibial artery, and under the popliteal muscle unites with the anterior tibial.

The superficial saphena veins are the Internal or Vena saphena major, which originates by two large roots at the inner part of hock. The *anterior* is a continuation of the internal metatarsal, the *posterior* of the external metatarsal. These converge, and form one large vessel on the internal surface of the tibia. The vein now ascends the inner surface of the thigh, and terminating near the groin, may either pass through the interstices between the adductor longus and brevis, entering the

moral, or end, near the origin of the gracilis, in the venæ profundæ femoris.

The External saphena or Vena saphena minor, originates at he back of the os calcis, anastomosing with the posterior root f the internus, with which, above the hock and in front of os alcis, it forms a large plexus of veins. It also anastomoses ith the posterior tibial by a large branch, which passes between he tibia and flexor pedis perforans, and dips behind the tendons of the gastrocnemii, in company with a nerve terminating ear the hip joint in the popliteal.

The Popliteal, formed by the union of the anterior and posterior tibials, is a satellite of the popliteal artery, and receives branches corresponding with 3 given off from it. The principal ne is the *femoral popliteal*, which enters with the external aphena.

The Femoral (Pl. XXV. fig. 1, *b'*), a satellite of the artery, is continuation of the popliteal. Its branches are similar to those f the femoral artery, with the addition of the *internal saphena*, which joins about its middle third. The femoral terminates in he external iliac.

The External iliac is a continuation of the femoral, and is he larger of the two branches, which form the common iliac. In ts course, this vein, which commences at the femoral, and proceeds over the anterior body of pubis, receives several collateral branches, the chief of which is the *circumflex* vein of the ilium, satellite of the corresponding artery; and the *inguinal* subutaneous abdominal, arising in the abdomen as far forward as he costal cartilages, where it anastomoses with the thoracic eins in cows. This is the conspicuous *milk vein*.

The Internal iliac, a trunk which, with the external, forms he common iliac, is very short, and formed by the union of atellites, corresponding to the branches, given off from the interal iliac artery. The *anterior vena cava* is the venous trunk, hich returns the blood from the head, neck, fore extremities, nd thoracic viscera. This large but short vessel is situated at

the anterior part of the thorax, between the layers of the anterio mediastinum below the trachea, and to the left of the anterio aorta. It terminates in the supero-posterior part of the righ auricle, and is formed by the union of the jugular and axillary veins, receiving the internal thoracic, vertebral, superior vertica dorsal, and vena azygos accessorius.

The Internal thoracic, Vertebral, and Superior cervical are satellites of, and counterparts in distribution to, their corre sponding arteries.

The Dorsal follows the same course as the dorsal artery receiving also several intercostal branches, the right one re turning the blood from second to fifth intercostal spaces; the left sometimes called the *lesser vena azygos*, is prolonged as far back as eleventh or twelfth intercostal spaces, receiving blood from the intercostal veins of all the spaces it crosses.

The Right vertebral, Supero-cervical, and Dorsal, reach the vena cava separately, whereas those on the left enter by a common trunk.

The Vena azygos is a long single branch, whose radicles origi nate near the first lumbar vertebra. It plays forwards on the right side of the anterior aorta below the bodies of the dorsa vertebræ, reaching the sixth. It becomes inflected downwards and terminates in the anterior vena cava. It receives branches from the spinal and psoas muscles, the posterior thirteen right, six or seven left intercostals, œsophageal, and bronchia veins.

The Axillary veins (Pl. XXV. fig. 3, *a*, *b*), the largest trunks which enter into the construction of the vena cava receive all the blood from the anterior extremity, several large subcutaneous thoracic, as well as branches corresponding t those of the axillary artery, viz., subscapular, humero—thoracic dorsalis scapulæ, and subcutaneous thoracic or spur vein, the humeral and its branches, anterior and posterior radial and ulnar veins, two superficial brachial veins, three metacarpals, two plantars, and the pedal plexuses.

The PEDAL PLEXUSES and plantar veins are identical with hose of the hind leg.

The METACARPAL veins are external, internal, and interosseous. 'he *internal*, the largest, passes up the leg to the side of the exor tendons, in company with an artery and nerve, the vein eing in front, the artery in the centre, reaching the back of he knee; it is continued as the *internal subcutaneous*. It orms a free anastomosis with other metacarpal veins, receiv- ig branches from the joint. The *external metacarpal* is ituated on the external side of the flexor tendons, accompanied y the corresponding plantar nerve, and receives branches from he skin and adjacent structures. On reaching the under part f the trapezium, it divides into numerous branches, which either nastomose with those of the internal or join the posterior radial nd ulnar. The *deep* or *interosseous* is very irregular and flexu- us, and may be double. It passes up the leg between the pos- erior surface of the common bone and suspensory ligament. At he head of the metacarpus, it splits up to unite with branches of he external and internal. It now ascends behind the knee by one r two small branches, which unite to form the posterior radial.

The POSTERIOR RADIAL OR SPIRAL is a continuation of the meta- arpal, terminating at the lower end of the humerus in the umeral. It is always accompanied, and in a great measure nveloped by, 3 or 4 venous branches, that freely anastomose ith and result from the terminals of the deep metatarsals.

The ANTERIOR RADIAL follows a course similar to the anterior dial artery, receiving satellite equivalent branches to that of he artery.

The ULNAR or cubital courses with the ulnar artery, receiving uscular and cutaneous branches, terminating at the inferior xtremity of the humeral. It is sometimes double in the latter art of its course.

The *superficial* or subcutaneous veins of the *fore-leg* are *ternal* and *internal*, separated from the skin and fascia of the m by a thin partition.

The INTERNAL BRACHIAL ascends the leg on the inner side of the radius, at the superior extremity of which it passes obliquely forwards, and terminates by two large branches—the basilar and cephalic. The *basilar* crosses the pectoralis transversus, and terminates in the humeral. The *cephalic* passes over the flexor brachii to the interstices between the pectoralis anticus and levator humeri, emptying itself into the irregular vein.

The EXTERNAL SUBCUTANEOUS BRACHIAL is much smaller than the internal, and ascends the leg on the anterior surface of the radius, terminating at the superior extremity by uniting either with the internal or cephalic.

The SPUR vein, or SUBCUTANEOUS THORACIC, commences by numerous branches in the flank, which unite in one common trunk. Posteriorly it lies near the external surface of the panniculus, being directed along the superior border of the pectoralis magnus; it then dips into the caput muscles, terminating in the humeral, sometimes in the axillary.

The HUMERAL is a satellite of the corresponding artery, and lies behind it, commencing above the elbow by the union of the brachial and articular branches. It terminates in the AXILLARY, which commences at the scapulo-humeral articulation, formed by the continuation of the humeral, and branches corresponding to the axillary artery, viz., subscapular, dorsalis scapulæ, humeral, and thoracic; along with the artery, it winds round the first rib, enters the thorax, uniting with its fellow and the jugulars to form the anterior vena cava.

The JUGULAR (Pl. XXV. fig. 3, *c*, and fig. 2. 4) commences by two branches, the superficial temporal and internal maxillary, just behind and below the temporo-maxillary articulation. The *lateral* branches, entering the jugular, are the superficial and deep maxillary, posterior auricular, occipital, glosso-facial or submaxillary, thyroid, and cephalic. The *maxillary* branches correspond with the maxillary arteries. The *posterior auricular*, which commences under the ear, descends over the parotid, where it receives numerous branches, and enters the jugular

ust below, and on the opposite side of the preceding. The *ccipital*, a satellite of the ramus anastomoticus, returns blood rom the brain, spinal cord, and muscles about the poll.

The *thyroid*, a large vessel formed by the laryngeal and thyroid eins, gains the jugular near the termination of the glosso-facial.

The *cephalic* enters at the inferior extremity of the jugular, nd is a satellite of the pectoral branch of the inferior cervical rtery. The last lateral branches of the jugular are several ameless ones, which return blood from the parotid gland and ervical muscles.

The *glosso-facial*, external or submaxillary (Pl. XXV. fig. 2. 1, nd description of plate), a satellite of the equivalent artery, ommences by two branches: the superior or angular comes from he angle of the eye; the inferior or dorsalis nasi, from the upper art of the nose. It descends along the anterior border of asseter, and winds round the lower jaw, between the artery nd Steno's duct; and below the internal masseter, at the ntero-inferior border of the submaxillary gland, it leaves the rtery, and enters the jugular at an acute angle. The lateral ranches of the glosso-facial, in addition to a small nasal twig, re vena varicosa, dental, palatine, nasal, superior and inferior oronaries, submaxillaries, buccal, lingual, and sublingual. The *uperior communicating*, or *vena varicosa* (Pl. XXV. fig. 2, *f*), s peculiar in form and disposition, being buried under the asseter, between the zygoma and alveoli of upper molars; its nterior extremity opens into the superior maxillary vein; its osterior passes through the optic fossa to the maxillary hiatus, here it receives the nasal and superior dental satellites of the rresponding arteries, superior and posterior dental, spheno-alatine, palatine and staphyline, from the soft palate; in the ular fossa, it receives the veins from the eyes, inferior eyelid, e ciliary, ophthalmic, posterior nasal, and the rami cerebrales ferioris, which communicate with this cavernous sinus through e foramen lacerum orbitale. Accompanied by the ophthalmic rve, three primary branches, from the teeth, palate, and nose,

enter the glosso-facial separately, sometimes by one trunk; c
receiving these, it winds round the maxillary tuberosity, formin
a large venous reservoir, which diminishes before entering th
superior maxillary. The use of this reservoir is to prevei
congestion in the cavernous sinuses, by continuing to receiv
venous blood during the time circulation might be arrested b
the motion of the jaw. The *superior* and *inferior coronary* (Pl.
XXV. fig. 2, *a*, *c*, *c'*) are the next branches, the inferior bein
the larger. The *buccal* or *inferior communicating* (Pl. XXV
fig. 2, *g*), resembles the vena varicosa, and is a satellite of th
buccal artery; it lies under the masseter, along the inferio
border of the buccinator, anteriorly communicating with th
glosso-facial near the function of the inferior labial; posterior
with the internal maxillary, receiving twigs also from the mout
and masseter muscles,—branches from the submaxillary glan
tongue, and sublingual likewise join the glosso-facial.

The *lingual* is a satellite of the artery and hypo-glossal nerv
The inferior dental comes from the lower jaw. The deep a
terior and posterior temporals are situated below, and to th
inner side of the articulation, communicating with the masseti
The pterygoid come from the pterygoid muscles, and the othe
from the sinews of dura mater. They form a net-work on t
surface of the muscle, which communicates posteriorly with t
superficial, and anteriorly with the deep temporal; betwe
these and behind the jaw is one of the most complete interla
ments of veins in the whole body.

The *superficial temporal*, one of the origins of the jugular, a
a satellite of the corresponding artery, is situated behind t
posterior border of the jaw, near the temporo-maxillary artic
lation, buried in and under the parotid gland. It results fr
the union of the anterior auricular and subzygomatic or tra
verse veins; its branches are the anterior auricular, transver
facial, and masseter. The large anterior auricular anastomos
with the pterygoid branch of the internal maxillary: this m
be replaced by a plexus.

The *subzygomatic* is divided into two branches, the transverse, a satellite of the equivalent artery, and the masseter, which anastomoses with the maxillo-muscular inferiorly, and with a deep temporal branch of the internal maxillary superiorly.

The *internal maxillary* (Pl. XXV. fig. 2. 2), a large vessel situated between the masseter internus and maxillary bone, runs obliquely upwards and backwards, reaching the maxillary articulation just below the condyle of the lower jaw, where, after turning slightly downwards, it joins the superior temporal; it originates in the buccal, near the superior extremity of the buccinator. Its branches are the dorsalis linguæ or lingual, the inferior dental, deep temporals, pterygoids, superior cerebral, and other corresponding satellites of the internal maxillary artery.

Circulation of the Fœtus.

In the fœtus, there is a direct communication between the right and left auricles, by the foramen ovale in the septum auricularis, and a very large Eustachian valve, situated at the anterior border of the posterior vena cava at its entrance into the auricle, which directs the blood from the posterior vena cava through the foramen ovale into the left auricle. The next difference between the fœtus and adult is a communicating branch between the pulmonary artery and posterior aorta, called the *ductus arteriosus*. Then there are two large arteries, the *umbilical* or *hypogastric*, which arise from the internal iliacs, pass along the sides of the bladder to its fundus, and out of the umbilical opening, and are continued along the umbilical cord to the placenta; in their course down the cord they wind round the umbilical vein. Finally, the *umbilical vein* enters the umbilicus, passes along the floor of the abdomen, reaches the liver, and joins the venæ portæ. There is no ductus venosus. These briefly are the extra-fœtal vessels. We now trace the course of the circulation. The arterial blood leaves the placenta by the umbilical vein, which is formed by the junction of

numerous radical capillaries, and passes down the umbilical cord accompanied by two arteries; on reaching the abdomen, it travels along the internal face of the abdominal wall covered by peritoneum, and thus arrives at the liver; joins the portal vein, and passes through the gland in the venæ portæ, then enters the hepatic veins, and by them gains the posterior vena cava, and mingles with the venous blood from the posterior extremities. The mixed blood is emptied by the posterior cava into the right auricle, passes directly through the foramen ovale into the left auricle, guided by the Eustachian valve; from the left auricle it enters the left ventricle, and by it is forced into the aorta; the major part passing into the anterior aorta, is distributed to the head and fore extremities; the remainder passes into the posterior aorta. Venous blood is returned from the fore extremity to the heart by the anterior vena cava to the right auricle, and passes directly into the right ventricle with a small portion of blood from posterior vena cava; the right ventricle propels it through the pulmonary artery, from which only a small portion passes into the *impervious lungs*, to be returned to the left auricle by pulmonary veins, the greater part going through the ductus arteriosus into the posterior aorta, where it becomes mixed with a small portion of blood from the right ventricle. In the posterior aorta, it glides backwards to supply posterior extremities and abdominal viscera. The chief portion, however, on arriving at the termination of posterior aorta, enters the umbilical arteries, and by them is returned to the placenta to be purified. *At birth*, when respiration has been established, the placental circulation is cut off, the foramen ovale closes up in about ten days, leaving the fossa ovalis, the ductus arteriosus contracts, and the umbilical arteries and veins become obliterated.

LYMPHATICS.

The *lymphatics* consist of a system of vessels, and numerous ganglia or glandiform bodies through which they pass.

They are called lymphatics, because they convey a clear limpid fluid; and absorbents, because they absorb alimentary matter. The absorbents of the chyle, or milky fluid, prepared during digestion, are called *lacteals*, or chyliferous vessels, but do not differ in character or anatomical structure. The lymphatics unite to form two large trunks—the thoracic canal or duct, and the right lymphatic vein—which enter the venous system near the heart. They are uniform, delicate, transparent, and are present in every tissue except the eyeball, brain, spinal cord, cartilage, tendon, placenta, ovum, umbilical cord, and bone. They are more numerous than, but resemble the blood-vessels; their collective capacity is not, however, greater. They are placed superficial and deep; the former run below the skin or membranous tunics; the latter generally accompany deep-seated blood-vessels, and originate in a delicate net-work, which proceeds to a large trunk, or passes directly to a lymphatic gland.

The *lymphatic conglobate glands* are small, round, or oval, varying in size from a hemp seed to a kidney bean, of a pale red colour, and consist of a cortical substance which occupies the external part of, and forms septæ within the gland, dividing it into numerous polygonal cavities, called *loculi* or *alveoli*, which are filled with a whitish pulp formed of cells and nuclei, identical in character with lymph corpuscles, and called the *medullary substance*. These loculi are traversed by very delicate trabeculæ and plates given off from the septæ, which divide into very minute cavities communicating with each other, forming a spongy texture enclosed in the medullary substance. The absorbents and lacteals, just before reaching the glands, divide into the afferent vessels, or *vasa afferentia*, which enter the gland; these again subdivide into intricate plexuses, which open into the spongy cavities, whence fine canals pass to join the central medullary plexus, and originate vessels which lead to those emanating from and leaving the gland—the *vasa efferentia* or efferent vessels. The efferent, fewer, but larger than the afferent, after a short course, unite into one or more trunk lymphatics.

They are very transparent, the contained fluid being distinctly visible. Their walls consist of three coats. The external is composed of a net work of interlacing areolar tissue, mixed with longitudinal fibres of elastic, and oblique fibres of smooth, muscular, tissue. This coat connects the vessels to its surroundings. The middle is thin, highly elastic, consisting of smooth, muscular fibres interlaced with areolar and elastic tissue. The internal is merely a basement membrane of elastic tissue, covered by a simple layer of scaly epithelium; it is liable to rupture, giving way when the vessels are unduly distended.

The sides of the lymphatics are beaded and sinuous, arising from the disposition of *valves* in their interior, which aid the onward flow of their contents. These generally consist of two semilunar flaps, with an attached convex and a free concave border—sometimes, however, of a single circular or spiral fold; they do not exist in all lymphatics, and are most numerous in the proximity of glands, and are always found where the lymphatic trunks enter the blood-vessels.

Lymphatics may pass through two or more glands, or enter a central trunk without approaching one.

The Thoracic duct (Pl. XXVI. fig. 1), the largest and longest lymphatic, receives all the lymphatics, except those of the right anterior extremity, and right side of the head, neck, and thorax; it originates in the lumbar region between the posterior aorta and vena cava, by a very irregular dilatation called the *receptaculum chyli*, or reservoir of Pecquet, into which flow the contents of the principal lymphatics. From the anterior aspect of this reservoir, the duct proceeds forwards on the right side of the vertebral column, enters the thoracic cavity through the aortic hiatus of the diaphragm, passes along the vertebræ until it reaches the sixth dorsal, where it curves downwards to the left side over the base of the heart, forwards to the beginning of anterior vena cava, terminating in the left axillary vein against the centre of the anterior border of first rib; it may empty itself into the right axillary or even anterior cava. Its orifice is dilated

Plate XXVI THORACIC DUCT AND PORTAL VEIN

PLATE XXVI.

THORACIC DUCT AND PORTAL VEIN.

Fig. 1.—Cavity of Chest opened from the right side.

1. Portion of aorta. 2. Trachea, divided at its entrance into the chest. *a a*. Right and left branches of thoracic duct, which at its commencement is double. *b*. Point of union of both branches. *c c*. Branches which arise from the thoracic duct, and again open into it. *d*. Point where the thoracic duct opens into axillary vein. *e*. Right lymphatic duct. *e'*. Point of junction of right and left thoracic ducts.

Fig. 2.—Portal Vein, with its branches.

1. Spleen. 2. Stomach. 3 3. Coils of small intestine. 4. Cæcum. 5. Colon. 6 6. Rectum. 7. Pancreas. 8. Liver. *a a*. Main trunk of portal vein. *b*. Anterior mesenteric vein. *b' b'*. Veins of small intestine. *b''*. Ileo-colic vein. *b'''*. Colic vein. *c c*. Posterior mesenteric vein. *d*. Gastro-splenic vein. *d'*. Superior coronary vein of stomach. *d''*. Splenic vein. *d'''*. Short veins (vasa brevia) of stomach.

nd guarded by a valve, which prevents the reflux of blood; it s united to the vein by a ligamentous band; it may be double when we have a right and left—double at its origin only, or ingle at its origin; then bifid for a short distance, again forming a single trunk; it contains few valves, and these at regular ntervals, giving it a varicose appearance. The short second ymphatic trunk is the lymphatic vein, or *ductus lymphaticus dextra*, situated at the junction of the jugular veins, and terminating in the gulf of the jugular; it is also guarded by a valve, nd receives the lymphatics from the right anterior extremity, ight side of head, neck, and thorax.

The lymphatics, which form the affluents of the thoracic canal, re divided into five groups—(1.) Embraces the lymphatics of he posterior extremity, pelvis, abdominal walls, and organs of elvic region. (2.) Those of abdominal digestive viscera. 3.) Those of the organs contained in the thorax. (4.) Those of he thoracic walls. (5.) Those of head, neck, and anterior extremity. The first series converge to a large group of ganglia, he sublumbar, presenting, however, at different parts of their assage, other groups, constituting the deep and superficial, inguinal, popliteal, iliac, and pre-crural ganglia.

Lymphatics of Posterior Extremity, Pelvis, Organs of Pelvis, and Abdominal Wall.—The *sublumbar ganglion* occupies the sublumbar region, resting in the angles formed by the bifurcation of the posterior aorta, extending as far forward as he posterior mesenteric and spermatic arteries. This ganglion receives the lymphatics of the pelvis, the emerging branches of he deep inguinal, and iliac ganglia-branches from the rectum, louble colon, and spermatic cord. The numerous efferent branches of the sublumbar ganglion, after forming one or more runks, terminate in the receptaculum chyli.

The *deep inguinal ganglion* is formed by a considerable number of lobes lodged under the aponeurosis and crural arch, in the nterstices between the adductor muscles of the thigh, along with, and to the inner aspect of, the crural vessels. The group

is elongated, and superficial exteriorly, reaching almost to the anterior pubic border. The colour of the lobes varies from grey, through brown, to almost black. The efferent vessels are formed by the superficial lymphatics, which accompany the internal saphena vein, and those originating in the deep solar surface of the foot, which, arranged as two trunks, accompany the deep veins of the leg. The efferent branches of this ganglion pass into the sublumbar plexus, entering the abdomen in company with the external iliac vessels.

The *superior inguinal ganglion* is placed in front of the inguinal ring at the side of the sheath. It is oblong, and consists of ten or twelve lobules. The afferent vessels are numerous, and receive the lymphatics from the internal part of the thigh, sheath, scrotum, and inferior abdominal walls. The efferents, larger, but less numerous, pass up the inguinal canal in company with the posterior abdominal artery, and terminate in the deep inguinal ganglion.

The small *popliteal ganglion* is formed of three to five lobules, situated just behind the great sciatic nerve and gemini muscles, and between the adductor magnus and biceps rotator tibialis, towards the femora-popliteal artery. It receives the lymphatics from the posterior part of the haunch and croup. The efferents join the deep inguinal ganglion, passing through the interstices of the thigh muscles.

The *iliac ganglion* consists of five or six lobules, which form a soft yellow group, situated in the triangular space between the two branches of the circumflex artery of the ilium. They receive the efferents from the anterior crural ganglia, and numerous deep lymphatics from the abdominal walls. The five or six efferents follow the circumflex artery, and terminate in sublumbar ganglion.

The *pre-crural ganglion* rests on the inner side of the anterior border of the fascia lata, upon the circumflex artery, and consists of a small elongated mass, composed of about twelve lobules. It receives the lymphatics from the antero-internal part of the

thigh. Its three or four efferents are very large, passing up the internal face of the fascia lata. They enter the abdominal cavity towards the angle of the haunch, and join the iliac ganglion.

The Lymphatics of the Abdominial viscera are the *lymphatics of the rectum* and those of the *floating colon*. There are two or three lobules at the base of the tail on each side of the sphincter, a series of ganglia along the small curve of the viscera, the ganglionic bodies, comprised between the layers of the mesentery, and the radical lymphatics, lying in the mucous and fleshy coats of the intestines generally. The efferent vessels of the mesenteric ganglia traverse the glands placed on the passage of the blood-vessels, and reassemble towards the origin of the posterior mesenteric artery by numerous large branches, which join the divisions of the lumbar plexus, with those of the double colon.

The *lymphatics of the large colon*.—Under this viscus a double chain of ganglia accompanies the colic arteries. Numerous small lobules, at equal distances from the principal ganglia, are disseminated over the lateral branches of the blood-vessels. The lymphatics emanating from the coats of this intestine pass for the most part into these small lobules, afterwards joining the principal ganglia, whence they emerge as numerous large satellites of the colic blood-vessels. These, and the lymphatics of the small intestines, unite to form the two great mesenteric trunks, which, with the efferent branches of sublumbar plexus, form the reservoir of Pecquet.

The *lymphatics of the cæcum*.—The ganglia of this gut are found along the passage of the cæcal arteries, constituting a series not so close as those of the colon, into which are received the lymphatic vessels of the membranes of the cæcum. These, on leaving the glands, form larger branches, which are satellites of the blood-vessels, and enter the same trunk as those of the small intestines.

The *lymphatics of the small intestines*.—The lymphatic ganglia, which receive the lacteals of these intestines, are very compact,

about thirty in number, of a grey colour, large, fusiform, and bifurcated at their superior extremity. They are closely packed in the mesentery, near the origin of the anterior mesenteric artery. Besides these larger ganglia, there are about fifty smaller lobules dispersed along the course of the ilio-cæcal artery.

The *lymphatics of the small intestines* form a large net-work, superficial and deep seated, converging from the visceral walls to the smaller glands, thence to the larger and mesenteric, which they enter at the superior extremity. The efferent glandular branches, usually two or three, unite to form larger ones, which finally join the intestinal branches of the receptaculum chyli.

The *lymphatics of the stomach.*—The ganglia of the stomach are divided into two classes—a large series, situated in the lesser, and a chain of smaller ones, distributed along the greater curvature, and attached to the gastro-colic omentum. The deep and superficial lymphatics of the stomach enter these glands, collecting on the blood-vessels, pass up towards the greater cul-de-sac near the cœliac axis, where they anastomose with branches from the spleen and liver, forming large flexous trunks, some of which enter the thoracic duct. Others pass backwards to the trunks of the intestinal lymphatics.

The *lymphatics of the splen.*—Those of the spleen are deep and superficial—the former in the parenchyma, the latter on the surface. They all pass to the branches of the vessels in the hilum, enter numerous groups of glands, and are dispersed along the blood-vessels, anastomosing with those of the stomach and liver.

The *lymphatics of the liver* consist of a deep series in the parenchyma of the gland, and a net-work of superficial ones on the capsule. They assemble towards the posterior fissure, and entering a group of small ganglia, pass into a much larger group situated between the trunk of venæ portæ and pancreas. Their efferents anastomose with those of the stomach and spleen.

Lymphatics of Organs situated in the Thorax.—There are three groups of lymphatic glands—a series of small ones in the posterior mediastinum, which receive the lymphatic vessels of the

osterior part of œsophagus, the bronchial glands situated at the ngle of bifurcation of the trachea, and stretching a short dis- nce into the parenchyma of the lungs, and receiving their mphatics; two series of glands, extending along the sides of ne inferior face of trachea to the base of the heart—the one re- ives the lymphatics from the pericardium and heart, the other om the trachea and anterior part of œsophagus. Their efferents nite to form two or three trunks which enter the thoracic canal n different places.

Lymphatics of Thoracic Wall.—There are also three sets—a ouble chain of small round glands, situated on each side of the orsal vertebræ above the intercostal spaces, and under the costal leura; a large glandular mass, resting on the ensiform cartilage, ust behind the heart and in front of the inferior part of the liaphragm; and a group of rudimentary glands, which accompany he internal thoracic artery.

The *lymphatics of the diaphragm*, after receiving those from the onvex face of the liver, enter the ganglia at the antero-inferior xtremity of the diaphragm, leaving them by numerous branches which accompany the internal thoracic artery, and either join the nterior extremity of the thoracic duct or great lymphatic vein, sually after passing through the pre-pectoral ganglia. They eceive the lymphatics from the inferior part of the intercostal spaces. The other lymphatic vessels of the thoracic walls run pwards in the intercostal spaces, and enter the chain of ganglia long the side of the dorsal vertebræ, forming two canals, which pass forwards to enter the anterior portion of the thoracic duct.

Lymphatics of Head, Neck, and Anterior Extremity.—These are directed to the entrance of the thorax, and unite to form a group of ganglia, termed the pre-pectoral, which may be regarded as the lymphatic glands of the whole anterior, as the sublumbar is of the posterior part of the body. Before the vessels reach this point of convergence, they are intercepted by four glandular groups, the guttural or pharyngeal, submaxillary, pre-scapular, and brachial.

The *pre-pectoral ganglia* are formed on each side of the ter minal extremity of the jugular veins, and to the inner inferior border of the scalenus; they are massive, passing into the chest under the axillary vessels, and along the internal aspect of the first ribs. Entering these ganglia, are the emerging lymphatic branches of the pre-scapular and axillary ganglia—those from the pharyngeal ganglia, which descend the trachea with the carotid artery, branches from the pharyngeal ganglia, as well as most of those which accompany the internal thoracic vessels. They afford numerous short and voluminous branches—those of the right side forming the lymphatic vein of the left, joining the thoracic canal, betimes reaching the anterior cava by a single trunk.

The *pharyngeal ganglia* are numerous, and attached slightly to each other. They are disposed in an elongated mass which occupies the lateral wall of the pharynx below the guttural pouch, reaching almost to the thyroid gland. They receive all the lymphatics of the head, from the base of the tongue, soft palate, walls of the larynx and pharynx, submaxillary plexus, and a lobule lodged in the substance of the parotid gland. The efferents form four or five large branches, which descend the trachea singly, or united into a bundle which follows the carotid; numerous elongated ganglia receive the radical lymphatics from the cervical portion of the trachea and œsophagus. On arriving at the entrance of the thorax, the efferents enter the pre-pectoral ganglia; one branch sometimes passes directly to the thoracic duct on left, or the lymphatic vein on right side.

The *submaxillary ganglia* is a fusiform mass situated at the base of the tongue, between the digastric and mylo-hyoid muscles, and a little above the submaxillary artery it receives the lymphatic vessels from tongue, cheeks, lips, nose, and nasal cavities; the efferent vessels going to the pharyngeal or guttural ganglia.

The *pre-scapular ganglia* is formed by the union of a chain running in the course of the ascending branch of the inferior cervical artery under the internal face of the levator humeri, and descending to the insertion of the sterno-maxillaris.

The *cervical lymphatics*, superficial and deep, enter this ganglionic chain as well as those from the breast and the majority from the shoulder; their efferents, short and voluminous, pass to the pectoral glands.

The *brachial ganglia*, situated under the shoulder, consist of two groups—one near the elbow to the inside of the inferior extremity of the humerus, receiving the lymphatics of the foot and fore-arm, which accompany the superficial veins, or creep up the interstices of the muscles with the deep vessels; the other disposed in a mass behind the brachial vessels, near the common insertion of the latissimus dorsi and teres internus. It receives nine or ten lymphatic branches from the shoulder and arm. The efferents accompany the axillary vessels, and enter the pre-pectoral ganglia.

THE NERVOUS SYSTEM.

General Anatomy.—The nervous system may be regarded as consisting of two sets of organs, peripheral and central, the function of one being to establish a communication between the centres and the different parts of the body, and that of the other to generate the nervous force. The former is composed of numerous white fibres, and the latter partly of fibres and partly of grey vesicular elements, termed nerve cells. The whole may be arranged under two divisions—1*st*, The cerebro-spinal or nervous system of animal life; and 2*d*, The sympathetic, ganglionic, or nervous system of organic life. Each is possessed of its own central and peripheral organs.

In the first, the centre is made up of two portions—one large and expanded (the brain or encephalon), placed in the cranial cavity; the other elongated (the spinal cord), continuous with the brain, and lodged in the canal of the vertebral column. The peripheral portion of this system consists of the cerebro-spinal nerves, which leave the axis in symmetrical pairs, and are distributed to the skin, the voluntary muscles, and the organs of common and spinal sensation.

In the second, the central organ consists of a chain of ganglia connected by a nerve cord, which extends from the head to the coccyx on each side of the spine. The nerves of this system are distributed to the involuntary muscles, mucous membrane, viscera, and blood-vessels. The two systems have free intercommunication, ganglia being placed at the junctions.

Two substances, distinguishable by their colour, enter into the formation of nervous matter, viz., *the white* or *medullary*, and the *grey*, *cinerilious*, or *cortical* substances. Both are soft, fragile and easily injured, in consequence of which the principal nervous centres are always well protected by bony coverings. When examined under the microscope, two distinct structure-elements —fibres and cells—are found; the fibres being of two kinds white or tubular, and grey or gelatinous, the former being most abundant.

The *tubular fibres*, which form the white matter of the brain, spinal cord, and nerves, and are also met with in the ganglia and nerves of the sympathetic system, have three distinct components—1*st*, An external envelope, the *neurilemmal* tube, fine transparent, and nearly homogeneous; 2*d*, A layer of white matter, the *medullary sheath;* and 3*d*, The *cylinder axis* or *primitive band*, in the centre of all. The diameter of these fibres varies between $\frac{1}{1500}$th and $\frac{1}{3000}$th of an inch, though some are much less.

The *grey*, *gelatinous fibres* constitute the chief part of the ganglionic system, and are also present in the cerebro-spinal nerves. They are smaller than the white fibres, measuring from $\frac{1}{4000}$th to $\frac{1}{6000}$th of an inch in diameter, and are apparently homogeneous in their construction.

The *nerve cells*, or *ganglionic corpuscles*, are found in the central organs, and in the peripheral expansion of some of the nerves of special sense. In shape they are spheroidal, caudate or pyriform, radiate or stellate, and of $\frac{1}{400}$th or $\frac{1}{600}$th of an inch in diameter. Each cell is composed of a transparent membrane, filled with

omogeneous, colourless matrix, in which is diffused a number of minute granular bodies, and an internal vesicular nucleus, presenting one or more minute, but very distinct nucleoli.

The *ganglia*, composed of nerve cells and gelatinous fibres, are invested by a thin envelope, continuous with the neurilemma of the nerves, which sends minute processes into the mass, dividing it into lobules. The nerve cords, on entering the ganglia, lose their membranous sheaths, and spread out into bundles, between which the grey matter is interposed.

A NERVE consists of a bundle of tubular fibres, held together by a dense areolar tissue, and enclosed in a membranous sheath, the *neurilemma*. In the larger nerves, a number of these fasciculi are united, and invested by a membrane termed the *sheath*, and have an external covering of cellular tissue, known as the vagina cellulosa or cellular sheath.

During their course, the cerebro-spinal nerves have frequent intercommunication, either by the passage of a branch or in a more intimate and complex manner in what is termed a *plexus*. When the nerves divide into branches, there is never any splitting of the ultimate fibres, nor yet is there ever any coalescing of them—they retain their individuality from their source to their termination.

Nerve fibres may be traced from the surface of the brain and spinal cord into the substance of these organs, the place where it leaves the surface being termed the *apparent*, and the deeper connection the *deep* or *real origin* or *root* of the nerve. In some the root is single, but in others the fibres spring from different parts of the nervous centre; such nerves are said to have two or more roots. These roots may have different functions, as in the spinal nerves, where the superior root is sensory and the inferior motory. Whenever this admixture of functionally distinct fibres is found, a ganglion is placed at or near the apparent root of the nerve.

Nerves terminate in a variety of ways—by loops, as in the voluntary muscles, and in some of the soft pulpy structures,

like the teeth; by terminal plexuses, in membranous surfaces, as the skin; and by swollen extremities. In several of the sentient nerves, there are small, oval masses (the *Pacchionian bodies*), at or near their peripheral terminations. These are plentiful in the nerves in the hand and foot, and in those emanating from the solar plexus. Some nerve fibres have no termination, but form a loop by joining with others in the same bundle, and so return to the axis; while others, as in the inter-retinal fibres of the optic nerve, have no connection with the centre.

Nerves which convey impressions to the centres are termed *sensory*, *centripetal*, or *afferent;* those which transmit stimulus from the centre to the organs of motion, *motor*, *centrifugal*, or *efferent*.

The Meninges of the Spinal Cord.

The cerebro-spinal axis is invested by three distinct membranes, viz., the dura mater externally, the arachnoid in the middle, and the pia mater innermost.

The *dura mater of the cord* is a strong, inelastic membrane, composed of intersecting bands and laminæ of white fibrous tissue. It extends from the foramen magnum, to which it is attached, and where it is continuous with the dura mater of the brain, to the posterior extremity of the canal, where, as a slender cord, it blends with the periosteum in the first bones of the coccyx. Excepting near the posterior part, where they are attached by fibrous slips, the dura mater is separated from the periosteum of the canal by areolar tissue and a plexus of veins, so that it forms a loose sheath round the cord. Its inner surface is smooth, and lined by the arachnoid; opposite each intervertebral foramen it is pierced for the passage of the spinal nerves, which it accompanies, as a tubular sheath, through the hole of conjugation.

The *arachnoid* (so called from its extreme tenuity, resembling a spider's web) is a delicate serous membrane, and, like other serous membranes, a shut sac. Its visceral layer loosely en-

velopes the cord, leaving between them an interval (the *sub-arachnoidean space*, continuous with an opening at the posterior border of the brain), which contains the cerebro-spinal fluid, the use of which is to protect the cord from pressure. The parietal layer is a continuation of the visceral which surrounds the nerves as they leave the cord until they pierce the dura mater, when it is reflected on the inner surface of that membrane. The space between the two layers is the true cavity of the arachnoid.

The *pia mater*, the proper envelope of the cord, is a thin vascular membrane, composed of minute blood-vessels held together by areolar tissue. It is less vascular, but thicker, denser, and more fibrous than the corresponding membrane of the brain, of which, like the others, it is a continuation. It closely invests the whole surface of the cord, sends processes into its longitudinal fissures, and forms a sheath for the spinal nerves. When the cord terminates, the pia mater is prolonged as a slender filament (*filum terminale*) through the centre of the mass of nerves forming the *cauda equina*, and blends with the terminal cord of the dura mater.

The *ligamentum denticulatum* is a narrow fibrous band, which runs between the superior and inferior roots of the nerves from the foramen magnum backwards, so as to form a support for the cord. Its inner border is continuous with the pia mater; the denticulations of its outer edge being attached to the dura mater in the intervals between the roots of the nerves.

The Meninges of the Brain.

The *dura mater* is the thick, white, fibrous membrane which lines the cavity of the cranium, forming the internal periosteum of the bones. It is continuous with the spinal dura mater at the foramen magnum, with the pericranium at the other foramina, and is also prolonged as a sheath for the nerves. In some places the layers separate to form irregular channels, lined by a continuation of the inner coat of the veins (*the sinuses of the*

dura mater) for the passage of the venous blood. On its external surface, the branches of the middle meningeal artery can be traced, and a groove formed by the walls of the longitudinal sinus; and from the inner surface, which is smooth and lined by the arachnoid—hence becoming a true fibro-serous membrane—processes are directed inwards for the support and protection of the different parts of the brain. These membranous processes, regarded as duplicatures of the inner layer of the dura mater, are three in number, viz., the *falx cerebri*, *tentorium cerebelli*, and *falx cerebelli*.

The *falx cerebri* (so named from its likeness to a sickle) is an arched process, which descends in the longitudinal fissure between the hemisphere of the cerebrum. Anteriorly it is attached to the crista galli, and posteriorly to the upper part of the ossific tentorium. Its convex upper border, along which runs the superior longitudinal sinus, is attached to the crest of union of the parietal and frontal bones; its under border is free, and contains the inferior longitudinal sinus.

The *tentorium cerebelli* is a vaulted partition, formed of two lateral plates of dura mater, between the cerebellum and posterior lobes of cerebrum. Each lamina presents an outer convex adherent border attached to the temporal parietal ridge, and enclosing a lateral sinus; an inferior concave, free border, turned outwards and a little forward; a superior extremity attached to the ossific tentorium, but leaving an opening for the passage of the crura cerebri; and an inferior extremity, which reaches to the upper part of the Gasserian ganglion, and contains the superior petrosal sinus.

The *falx cerebelli* is a short double process, proceeding from the ossific tentorium towards the foramen magnum, between the hemisphere of the cerebellum. The occipital sinus is found within its folds.

The *arachnoid membrane*, like that of the cord, is a close sac, the parietal layer of which is firmly adherent to the dura mater, and is reflected over the several processes. The visceral layer

is thin and transparent on the upper surface of the brain, to which it is loosely attached by the sub-arachnoidean cellular tissue: at the base, where the sub-arachnoidean spaces are found, it is thicker and more opaque. These spaces, three in number (anterior, middle, and posterior), contain the cerebro-spinal fluid; they communicate freely with each other, and with the spinal sub-arachnoidean space, and, through it, with the fourth ventricle of the brain. The anterior is situated at the base of the longitudinal fissure, stretching between the middle lobes of the cerebrum, immediately in front of the commissure; the middle, between the pituitary body and the peduncles of the cerebellum; and the posterior, between the medulla oblongata and the posterior part of the cerebellum.

Yellow and white fibres, intimately blended, enter into the composition of the arachnoid, the free surface being lined with scaly epithelium. It surrounds the nerves at their apparent origin, and accompanies them to their exit from the cranial cavity when the layers become continuous.

The *pia mater* (tunica vasculosa) is closely adherent to the entire surface of the brain, dipping into every fissure or depression, and into the sulci between the convolutions, and passing into the interior at four different places, viz., on each side, between the crura cerebri and middle lobes; at the transverse fissure, between the cerebrum and cerebellum, where it forms the velum interpositum; and at the posterior extremity of the fourth ventricle. It is thinner, but much more vascular, than the pia mater of the cord, its vascularity being greatest on the surface of the hemispheres, where it is little more than a ramification of minute vessels, part of which (tomentum cerebri) pass some distance into the grey substance. The locus perforatus and substantia perforata are also pierced by minute arteries derived from this membrane.

The Spinal Cord.

The *medulla spinalis* (Pl. XXVII. fig. 6, *b b*) is a large, white irregularly cylindrical cord, flattened from above downwards which extends from the foramen magnum to the anterior third of the sacral portion of the spinal canal, where it terminates in a slender filament. In order to allow considerable motion of the vertebral column without risk of injury to the cord, it is loosely suspended in the canal; the other contents being the meninges and subarachnoidean fluid, numerous arterial and venous plexuses, and a quantity of loose areolar tissue and fat. In its course, the cord varies in size, being dilated at its origin, where it joins the medulla oblongata, and having a considerable enlargement between the fifth cervical and second dorsal vertebræ, where the large nerves which form the brachial plexus are given off; and again at the third lumbar vertebra, where the lumbar and sacral nerves which constitute the cauda equina take their rise. The roots of the spinal nerves (superior and inferior) have their origin opposite the inter-vertebral foramina (holes of conjugation). The terminal filament or central ligament of the cord, which is constructed of white fibrous tissue externally, and nervous matter internally, passes through the centre of the cauda equina backwards to the second coccygeal bone, where it blends with the sheath.

When denuded of its coverings, the spinal cord is found to be divided into two lateral symetrical *columns* by longitudinal fissures—one on the upper surface least distinct, but deepest, the *superior median fissure*; the other, on the under surface, broader, but shallower, the *inferior median fissure*. Layers of white matter at the termination of these fissures constitute the *superior* and *inferior white commissures*, between which a cross portion of grey matter, the *grey commissure*, extends the whole length of the cord.

Each lateral column is again divided conventionally into three

parts by lateral fissures—a superior (best marked), corresponding with the sensory, and an inferior, corresponding with the motor roots of the spinal nerves.

A transverse section of the cord shows the white matter externally, in the form of two *semi-cylinders*, and the grey matter in the centre of each. The grey substance varies in size in different parts of the cord, but always presents the same general appearance of two *crescentic-shaped* masses, united in the middle by the grey commissure. Each crescent presents two *cornua* or horns—the superior, long and thin, traversing the whole thickness of the cord, and prolonged outwards and upwards to the superior lateral fissure; the inferior, thicker and more irregular, directed over against the inferior roots of the nerves.

The superior columns of the cord are the sensory, and are isolated by the grey matter from the inferior and lateral columns, which are the motory.

The fibres of the cord are not all continuous with those of the encephalon, some being proper to the cord itself; while of those which proceed to the brain, some cross with each other before doing so.

The proportionate size of the brain and spinal cord varies in different animals, according to the position which they occupy in the scale of intelligence—the higher that position the larger and heavier being the brain, and the smaller and lighter the cord relatively. Thus in man, the most intelligent of the animal creation, the brain weighs 50 oz., and the spinal cord about 1½ oz.—a proportionate weight of 1 to 33. In the horse the brain weighs 23 oz., and the spinal cord 10½ oz., or a proportionate weight of 1 to 2·19. In the ass the proportionate weight is as 1 to 2·4; in the cord, as 1 to 2·13. In the sheep as 1 to 2·6; in the pig as 1 to 2·28; in the dog as one to 5·14; in the cat as 1 to 3·75; and in the hare as 1 to 2.*

* Chauveau. "Traité d'Anatomie comparée."

The Encephalon.

The brain is that portion of the cerebro-spinal axis within the cranium. In form it is a slightly flattened and elongated ovoid body, which may be considered to consist of four separate parts — the *medulla oblongata*, the *cerebellum*, the *cerebrum*, and the *pons Varolii*.

The Medulla oblongata (Pl. XXVII. fig. 2, *h*) is the prolongation of the spinal cord, extending to the pons Varolii, from which it is separated by a shallow fissure. This portion of the brain is very large in the domesticated animals, and wherever the spinal cord is largely developed. It is pyramidal in shape, the narrowest part being where it joins the cord. The inferior surface is convex, and rests upon the basilar process, and the superior surface is received between the hemispheres of the cerebellum, where it forms the floor of the fourth ventricle. Two mesian fissures, continuous with the superior and inferior longitudinal fissures of the cord, divide the medulla into symmetrical halves. The superior, deep and narrow, extends into the posterior part of the fourth ventricle, while the inferior terminates in a small depression (*foramen cæcum*) at the posterior part of the pons. On each half of the medulla the following objects can be distinguished, viz., the *inferior pyramids*, the *olivary bodies*, the *restiform bodies*, the *intermediate fasciculi*, and the *superior pyramids*.

The *inferior pyramids* are bundles of white fibres, placed on each side of the inferior mesian fissure, and continuous with portions of both the inferior and lateral columns of the cord. They are constructed of three sets of fibres, the innermost of which decussate with those of the opposite pyramid; the second pass in a direct manner from the cord; and the third, the arciform fibres, form a series of curves which wind round the corpora olivare, to join the restiform bodies.

The *corpora olivare* (Pl. XXVII. fig. 2, *k*) are two elongated,

oval-shaped bodies, on the outside of the inferior pyramids. They are separated from the pons Varolii by a slight depression, and are partly covered by the arciform fibres. A section shows the corpus olivare to be a mass of white matter, in which is a hollow indented capsule of grey matter (*corpus dentatum*). This capsule has an anterior opening, and contains a nucleus of white matter, from which a bundle of fibres spring. These fibres pass through the opening, and, joining the fibres from the inferior pyramids, constitute the *olivary columns*, which become continuous with thalami optici and corpora quadrigemina.

The *corpora restiforme* (Pl. XXVII. fig. 2, *l*) constitute the lateral, and greater part of the superior portion of the medulla, and form the connecting link between the cord and cerebellum. They are composed chiefly of white longitudinal fibres, derived from the inferior and lateral columns of the cord and arciform fibres, which increase in thickness as they pass forwards and upwards to form the posterior peduncles of the crura cerebelli. The lateral walls of the fourth ventricle are formed by the divergence of the restiform bodies.

The *superior pyramids* (Pl. XXVII. fig. 2, *i*) are small bands of fibrous matter between the superior mesian fixture and restiform bodies on each side. They are a continuation of the superior columns of the cord into the peduncles of the cerebrum.

The *intermediate fasciculi* are bundles of fibres, which pass from the lateral columns to the crura cerebri, between the restiform bodies and olivary fasciculi.

The Pons Varolii (XXVII. fig. 2, *g*) is the transverse projection on the base of the brain, between the medulla oblongata and the peduncles of the cerebrum, which is lodged in the anterior depression on the surface of the basilar process of the occiput, and has a groove for the basilar artery along its middle line. It consists of a semicircular band of white fibres, which stretch as a bridge from one side of the encephalon to the other, each extremity being curved upwards, to form the thick cords, which constitute the *middle peduncles* of the cerebellum.

The Cerebellum.

The *cerebellum* (Pl. XXVII. fig. 1, *d*, *d'*, *d''*; fig. 2, *g*; fig. 5, *k k*, *k' k'*, *m m'*) is lodged in the posterior part of the cranial cavity, immediately above the medulla oblongata, and, in the domestic animals, behind the cerebrum, from which it is separated by the tentorium cerebelli. It is globular or elliptical in shape, the transverse diameter being greatest, and consists of a body and three pairs of peduncles, the anterior of which connect it with the corpora quadrigemina, the middle with the pons Varolii, and the posterior with the restiform process of the medulla oblongata. The body of the cerebellum is composed of grey matter externally, and white in the centre. Its surface presents numerous fissures, the two deepest of which run in a circular manner, so as to divide it into a middle and two lateral lobes. The middle lobe projects beyond the lateral, and winds round to the base, forming the vermiform process, to the anterior of which a thin plate of white fibre, the *valve of Vieussens*, is attached, and passes forward to unite the anterior peduncles. This valve covers the aqueduct of Sylvius, and, with the vermiform processes, forms the roof of the fourth ventricle. The posterior vermiform process is not well marked. The smaller fissures, or sulci, divide the cerebellum into numerous lobules, which, when separated, are found to be indented with numerous secondary fissures. Each lobule consists of a periphery of grey matter, and a ramification of white fibres from the centre, so that the whole organ presents an arborescent appearance when cut across. The centre of the cerebellum contains a mass of white matter, within which is a denticulated capsule of grey matter (*corpus dentatum*), similar to that of the olivary bodies, from which white fibres proceed to the crura cerebelli and to the valve of Vieussens, the centre white mass consisting of three bundles of fibres, each of which proceeds to a separate peduncle.

The *fourth ventricle* (Pl. XXVII. fig. 5, *n*) is the lozenge-shaped space between the cerebellum and the medulla, its roof being formed by the vermiform processes and valve of Vieussens, its lateral walls by the superior pyramids and restiform bodies, and its floor by the olivary fasciculi; the testes being its boundary anteriorly, and the restiform bodies posteriorly. A fissure, continuous with the superior median fissure of the cord, passes along the floor of the ventricle into the aqueduct of Sylvius, which is a canal leading into the third ventricle; and on either side of this fissure a few fibres, which join the auditory nerve, unite at an angle somewhat resembling the barb of a pen, and constitute what is known as the *calamus scriptorius*. The lining membrane of this ventricle is continuous with that of the others, through the aqueduct of Sylvius, and with the sub-arachnoidean space.

The Cerebrum.

The *cerebrum* (Pl. XXVII. fig. 1, 2), or brain proper, occupies the anterior portion of the cranial cavity. It is ovoid in shape, with an irregularly flattened base, and consists of lateral halves or hemispheres, separated by the longitudinal fissure, in which the falx cerebri is lodged. Anteriorly, from the optic commissures, this fissure reaches quite to the base, but, on the superior surface, it is interrupted by a broad lamina of white fibres, the *corpus callosum*, or great commissure of the hemispheres; and, at the upper part of its posterior extremity, it is crossed by a species of bridge, under which the venæ Galeni pass to the interior. Deep, irregular sulci map out the surface of the hemispheres into numerous convolutions, the number of which, and the depth of the sulci, indicate the range of intelligence possessed by the animal, as the grey matter, which is believed to be the seat of the intellectual faculties, is found on the surface of the convolutions and on the sides and bottom of the sulci, so that the deeper and more numerous these are the greater is the amount of grey matter in the brain (Pl. XXVII. fig. 1, *a*, *a'*, *a''*, *a'''*).

In the domestic animals, each hemisphere is divided into an anterior and a mastoid lobe, the posterior lobe which is found in man being wanting. The *anterior lobe*, which forms the bulk of the organ, is separated from the mastoid lobe by the *fissure of Sylvius*, not very distinct in the lower animals, at the entrance of which, connecting the lobes, is a bundle of fibres—the *fasciculi unciformis*. This fissure—which is on a level with the optic tracts, and contains the middle cerebral artery—divides into two branches, one going upwards and forwards, the other downwards and inwards. Between the bifurcations, a prominent cluster of convolutions, the *island of Reil*, converge to the fasciculi unciformis. These convolutions, which, from their being covered in the fissure, are also called the *covered convolutions*, are most constant in all animals, and are the first recognised in the lowest scales of brains.

At the base of the brain are the *crura*, or *pedunchs of the cerebrum* (Pl. XXVII. fig. 2, *a a*), two large bundles which, commencing in front of the pons Varolii, proceed forward in a divergent manner, entering the under part of each hemisphere, and terminating in the optic thalami. These crura consist of two layers of white matter, with a mass of grey matter (*locus niger*) interposed. Both layers are longitudinal, the superficial being continuous with the inferior pyramids, and the deep with the lateral and superior columns of the medulla and olivary fasciculi. They are covered by the corpora quadrigemina and optic thalami, and are crossed in front by the *optic tracts*, or apparent origin of the optic nerves. These tracts proceed forward and inward, and decussate in the median line, the junction being termed the optic commissure. The lozenge-shaped space between the crura and the optic tracts is the *inter-pedunculur space*, in which we find the *pituitary body*, the *tuber cinereum*, the *infundibulum*, the *corpus albicans*, the *locus perforatus posticus*, and the *pons Tarini* (Pl. XXVII. fig. 2, *b*, *c*, *d*, *e*, *f*).

The *pituitary gland* (Pl. XXVII. fig. 2, *d*), a small, round,

Plate XXVII BRAIN AND EAR

G. Waterston & Sons Edin. Photo Litho.

PLATE XXVII.

BRAIN AND EAR.

Fig. 1.—Cerebrum and Cerebellum, seen from the front.

(*a.*) Left hemisphere of cerebrum. *a'*. Right hemisphere. *a''*. Its inferior lobe. *a'''*. Its superior lobe. *b*. Corpus callosum. *c*. Spot where the large cerebral veins pass out. *d d' d''*. Cerebellum. *d*. Vermiform process. *d'*. Its left lobe. *d''*. Its right lobe.

Fig. 2.—Base of the Cerebrum with the Pons Varolii and Medulla Oblongata.

a a. Crura cerebri. *b*. Corpus mammillare. *c*. Infundibulum. *d*. Pituitary body. *e*. Mammillary processes. *f*. Tuber cinereum. *g*. Pons Varolii. *g' g'*. Middle crura of cerebellum. *h*. Medulla oblongata. *i*. Anterior pyramids. *k*. Olivary bodies. *l*. Restiform bodies.

Fig. 3.—Base of the Brain, with Origins of the twelve Cranial Nerves.

a. 1st pair, Olfactory nerve. *b*. 2d pair, Optic nerve. *c*. 3d pair, Oculo-motor nerve. *d*. 4th pair, Pathetic nerve. *e*. 5th pair, Trigeminal nerve. *f*. 6th pair, Abducent nerve. *g*. 7th pair, Facial nerve. *h*. 8th pair, Auditory nerve. *i*. 9th pair, Glosso-pharyngeal nerve. *k*. 10th pair, Pneumogastric nerve. *l*. 11th pair, Spinal accessary nerve. *m*. 12th pair, Hypo-glossal nerve.

Fig. 4.—Cerebrum with the Lateral Ventricles opened, seen from above.

1 1. Grey substance. 2 2. White substance. *a*. Septum lucidum. *b*. Corpus callosum. *c c*. Superior crura of fornix. *d*. Corpus fimbriatum of right crus. *e*. Choroid plexus of left lateral ventricle. *f f*. Corpora striata. *g*. Inferior horn. *h*. Superior horn.

Fig. 5.—Lateral Ventricle of Cerebrum after removal of the Fornix, along with Cerebellum which is cut vertically, seen from above.

a a. Corpora striata. *b*. Portion of fornix, the greater part having been removed. *c c*. Striæ terminales. *d d*. Optic thalami. *e*. Pineal gland thrown back. *f*. Inferior cerebral opening. *g*. Superior cerebral opening. *h h*. Inferior pair of corpora quadrigemina. *i i*. Superior pair. *k k*. Inferior peduncles of cerebellum. *k' k'*. Its superior peduncles. *l*. Medullary velum. *m*. Left half of cerebellum. *m'*. Its right half with arbor vitæ. *n*. Fourth ventricle. *o*. Fossa triangularis.

Fig. 6.—Cervical portion of Spinal Cord, exposed by opening the Vertebral Canal from above.

a. Brain. *b b*. Spinal cord. *c c*. Cervical nerves.

EAR.

Fig. 7.—The Outer Wall of the Tympanum.

a. External auditory meatus. *b*. Membrana tympani. *c*. The malleus. *d*. Osseous cells and laminæ on the outer wall. *e e*. Groove for tympanic membrane. *f*. Opening of Eustachian tube.

Fig. 8.—The Inner Wall of the Tympanum.

a. Aqueductus Fallopii. *b*. The promontory. *c*. Fenestra ovalis. *d*. Fenestra rotunda.

Fig. 9.—A portion of the Labyrinth, with part of the Cochlea.

a. Modiolus. *b*. Lamina spiralis.

reddish-grey, vascular, two-lobed body, lodged in the sella turcica, where it is held by a fold of dura mater, is similar in structure to the ductless glands. In the fœtus, it contains a central cavity, which communicates, through the infundibulum, with the third ventricle.

The *tuber cinereum* (Pl. XXVII. fig. 2, *f*), a spherical mass of grey matter forming part of the floor of the third ventricle, is situated immediately behind the optic tracts. From its under surface is prolonged the *infundibulum* (Pl. XXVII. fig. 2, *c*), a conical process of reddish colour, to the summit of which the pituitary body is attached. The funnel-shaped cavity in this process passes out through the tuber cinereum into the third ventricle.

The *corpus albicans* is a round object, white externally and grey internally, behind the tuber cinereum. It is connected with the crura or bulb of the fornix.

The remaining space between the corpus albicans and the crura of the cerebrum, forming part of the floor of the third ventricle, is the *locus perforatus posticus*, the numerous minute openings in which allow of the passage of blood-vessels to the optic thalami. The white fibres which cross this space from one cross to the other form the *pons Tarini*.

On each side, rather to the front of the optic tracts, and near the commencement of the Sylvian fissure, is a triangular space of grey matter, the *locus perforatus anticus*. These spaces, like the posterior perforated space, are pierced for the passage of blood-vessels to the corpora striata, which lie immediately above.

The *olfactory bulbs* (Pl. XXVII. fig. 3, *a*), the apparent origin of the first pair of cranial nerves, arise from the anterior perforated spaces. They consist of a layer of white surrounding an inner tube of grey matter, the interior being hollow, and communicating with the lateral ventricles.

On removing the upper part of the hemispheres, by a section midway between the corpus callosum and the superior surface of the brain, a central mass of white matter, surrounded by a

convoluted border of grey, is exposed. The white portion, known as the *centrum ovale minus*, is studded with numerous red spots, *puncta vasculosa*, caused by the escape of blood from the vessels which have been divided. A second section, made immediately above the corpus callosum, exposes the greatest amount of white matter, *centrum ovale majus*, above which, on the inner surface of the hemisphere, is the *gyrus fornicatus*, or convolution of the corpus callosum. The space between these convulutions and the corpus is known as the *ventricle of the corpus callosum.*

The *corpus callosum* or *great commissure* (*trabs cerebri*) (Pl. XXVII. fig. 1, *a;* fig. 4, *b*) is the white quadrilateral, slightly arched body which unites the hemispheres. Its lateral borders are hidden by the gyri fornicati and substance of the hemispheres, in which they become lost; while the middle of its superior surface, seen at the bottom of the longitudinal fissure, is free, and covered with pia mater. Along its middle line between two delicate cords of white matter (*striæ longitudinales*, runs a line or seam, the *raphé*, on either side of which may be seen the transverse markings which indicate the direction of the fibres of which the corpus callosum is composed. Its inferior surface is connected posteriorly with the fornix, the remainder being divided by the septum lucidum into two parts, which form the roofs of the lateral ventricles. Its anterior extremity is reflected downwards, the bend being the knee (*genu*), and the tapering reflection the rostrum or beak. From the sides of the *rostrum* a delicate grey membrane (*lamina cinerea*) extends to the tuber cinereum, and from the point divergent white bands, the *crura of the corpus*, extend to the anterior perforated spaces. The posterior extremity of the corpus callosum is thick, and forms a free rounded border which is in connection with the middle of the fornix.

When the corpus callosum is cut through, two large cavities in the substance of the hemispheres (the *lateral ventricles*) (Pl. XXVII. fig. 4) are exposed. These cavities are lined with a

elicate membrane, covered with ciliated epithelium, which se-retes a serous liquid similar to the cerebral spinal fluid. They re each possessed of a roof and two smaller cavities or cornua. he *roof* of the body of the ventricle is formed by the corpus allosum, and the *floor* by the corpus striatum in front, and the iternal part of the hippocampus behind; while the *septum icidum* stretches as a partition between the two ventricles. unning obliquely from behind forwards, and from without in-ards, between the corpus striatum and the hippocampus, is a rrow in which a red vascular fringe, the *choroid plexus*, is dged; and between the corpus striatum and the thalamus op-cus is a narrow band of white matter, *tænia semicircularis*. he *anterior cornu* stretches from the body of the ventricle into ne anterior lobe of the cerebrum, and is continued as a straight nal to the cavity of the olfactory lobe. The *descending cornu* asses from the recurved portion of the body of the ventricle ackwards, outwards, and downwards, and then forwards and nwards, winding round the optic thalamus and crus cerebri, to erminate in a cul-de-sac in the middle lobe near the fissure of ylvius. As there are no posterior lobes to the cerebrum of nimals, so the posterior cornua of the lateral ventricles, which re found in man, are also wanting.

The *septum lucidum* (Pl. XXVII. fig. 4, *a*) is the thin, semi-ransparent substance which stretches between the corpus cal-osum above and the fornix below, and forms the partition etween the lateral ventricles. It is triangular in shape, and is omposed of two laminæ, between which a perfectly isolated avity, lined with epithelium and containing a serous fluid, is ound. This cavity is the *fifth ventricle* or ventricle of the eptum lucidum.

The *fornix* (Pl. XXVII. fig. 4, *c c;* fig. 5, *b*) is the longitu-inal band which extends as an arch along the lower border of he septum lucidum, and is attached to the posterior extremity f the corpus callosum. It consists of a body and four pillars. The body is triangular in form, broad and flat behind, and

narrow in front, where it dips down to leave the corpus callosum; its edges reach the choroid plexuses, and its inferior surface rests on the velum interpositum. The anterior pillars descend in front of the anterior commissure, and, becoming inflected downwards and backwards by the sides of the third ventricle, pass to the corpus albicans, of which they form the external fibres, and then turning upwards, become lost in the optic thalami.

Behind the anterior pillars of the optic thalami on each side, small openings pass downwards and backwards, and, uniting in the middle line, lead into the third ventricle. This is the *anterior common opening* or *foramen of Monro*, which forms a communication between the two lateral and the third ventricles.

The posterior pillars of the fornix pass downwards to the descending cornua of the lateral ventricles, and then become continuous with the hippocampi. The thin prolongation behind the choroid plexus is the *corpus fimbriatum* (*tænia hippocampi*) (Pl. XXVII. fig. 4, *d*); and the transverse white fibres which pass, like the strings of a harp, between the pillars, form the *lyra*.

The *hippocampus* (*cornu ammonis*) is the large eminence, constituted of white matter externally and grey internally, which occupies the posterior part of the floor of the lateral ventricle. The hippocampi are in connection with the body of the fornix, and are separated from the optic thalami by the choroid plexuses. Posteriorly they converge and enter the descending cornua of the ventricles occupying the cul-de-sac. Towards their terminations they become enlarged, and present a number of rounded elevations, with indented edges somewhat resembling the foot of an animal; hence they are called *pes hippocampi*. The external white matter of the hippocampi is continuous, through the corpora fimbriata, with the fornix and corpus callosum.

The *corpus striatum* (Pl. XXVII. fig. 4, *f f*) is the pear-shaped prominence which occupies the anterior region of the floor of the lateral ventricle. Its broad anterior extremity—

intra-ventricular portion—stretches into the anterior cornu, and its narrow posterior extremity—extra-ventricular portion—passes into the descending cornu, and is embedded in the substance of the hemisphere. The furrow along its oblique inner side, which separates it from the hippocampus and the optic thalamus, contains the choroid plexus and the tænia semicircularis. The corpora striata are grey externally, and are composed of grey matter, with numerous white fibres traversing it, which give it a striated appearance when cut across. They are the superior ganglia of the cerebrum.

The *tænia semicircularis* is a narrow, white, semi-transparent band, which separates the corpus striatum from the optic thalamus. In front, it reaches the anterior pillars of the fornix, becoming lost near the foramen of Monro; and, posteriorly, it disappears in the descending cornu. A large vein beneath this band (*vena corporis striati*) receives the blood from the corpus striatum, and empties itself into the vena Galeni.

The *velum interpositum* is a fold of pia mater, which passes into the interior of the brain in the transverse fissure between the corpora quadrigemina and the posterior part of the corpus callosum, and on which the fornix rests, being interposed between that body and the third ventricle. It is triangular in shape, its apex corresponding with the anterior common opening, and consists of a layer derived from the inferior surface of the cerebrum, and another from the superior surface of the cerebellum. A process from it embraces the pineal gland; and its sides, projecting into the lateral ventricles, form the free border of the choroid plexuses.

The *choroid plexus* (Pl. XXVII. fig. 4, *e*) is the vascular fringe in the lateral ventricle, which stretches from the foramen of Monro and the descending cornu in the furrow between the hippocampus and the corpus striatum. It is a highly vascular, villus membrane, containing looped plexuses of blood-vessels, surrounded by a thick layer of epithelium.

The *thalami optici* (Pl. XXVII. fig. 5, *d d*) (bed of the optic

nerves) are the two large oval bodies, seen when the fornix and hippocampi are removed, embracing the anterior portion of the crura cerebri, and in front of the corpora quadrigemina. They form the inferior ganglia of the brain, and, like the corpora striata, consist of grey matter, with intersecting white fibres, derived from the crura cerebri, hemispheres, and cerebellum. The anterior portions of the optic thalami approximate most closely. Their upper surfaces are convex and free, and their posterior surfaces project into the descending cornua of the lateral ventricles. Between the thalami and the crura cerebri are rounded grey prominences—*corpora geniculata*—two on each side, the innermost of which connect the thalami with the nates, and the outermost, which are the largest, with the testes.

The *third ventricle* is the space between the optic thalami, which form its lateral walls, seen on removing the fornix and velum interpositum, which form its roof; its floor being formed of the tuber cinereum, corpus albicans, locus perforatus posticus, and lamina cinerea. Three *commissures*—anterior, middle, and posterior—cross this ventricle. The *anterior* is a bundle of white fibres, which forms the anterior boundary of the ventricle, and unites the corpora striata in front of the pillars of the fornix; the *middle*, constructed of grey matter, is the *grey* or *soft commissure*, which stretches between the thalami; the *posterior*, which is white, and also unites the thalami, crosses the posterior part of the ventricle in front of the pineal gland. There are three openings into this ventricle—1*st*, Between the anterior and middle commissure, in the centre of the floor, a deep pit or cavity, the *iter ad infundibulum*, leads to the infundibulum; 2*d*, Between the grey commissure and summit of the fornix, the foramen of Monro leads into the lateral ventricle; and 3*d*, The *aqueduct of Sylvius*, or *iter e tertio ad quartum ventriculum*, which leads into the fourth ventricle. Through these openings, the lining membrane of the third ventricle is continuous with that of the others.

The *pineal gland* (Pl. XXVII. fig. 5, *e*) is a small reddish-

brown tubercle, placed behind the third ventricle in a groove between the corpora quadrigemina, where it is kept in its place by a layer of the velum interpositum, to which it is attached. In shape it is somewhat conical, having a broad base and a free apex. The base, which is turned forwards, has bands of white matter, its peduncles passing from each angle to the optic thalami, which they join. The pineal gland is very vascular, and is constructed of areolar tissue and cells, which contain, besides a viscid fluid, a quantity of sand-like matter (*acervulus cerebri*), which give a gritty feel to the body. Though these grains often accumulate largely in old animals, they are not regarded as the products of disease. The use of this gland is not known; the ancients regarded it as the seat of the soul, and the chief source of nervous power.

The *corpora quadrigemina* or *optic lobes* (Pl. XXVII. fig. 5, *h*, *h*) are the four rounded eminences situated immediately behind the optic thalami, surmounting the posterior part of the crura cerebri, and forming part of the roof of the aqueduct of Sylvius. They are separated by a crucial depression, and are placed one before the other in the mesian line. In the Horse and Ox the anterior pair, the *nates*, which are grey in colour, are larger than the posterior pair, the *testes*, which are rounded and nearer together; in the Dog and carnivora, however, the testes are the largest. These bodies have connection with the olivary fasciculus, and, by the processus e cerebello ad testes, are joined to the cerebellum. The white processes (*brachia*), given off from each side, pass to the optic thalami and to the commencement of the optic tracts. The corpora quadrigemina are ganglionic in structure, with interlacing white fibres, the testes, in addition, having an external white tunic.

THE ENCEPHALIC CIRCULATION.

The circulation of the blood in the brain differs in a remark able degree from that of any other region—one great peculiarit being that the general arrangement of vessels in the substanc of the organ is almost entirely capillary. The larger arteries a ramify in the dura mater and in the sulci between the convolu tions, and the smaller branches, from which the extremely fin penetrating twigs are given off, in the pia mater. The veins also, are extremely small, and do not unite until they emerg from the nervous substance, when their superficial branches dispersed over the surface of the brain, enters large sinuses o angular channels within the dura mater. These sinuses ar remarkable for their rigidity, which enables them to preserve a almost uniform diameter. Another remarkable feature is th great freedom of anastomosis which exists among the arteries— in the larger trunks, as well as in the smaller branches.

I. The Arterial Circulation.

Four large arteries, two internal carotid and two cerebro spinal branches of the occipital artery, convey the blood to th encephalon. An examination of the tortuous course of these arteries shows how beautifully Nature has provided against injury to the delicate brain-structure by the blood striking with too great a force against its base.

The Cerebro-spinal arteries enter the spinal canal through the anterior intervertebral foramina in the wing of the atlas, and wind round the cord to its inferior surface, where they each divide into two branches—one of which, the *anterior* or *cerebral branch*, passes forwards and joins its fellow near the middle of the medulla oblongata, to form the basilar artery. The *posterior branches* pass backwards, and also coalesce to form the *middle spinal artery*, which runs along the longitudinal fissure of the cord.

The Basilar artery (Pl. XXI. fig. 2, *e*, and description) is

continued forwards in the longitudinal furrow on the inferior surface of the pons Varolii, near the anterior border of which it divides into two branches—the posterior cerebrals. In its course, the basilar artery gives off—1*st*, Several small branches, which penetrate the surface of the medulla oblongata and pons Varolii; 2*d*, The *posterior cerebellar*, right and left, which, like the terminal branches, are given off at right angles behind the posterior border of the pons. They are carried outwards, ascending over the pons, and then, inflected backwards, are distributed over the lateral and posterior parts of the cerebellum. 3*d*, The *anterior cerebellar arteries*, two or three on each side, the principal being given off just in front of the pons, on the outer side of which it ascends in an outward and a little backward direction, to be distributed to the anterior surface of the cerebellum.

The terminal branches, *posterior cerebral arteries*, are the largest, and form the posterior border of that peculiar arterial circle at the base of the brain known as the CIRCLE OF WILLIS. They are joined by the posterior communicating branches of the internal carotid, and pass outwards round the crura cerebri towards the transverse fissure, anastomosing with the middle cerebrals, and are finally distributed over the posterior part of the cerebrum. In their course, these arteries give off branches which penetrate the interpeduncular space, and a branch distributed over the velum interpositum.

The INTERNAL CAROTID (Pl. XXI. fig. 2) is one of the three terminal branches of the common carotid. It enters the cranial cavity through the foramen lacerum basis cranii, and through the cavernous sinus, where it forms a double curve. The first of these curves, which occupies the carotid fossa in the sphenoid bone, has its convexity looking forwards, and the second has its convexity looking backwards, so that the two curves resemble the letter S. After the second curve, the artery pierces the dura mater, and, at the fissure of Sylvius, divides into anterior and middle cerebral and posterior communicating arteries.

The POSTERIOR COMMUNICATING ARTERY, which forms the

lateral boundary of the circle of Willis, passes backwards by the side of the interpeduncular space, and inosculates with the posterior cerebral branch of the basilar artery.

The Anterior cerebral branches are carried forwards to the longitudinal fissure, where they converge and unite; and, passing through the fissure, after a short course, again divide into two branches, which subdivide to supply the corpus callosum, the third ventricle, and the under surface of the cerebrum. Sometimes, instead of uniting into a single trunk, the anterior cerebral arteries are joined by a transverse branch, termed the *anterior communicating artery*. These vessels and their communicating branch form the anterior lateral and anterior boundaries of the circle of Willis.

The Middle cerebral artery passes directly outwards to the fissure of Sylvius, where it divides into numerous branches which ramify over the lateral and inferior surfaces of the cerebrum, and anastomose with branches of the anterior and posterior cerebrals. Just before this artery divides, it gives off a small branch, the *anterior choroid*, which enters the descending cornu of the lateral ventricles and supplies the choroid plexus.

II. The Venous Circulation.

The encephalic venous circulation consists of veins and vascular triangular channels of various sizes, found within the dura mater. These are the sinuses, which are lined by a continuation of the inner tunic of the veins, and which, like the other veins of the brain, are destitute of valves, but present numerous bands or cords stretched across their interior so as to prevent distention.

The veins are divided into superficial and deep.

The Superficial veins are distributed over the whole surface, mostly in the grooves between the convolutions; they receive small capillary branches from the substance, and terminate—those from the superior surface in the longitudinal sinus, and those on the inferior and lateral surfaces in the lateral and other sinuses.

The Cerebellar veins are, like the cerebral, scattered over the whole surface of the cerebellum, and mostly terminate in the petrosal sinus.

The Deep or Ventricular veins arise by very minute branches, which form intimate plexuses in the ventricles, the chief being the veins of the corpora striata and those of the choroid plexuses, which unite to form the venæ Galeni, which leave the interior through foramina at the posterior part of the longitudinal fissure, and terminate in the longitudinal sinus.

III. The Sinuses.

The principal sinuses of the dura mater are the longitudinal, two lateral, two petrosal, two cavernous, the occipital, and the transverse.

The Longitudinal sinus, situated in the attached border of the falx cerebri, commences at the crista galli, and terminates at the ossific tentorium, in the large reservoir (torcular Herophili) or confluence of the sinuses, which bifurcate and join the lateral sinuses.

The Lateral sinuses, situated within the folds of the tentorium cerebelli, receive the blood from the longitudinal sinus, and terminate in veins which empty themselves partly into the temporal veins, through the parieto-temporal conduits, and partly into the jugular vein.

The Occipital sinuses, which are very irregular, are situated in the falx cerebelli, and terminate in the lateral sinuses.

The Petrosal sinuses, situated at the sides of the petrous temporal bone, form a communication between the lateral and cavernous sinuses.

The Cavernous sinuses, which resemble the corpus cavernosum of the penis in structure, are situated under the dura mater at the sides of the sphenoid bone. They stretch back as far as the condyloid foramen, and are united by an arched branch, sometimes termed the *transverse sinus*, which winds round the back of the pituitary gland. The cavernous sinuses are con-

tinuous with the veins of the spinal cord, and terminate in the cerebro-spinal branches of the occipital veins.

The Cranial Nerves.

The nerves which are transmitted through the foramina at the base of the cranium are denominated cranial nerves. They leave in pairs, regularly disposed, one on the right side and the other on the left, and are named numerically, according to the order in which they leave the cavity, and by names derived from the parts to which they are distributed and the functions they perform.

The cranial nerves are differently enumerated by different authorities, some classifying them into nine, and others into twelve pairs. The first classification is that of Willis, who makes the number correspond with the number of openings through which they find their exit; and the last that of Soemmerring, who counts the number of the apparent roots of the nerves. They are also arranged in three divisions, according to their functions, viz., into 1*st*, Nerves of special sensation; 2*d*, Nerves of motion; and 3*d*, Mixed or compound nerves—that is, nerves which contain both motory and sensory fibres. Soemmerring's classification is the one adopted in this work.

Designation of the Nerves.

According to Willis's Classification.	According to Sœmmerring's Classification.	According to their Distribution or Function.
1	1	Olfactory.
2	2	Optic.
3	3	Motores oculorum.
4	4	Pathetici (trochleares).
5	5	Trifacial (trigemini).
6	6	Abducentes.
7	7	Facial (portio dura).
	8	Auditory (portio mollis).
8	9	Glosso-pharyngeal.
	10	Pneumo-gastric (vagus, par vagum).
	11	Spinal accessory.
9	12	Hypo-glossal (lingual).

CRANIAL NERVES.

PLATE XXVIII.

CRANIAL NERVES.

Fig. 1.—The Ninth, Tenth, Eleventh and Twelfth Cranial Nerves, First Cervical, and Cranial portion of the Great Sypathetic Nerves, exposed on the left side of the head.

(The Left Ramus of the Lower Jaw and the Parotid Gland are removed).

a. Carotid. *b.* Glosso-pharyngeal nerve. *b'.* Pharyngeal branch. *b''.* Lingual branch. *c c.* Pneumogastric nerve. *c'.* The pharyngeal branch. *c''.* Superior laryngeal branch. *d.* Spinal accessory nerve. *d'.* Its lower branch. *d''.* Its upper branch. *e.* Hypo-glossal nerve. *f.* Great sympathetic nerve. *f'.* Its spindle-shaped ganglion. *f''.* Place of union of great sympathetic with tenth cranial nerve. *g.* First cervical nerve.

Fig. 2.—The Nerves on the Right Side of the Head laid bare.

(The Right Ramus of the Lower Jaw has been removed, and the Cheek laid open.)

a. Second division of 5th cranial nerve. *b.* Inferior palpebral nerve. *a'.* Spleno-palatine nerve. *c.* Superior nasal nerve. *d.* Great palatine nerve. *e.* Superior dental nerve. *f.* Small palatine nerve. *g.* Infra-orbital nerve. *g'.* Superficial nasal nerve. *g''.* Inferior nasal nerve. *g'''.* Superior labial nerve. *h.* Third division of 5th cranial nerve. *i.* Masseteric nerve. *k.* Anterior temporal nerves. *l.* Pterygoid nerve. *m.* Buccinator nerve. *n.* Superficial temporal nerve. *o.* Posterior dental nerve. *o'.* Its mental branch. *p.* Lingual nerve. *p'.* Its superficial branch. *p''.* Its deep branch.

Fig. 3.—The Second and Third Divisions of the 5th Cranial, along with the 7th Cranial Nerve, exposed on the left side of the head.

a. Continuation of infra-orbital nerve. *b.* Masseteric nerve. *c.* Superior branch of superficial temporal nerve. *d.* Its inferior branch. *e.* Anterior auricular nerve. *f.* Internal auricular nerve. *g.* Posterior auricular nerve. *h h.* Posterior temporal nerve. *i.* Nervus subcutaneus colli. *k.* Stylo-hyoid nerve. *l l l.* Branches to parotid gland. *m.* Facial nerve. *n.* Anterior buccal nerve. *n'.* Its anterior branch. *n''.* Its posterior branch. *o.* Posterior buccal nerve.

First Pair.—The Olfactory (Pl. XXVII. fig. 3, *a*), or nerve f the Special sense of smell, arises by three roots—an *inner*, *hort* root of white fibres, derived from the inner and posterior art of the anterior lobe; an *outer*, *long root*, also white, which rosses the Sylvian fissure into the mastoid lobe, where it is ontinuous with fibres of the optic thalamus; and a *middle* or *rey root*, which also contains white fibres from the corpus triatum, from a papilla of grey matter (caruncula mamillaris) n the anterior lobe. The union of these roots forms the olfac- ory lobe, which, as it passes forward, swells into an oblong nass, the olfactory bulb, which rests on the cribriform process f the ethmoid bone. From the under part of the bulb spring he olfactory nerve filaments, which are distributed, in the form f a delicate net-work, over the surface of the mucuous mem- brane of the nares. These filaments are divisible into three groups—an *outer*, sent to the middle turbinated bones and sur- face of ethmoid; a *middle*, which supplies the mucous membrane f the roof of the nose; and an *inner*, spread over the septum narium.

Second Pair.—The Optic (Pl. XXVII. fig. 3, *b*), or nerve of the Special sense of sight, is a large nerve, which has its deep rigin in the corpora geniculata, optic thalamus, and corpora quadrigemina; the fibres from these three different sources uniting o form the optic tract, which winds round the crus cerebri to oin its fellow, and form the optic commissure (chiasma) or superficial origin of the optic nerves. After leaving the com- missure, the nerves become rounded, and diverge to pass through he optic foramina, where they receive a covering of dura mater, which immediately splits into two portions, one of which forms he periosteum of the orbit, and the other a sheath for the nerve. After piercing the sclerotic and choroid coats of the eyeballs, the nerve expands into the nervous retina. A little ehind the eyeball, the nerve is pierced to its centre for the passage of a small artery (arteria centralis retina), which supplies he retina.

In the optic commissure, a peculiar decussation of nerve fibres takes place,—while the outer fibres of the optic tract continue their course direct to the eye of the same side, the innermost pass to that of the opposite side; at the same time, some of the fibres cross from one tract to the other, and have no connection with the eyes; while others proceed from eye to eye, without having communication with the brain.

Third Pair.—Motores oculorum (Pl. XXVII. fig. 3, *c*), the motor oculi, a nerve of motion, has its apparent origin on the inner side of the crus cerebi, close to the pons Varolii, its course lying between the posterior cerebral and anterior cerebellar arteries; its deep origin may be traced to the locus niger, pons Varolii, corpora quadrigemina, and valve of Vieussens. It makes its exit from the cranial cavity through the foramen lacerum orbital into the optic fossa, where it divides into three branches. The *superior branch* supplies the superior (levator) and posterior (retractor) recti, and levator palpebræ muscles; the *middle* goes to the retractor muscle; and the *inferior* sends branches to the internal and inferior recti and inferior oblique muscles, and also to the lenticular ganglion.

Fourth Pair.—The Pathetici (Pl. XXVII. fig. 3, *d*), a nerve of motion, and the smallest of the cranial nerves, has its superficial origin by the side of the pons Varolii, but its deep fibres may be traced to the valve of Vieussens, floor of fourth ventricle, and corpora quadrigemina. Winding round the crus cerebri, this nerve passes through the outer wall of the cavernous sinus, leaves the cranium through the foramen pathetici, and is distributed to the superior oblique muscle of the eye. In the cranial cavity, it gives off a recurrent branch, which passes backwards to the walls of the lateral sinus, and also a branch to the ophthalmic; it receives a few filaments from the sympathetic.

Fifth Pair.—The Trifacial (Pl. XXVII. fig. 3, *e*) (trigeminus) is the largest of the cranial nerves, and, being a nerve of common sensation, of special sense, and of motion, belongs to the class of mixed nerves. It is analogous to a spinal nerve in

having its origin by two roots, posterior and anterior, and in having a ganglion on the posterior root. It arises on the side of the pons Varolii; and the sensory root, which is largest, may be traced to the restiform bodies and lateral columns of the cord, the anterior or motory root having its deep origin in the corpora pyramidalia. The nerve passes forward through an opening in the dura mater, at the apex of the petrous temporal bone, where the posterior root spreads out into a large ganglion, the *Gasserian*, the anterior root passing beneath without any connection. The Gasserian ganglion divides into the ophthalmic, superior maxillary, and inferior maxillary branches.

The OPHTHALMIC NERVE, the smallest of the three divisions of the Gasserian ganglion, passes forwards in the outer wall of the cavernous sinus, in company with the third and sixth nerves, and divides into three branches (frontal, lachrymal, and nasal), which enter the optic fossa through the orbital hiatus.

The *frontal* or *supra orbital nerve*, is a large, flat branch, placed on the internal wall of the optic fossa; it ascends parallel with the superior oblique muscle, passes through the supra-orbital foramen, and, after giving a branch to the upper eyelid, divides into two branches, one distributed to the skin of the forehead, the other to the muscles above the eye. This nerve anastomoses, and forms a plexus with the anterior auricular nerve.

The *lachrymal nerve*, the smallest of the three, passes straight up to the lachrymal gland, which it supplies, together with the conjunctiva, and the muscles and tegument of the anterior part of the eye.

The *nasal* or *palpebro-nasal nerve*, the largest branch of the ophthalmic, curves inwards between the retractor and levator oculi, and re-enters the cranial cavity through the orbital foramen; it then passes through the cribriform plates of the ethmoid, and divides into two branches, which ramify in the pituitary membrane on the walls of the nasal fossæ. Before entering the orbital foramen, it gives off a long branch to the membrane nic-

tituns and lower eyelid, another to the lachrymal sac, and a sensory root to the ophthalmic ganglion.

The Superior maxillary nerve (Pl. XXVIII. figs. 2 and 3, and description) leaves the cranium through the foramen rotundum, and gains the orbit in company with the internal maxillary artery, crosses the lower part of the orbit, enters the maxillary hiatus, passes through the infra-orbital canal and emerges on the face at the infra-orbital foramen, where it divides into numerous facial branches. The lateral branches of the superior maxillary are—

1. The *orbital branch*, which leaves the trunk in the orbit, and is distributed to the eyelids and integument.

2. The *anterior palatine* or *palato-maxillary*, which enters the palatine foramen with the palato-labial artery, and accompanies the palatine artery, giving branches to the palate and gums.

3. The *posterior palatine* or *staphyline*, which accompanies the staphyline artery, and is distributed to the soft palate.

4. The *spheno-palatine* or *nasal*, which passes through the spheno-palatine foramen, is distributed to the mucous membrane of the nose, and sends a branch to the spheno-palatine ganglion (*Meckel's*).

5. The *dental*, which is given off in the infra-orbital canal, and divides into posterior and anterior—the former supplying the molar teeth, and sending a branch to the maxillary sinus, and the latter furnishing nerves to the incisor and canine teeth.

The terminal branches of the superior maxillary are distributed to the nose, false nostril, upper lip, and muscles and tegument of the face, and form intimate plexuses with branches of the seventh pair or motor nerves.

The Inferior maxillary nerve (Pl. XXVIII. figs. 2 and 3, and description), the largest of the three divisions of the Gasserian ganglion, unites with the anterior root of the nerve immediately after it passes through the oval opening in the dura mater, so that it is both sensory and motory. The course of this nerve

s through the foramen lacerum basis cranii, and between the terygoid muscles to the posterior maxillary foramen, which it nters, and, passing through the lower jaw, makes its exit at the nterior maxillary foramen, and terminates in the mental nerves. n its course it gives off masseter, buccal, internal pterygoidean, ubzygomatic, lingual, mylo-hyoidean, and dental branches.

The *masseter branch* is detached from the trunk at the base of he cranium, turns round the temporo-maxillary articulation, and s distributed to the masseter muscle. It gives off branches to he temporal muscle.

The *buccal* is directed forwards, traverses the external ptery-oid muscle, and is distributed to the buccinator muscle and to he mucous membrane of the cheek, descending to the commis-ures of the lips and the labial glands. In its course it gives mall branches to the external pterygoid muscle, a branch (the *nterior deep temporal*) to the temporal muscle, and branches to he molar glands. The branches to the pterygoid and temporal nuscles are motory, the others are sensory.

The *internal pterygoid* supplies the internal pterygoid muscle.

The *subzygomatic* or *auriculo-temporal nerve* winds round the amus of the lower jaw, and, passing between the parotid gland nd the posterior border of the jaw, joins the nerves of the eventh pair. In its course it gives off twigs to the guttural ouch, parotid gland, and teguments of the temporal region.

The *lingual* or *gustatory*, the nerve of the SPECIAL SENSE OF ASTE, is the principal branch of the inferior maxillary; its ourse lies between the ramus of the jaw and the pterygoid nuscles, to reach the base of the tongue, along the side of which, under the mucous membrane, it runs to the tip, giving ff in its course numerous branches to the papillæ and mucous nembrane of the mouth, gums, and sublingual gland. The ngual receives the chorda tympani branch of the facial, and nastomoses with terminal branches of the twelfth pair: it also ends a branch to the submaxillary ganglion (Pl. XXVIII. fig. , *p*).

The *mylo-hyoidean* distributes branches to the mylo-hyoidean and digastricus muscles and twigs to the submaxillary glands.

The *dental branches* are given off in the dental canal, to supply the teeth of the lower jaw.

The *mental* or terminal branches of the nerve are distributed to the lower lip, and communicate with the facial.

The sympathetic ganglia annexed to the fifth pair, are the ophthalmic or lenticular, the spheno-palatine or Meckel's, the optic, and the submaxillary.

Sixth Pair.—The Abducens (Pl. XXVII. fig. 3, *f*), a nerve of motion, has its apparent origin close behind the pons Varolii at its junction with the inferior pyramids, and its fibres can be traced to the inferior pyramids and lateral bundles of the medulla. From its origin it passes forwards through the foramen lacerum orbitale in company with the third and the ophthalmic branch of the fifth, and is distributed to the abductor oculi and the external portion of the retractor oculi muscles.

Seventh Pair.—The Portio dura or Facial (Pl. XXVII. fig. 3, *g*) has its apparent origin in a depression in the medulla oblongata between the olivary and restiform bodies: its deep origin can be traced to the floor of the fourth ventricle and olivary fasciculi. From its origin it passes forwards, in company with the eighth nerve, along with which it enters the meatus auditorius internus, and thence into the aqueduct of Fallopius, where it bends upon itself and forms a slight enlargement, the *geniculat ganglion*, making its exit through the stylo-mastoid foramen, where it lies deeply buried beneath the parotid gland. Afterwards, inflected forwards, it passes between the gland and the guttural pouch to gain the posterior border of the maxilla, round the cervix of which it turns, and, mounting to the external surface of the masseter muscle, terminates in two or three branches, which anastomose with the subzygomatic branch of the fifth, forming the subzygomatic plexus.

In its course the facial nerve gives off numerous branches—

ome before leaving the bone, the interosseous, and some after eaving it, extraosseus.

The intra-osseous branches are the *superior petrosal*, which, eaving the genicular ganglion, re-enters the cranial cavity by he Fallopian hiatus, and passing forward along the cavernous inus, penetrates the orbital hiatus to Meckel's ganglion, which t furnishes with motor roots. A little to the outside of the bove, the *lesser superior petrosal* furnishes motor fibres to the ptic ganglion, and a small filament supplies the stapedius muscle. The *chorda tympani* branch is given off in the aqueduct of Fallopius. It enters the cavity of the tympanum, passes through he middle of the chain of small bones in the ear, and, leaving he cavity through the spiral foramen, after a short course under he pterygoid muscle, joins the gustatory nerve. The last intra-sseous branch is one which anastomoses with the pneumo-gastric.

After emerging from the stylo-mastoid foramen, the fascial nerve gives off branches to the stylo-hyoid and digastricus muscles; a cervical branch, which passes downwards below he deprimens aurem muscle to the panniculus and skin of neck; twigs to the guttural pouch and parotid gland; and astly, the anterior, posterior, and middle auricular nerves.

The *anterior auricular* ascends over the front of the ear, supplying the muscles and uniting with branches of the fifth, to form he auricular plexus. The *posterior auricular* passes upwards with he posterior auricular artery, and supplies the posterior muscles f the ear and the skin. The *middle auricular* enters the concha. o the inner surface and cartilage of which it is distributed.

The *terminal* or *temporo-facial* branches of the facial nerve re in two sets—an inferior, which passes downwards to the ower lip and muscles of the side of cheek and lower jaw; and superior, which supplies the muscles of the nose and tissue of ne lower lip. They anastomose with the terminal branches of ne superior and inferior maxillary divisions of the fifth, and, om the peculiar looped manner of their terminations, have btained the name of *pes anserinus*.

Eighth Pair.—The Portio dura, or Auditory (Pl. XXVII. fig. 3, *h*), the nerve of the Special sense of hearing, has its origin on the medulla oblongata, close to the facial nerve. Its deep roots are anterior and posterior, the one springing from the central grey matter of the medulla, and the other from the floor of the fourth ventricle. The auditory nerve enters the meatus auditorius internus in company with the seventh, and at the bottom of the passage divides into two branches—an *anterior* or *cochlear*, distributed to the cochlea, and a *posterior* or *vestibular*, which supplies the vestibule and the remaining portions of the internal ear.

Ninth Pair.—The Glosso-pharyngeal (Pl. XXVII. fig. 3, *i*; Pl. XXVIII. fig. 1, *b*, *b''*), a mixed motor and sensory nerve, principally distributed to the tongue and pharynx, arises from the medulla, the fibres composing it being traceable to the restiform bodies and the olivary fasciculæ. It pierces the dura mater through a distinct opening, and leaves the cranium through the foramen lacerum and asis cranii; previously, however, presenting a gangliform swelling, the *petrosal*, or *Andersch's ganglion*, which rests on the petrous bone. Leaving the cranium, it passes downwards and forwards, between the guttural pouch and masseter muscle, and along the posterior border of the greater cornu of the os hyoides, to gain the base of the tongue, being distributed to the mucous membrane and substance, principally of the base and sides of that organ. Its branches are the *nerve of Jacobson*, given off from the petrosal ganglion, and distributed to the tympanum and its membrane; filaments to the superior cervical ganglion; a branch to the carotid plexus; branches to the muscles of the pharynx; and a communicating branch to the pneumo-gastric.

Tenth Pair.—The Par vagum, or Pneumo-gastric (Pl. XXVII. fig. 3, *k*), is a mixed nerve, which originates by motor and sensory roots. Its apparent origin is from a groove in the medulla oblongata, immediately behind the ninth, and its deep roots can be traced to the restiform bodies, olivary fasciculi, and

rey matter, in the floor of the fourth ventricle. This nerve is emarkable for its extent, for the numerous dissimilar organs to which it is distributed, and for its free and extensive anastomoses with other cerebro-spinal, and with the sympathetic nerves. It ierces the dura mater in company with the eleventh nerve, and asses through the foramen lacerum basis cranii, previously pre-enting an oblong grey mass, the *jugular ganglion*.

After leaving the cranium, the par vagum descends behind he guttural pouch, close to the superior cervicular ganglion, rosses to the inner side of the occipital artery, and joining the ommon carotid, proceeds down the neck in the same sheath vith the artery. After entering the thorax, the course of the erve on the two sides varies. The *right nerve*, turning ob-iquely round the axillary artery, proceeds backwards by the ide of the trachea to the origin of the bronchi, where it gains he under and right side of the œsophagus; while the *left nerve* asses along the anterior aorta, crosses the origin of the posterior orta, and gains the upper and left side of the œsophagus, the wo being continued to the stomach and the solar plexus.

The branches of the par vagum are—

1. An anastomotic branch to the facial.
2. Numerous branches to the superior cervical ganglion.
3. A sensory-motor branch to the pharynx, which anastomoses vith the pharyngeal branch of the ninth (Pl. XXVIII. fig. 1, *c'*).
4. The *superior laryngeal*, which passes to the sides of the rynx, which it enters through a hole in the thyroid cartilage, eing distributed to the mucous membrane, and giving motor bres to some of the muscles of that organ (Pl. XXVIII. fig. , *c''*).
5. Filaments to the inferior cervical ganglion, two or three rge ones being given off by the *right nerve*, and one long nall branch, which is detached in the neck, by the *left nerve*.
6. The *inferior*, or *recurrent laryngeal nerve*.—On the right de, this nerve leaves the par vagum as it passes the first rib, nd winds round the origin of the dorsal artery, to gain the side

of the trachea. The left is given off near the root of the lung and is inflected round the posterior aorta to reach the trachea. Passing up the trachea, below the carotids, the nerves reach the larynx, and are distributed to the crico-arytenoid, posterior and lateral arytenoid, and thyro-arytenoid muscles, giving off in their course branches to the trachea and œsophagus.

7. Numerous branches at the root of the lungs, which form the *bronchial plexus*, from which branches are distributed to the divisions of the bronchi and to the lungs.

After this plexus is given off, each par vagum is continued along the œsophagus by a superior and an inferior branch. After a short course, the superior branches unite, and the inferior branches doing the same, they accompany the œsophagus, one above and the other below, supplying it with numerous twigs, till they enter the abdomen through the œsophageal opening of the diaphragm, when the inferior branch terminates at the lesser curvature of the stomach, in a plexus which sends numerous branches to the right sac of that organ; and the superior branch, passing to the left of the cardiac orifice, becomes lost in the solar plexus. In passing, it gives numerous twigs to the left sac of the stomach, mingles its branches with those of the sympathetic from the hepatic plexus, and anastomoses with the terminal twigs of the right nerve.

Eleventh Pair.—The Spinal accessory (Pl. XXVII. fig. 3, *l*; Pl. XXVIII. fig. 1, *d*, *d'*), a nerve of motion, arises from the cervical portion of the spinal cord, close to the superior roots of the spinal nerves, and, after entering the cranium by the foramen magnum, receives additional filaments from the medulla oblongata. It passes through the dura mater, in company with the tenth pair, and leaves the cranium through the foramen lacerum basis cranii. In the cranial cavity, it gives twigs to the par vagnum, and, after emerging from it, is directed backwards under the superior extremity of the submaxillary gland, and passing down the neck, gains the border of the levator humeri muscle near the shoulder; then mounting

slightly upwards, it crosses under the cervical trapezius, and is lost in the dorsal trapezius and rhomboideus brevis muscles.

In its course, it gives off numerous twigs to the superior cervical ganglion, to the maxillary gland, and a large branch to the sterno-maxillaris, levator humeri, and trapezius muscles, and receives branches from the first, second, third, fourth, fifth, and sometimes sixth cervical nerves.

Twelfth Pair.—The Hypo-glossal (Pl. XXVII. fig. 3, *m;* Pl. XXVIII. fig. 1, *e*), a motor nerve, has its origin in numerous filaments derived from the medulla oblongata. It makes its exit from the cranium by the condyloid foramen of the occipital bone, descends by the external face of the guttural pouch, and is distributed to all the muscles of the tongue.

The Spinal Nerves.

The nerves which emanate from the spinal cord, and make their exit through the intervertebral foramina or holes of conjugation, are the spinal nerves. They consist of forty-two or forty-three pairs, and are divided, according to regions, into eight cervical, seventeen dorsal, six lumbar, five sacral, and six or seven coccygeal pairs. The whole of the spinal nerves originate by two orders of roots, *superior* or *sensory*, and *inferior* or *motory;* the former, which are larger and more numerous, arising from the superior lateral fissure, and the latter from the inferior lateral fissure of the cord. In the intervertebral foramina, there is a *ganglion on each of the superior roots*, underneath which the inferior root passes. The union of the two roots constitutes the spinal nerve, which, almost immediately after it passes through the foramen, divides into two terminal branches—a *superior* distributed to the spinal muscles and the integument which covers them; and an *inferior*, longer and larger, distributed to the inferior and lateral parts of the trunk and extremities, and which sends numerous communicating branches to the sympathetic system.

Cervical Nerves (8 pair).

The first cervical nerve, the sub-occipital of Willis, leaves th spinal canal through the anterior intervertebral foramen of th atlas; the second through a foramen in the anterior part of th axis, the succeeding five through the corresponding holes of con jugation, and the eighth between the last cervical and first dor sal vertebræ.

Superior branches.—The superior division of the *first* nerve after reaching the interstice between the superior oblique and the posterior straight muscle of the head, divides into numerous branches, which are distributed to the muscles at the back of the poll and to the retrahentes muscles of the ear; one long branch, which anastomoses with the posterior auricular branch of the seventh cranial nerve to form the *auricular plexus*, being sent to the concha, and the skin covering it (Pl. XXVIII. fig. 1, *g*).

The *second*, situated under the obliquus capitis muscle, to which and the superior oblique it gives branches, is distributed in a similar manner to the superior branches of the remaining cervical nerves. These, gradually diminishing in size as they proceed backward, penetrate the transverse muscles, and divide into *superficial branches*, distributed to the superficial muscles and skin, and the *deep branches*, larger than the others, which cross the transverse spines, and form the *deep cervical plexus* from which the deep muscles are supplied.

Inferior branches.—The inferior divisions of the cervical nerves gradually increase in size from the first to the last. They separate into two distinct groups composed of the anterior six, which furnish branches to the muscles and skin of the breast, and of the lateral and forepart of neck, transmitting intercommunicating branches, which form a vast net-work, known as the superficial cervical plexus, and which is transversed by the cervical branch of the facial and an important branch from the

spinal accessory nerves; and the last two, which, together with a branch from the sixth, join the two first dorsal nerves to form the brachial plexus.

The First Cervical nerve passes through the foramen in front of the atlas in company with the occipital artery and vein, crosses the rectus anticus major muscle and the spinal accessory nerve, and, describing a curve towards the top of the trachea, enters the subscapulo-hyoideus muscle, where it terminates in numerous branches. In its course it furnishes filaments to the three recti muscles, to the thyro-hyoid, thyro-hyoideus, sterno-maxillaris, and muscles connecting the hyoid bone to the larynx, and communicates with the superior cervical ganglion and spinal accessory and hypo-glossal nerves.

The Second Cervical nerve descends under the inferior oblique, crosses the rectus anticus major, and is distributed by numerous branches to the rectus anticus major and minor, levator humeri, deprimens aurem, retrahentes aurem, subscapulo-hyoideus muscles, to the outer side of concha, and to the panniculus and skin, and communicates with a branch of the spinal accessory and cervical branch of the facial nerves, and with the inferior cervical ganglion of the sympathetic.

The Third, Fourth, Fifth, and Sixth Cervical nerves pass through the intertransverse muscles, and divide into deep and superficial branches, the one being distributed to the deep muscles of the neck and anterior part of shoulders, and the other to the skin of neck and panniculus. The deep branches of the sixth and seventh, and a filament, not constant, from the fifth, uniting with a branch from the brachial plexus, constitute the diaphragmatic nerve.

The Seventh Cervical nerve, a large nerve, passes between the two portions of the scalenus, and enters the brachial plexus. It receives an anastomosing branch furnished by the sixth pair.

The Eighth Cervical nerve, larger than the preceding, also passes to the brachial plexus. It sends a branch to the inferior cervical ganglion.

Dorsal Nerves (17 pair).

The dorsal nerves, with the exception of the first, are all distributed in a similar and very simple manner, as compared with the cervical nerves. The *superior branches*, passing up between the transverse processes, bifurcate, one branch being sent to the spinal muscles and the skin of the dorsal region, the other being distributed to the longissimus dorsi muscle. The *inferior branches* descend to the intercostal spaces, and pass along between the pleura and internal intercostal muscles. Each of these *intercostal nerves*, at its origin, gives a branch to the sympathetic, and, towards its middle, branches directed obliquely outwards to the skin, where they ramify, and, in their course, give off muscular filaments.

The *inferior branch of the first* goes almost entirely to the brachial plexus. It has no cutaneous division, and its intercostal branch is very slender.

The Second Dorsal nerve sends a large branch to the brachial plexus. Its intercostal branch, more considerable than that of the first, extends down to the sternum, and gives off cutaneous twigs.

The Third, Fourth, Fifth, Sixth, Seventh, and Eighth Dorsal nerves pass to the extremity of the intercostal spaces, and are prolonged into the pectoralis major and rectus muscles, *the last nine*, after reaching the cartilages of the false ribs, are continued into the walls of the abdomen, and under the internal oblique, to the rectus, where they divide, one division going to the substance of the muscles, the other furnishing twigs to the skin of the belly. The Seventeenth dorsal nerve furnishes a large branch to the fleshy portion of the internal oblique, and another which anastomoses with the first lumbar.

Plate XXIX

SPINAL NERVES

PLATE XXIX.

SPINAL NERVES.

Fig. 1.—Brachial Plexus and its Branches exposed on the right side.

a. Seventh cervical nerve. *b*. Eighth cervical nerve. *c*. First dorsal nerve. *d*. Branch of communication between the first and second dorsal nerves. *e*. Anterior thoracic nerves. *f*. Posterior thoracic nerves. *g*. Anterior scapular nerve. *h*. Middle scapular nerve. *i*. Posterior scapular nerve. *k*. Ulnar nerve. *l*. Anterior brachial nerve. *m*. Posterior brachial nerve. *n*. Median nerve. *o*. Anterior radial nerve. *p*. Posterior radial nerve.

Fig. 2.—Inner side of Left Fore-foot, with the Nerves.

q. External volar nerve. *r*. Internal volar nerve. *s*. Inner branch of ulnar nerve. *s'*. Outer branch of ulnar nerve. *t*. Point of communication of inner branch of ulnar nerve with external volar nerve. *u*. Branch of communication between external volar nerves. *v*. Internal digital nerve.

Fig. 3.—The Lumbar and Sacral Plexus exposed on the right side.

(The Abdominal and Pelvic Cavities are opened and the Viscera and Sciatic Ligaments removed.)

1. Last lumbar nerve. 2. First sacral nerve. *a*. External spermatic nerve. *b*. Anterior crural nerve. *b'*. Internal cutaneous nerve. *b''*. Continuation of anterior crural nerve. *c c*. Obturator nerve. *d*. Anterior gluteal nerve. *d'*. Posterior gluteal nerve. *d''*. Posterior cutaneous nerve. *e e'*. Sciatic nerve. *f*. Posterior crural nerve. *g*. Middle crural nerve. *h*. Small tibial nerve. *i*. Large tibial nerve.

Fig. 4.—Nerves of Lower Part of Hind-leg, seen from the inner side.

k. Internal cutaneous tibial nerve. *l*. External plantar nerve. *m*. Internal plantar nerve. *n*. Communicating branch between them. *o*. Internal digital nerve.

Lumbar Nerves (6 pair).

The *superior branches* of the lumbar nerves are distributed to the muscles of the loins, and to the integument of the loins and croup.

The *inferior branches* send twigs to the sympathetic, and branches which anastomose with one another.

The First Lumbar nerve receives a branch from the last dorsal, and turning backwards under the transverse processes of the second lumbar vertebra, passes through the transversalis abdominis and internal oblique, to which it sends filaments, and terminates at the insertion of the rectus. Near its origin, it gives off a branch which, uniting with a branch from the second, furnishes numerous twigs to the psoas magnus, and, passing through the abdominal muscles, terminates in numerous cutaneous filaments.

The Second Lumbar nerve has similar anastomosing branches to the first, and a branch which, receiving a small branch from the third, descends under the skin of the internal face of the thigh, and is distributed to the skin of the flank and the crural region.

The Third, besides its anastomosing branches, sends a long branch downwards and outwards to the inguinal canal, where it ramifies in the cremaster muscle; it also furnishes numerous twigs to the psoas magnus, and a branch which unites with a large branch of the fourth.

The Fourth Lumbar, besides the branches common to all, gives a large branch to the lumbar plexus, and a long branch which, after uniting with a branch from the third, is directed downwards to the thigh, where it terminates in numerous cutaneous and aponeurotic branches.

The Fifth Lumbbar gives a large branch to the lumbar plexus, and branches to the psoas parvus.

The Sixth Lumbar is the principal branch of the sacro-lumbar plexus.

Sacral Nerves (5 pair).

The sacral nerves, which diminish in size from the first to the last, have their origin close to each other, their roots surrounding the pyramidal point in which the spinal cord terminates, and by which it extends into the canal of the sacrum. With the coccygeal and the last lumbar they form the nerve tuft known as the *cauda equina.*

The *superior branches* of the sacral nerves leave the spinal canal through the superior sacral foramina, and are distributed to the muscles of the superior face of the sacrum, and terminate in the skin of the croup.

The *inferior branches*, the *first three* of which go to assist in the formation of the sacro-lumbar plexus, divide at the sides of the pelvic cavity. The *fourth* constitutes the *internal pudic nerve*, which, at its origin, sends an anastomosing branch to the origin of the fifth. It is distributed to the penis, where it terminates, by numerous branches, in the glands. Before leaving the pelvic cavity, it sends filaments to the muscles and skin of the perineo-anal region. In the female, this nerve is distributed to parts analagous to those of the male.

The *fifth* forms the anal or hæmorrhoidal nerve, distributed to the sphincter ani, and the skin covering it.

Small filaments which form the *pelvic* or *hypogastric* plexus are given off from near the origin of all the sacral nerves.

Coccygeal Nerves (6 or 7 pair).

The coccygeal nerves differ from the other spinal nerves in having no communication with the sympathetic. They diminish in size from the first to the last. The *superior* branches unite to form one large nerve, which passes under the curvator coccygeal muscle, and extends to the tip of the tail, giving off muscular and cutaneous filaments in its course; the inferior branches

likewise coalesce and extend in a similar manner under the depressor muscle.

The inferior branch of the first coccygeal receives a branch from the last sacral, and sends a filament down towards the anus and perinæum.

Nerves formed by the Inferior Branches of the Spinal Nerves.

The Diaphragmatic Nerve.—The diaphragmatic, the motor nerve of the diaphragm, is constituted of two principal branches, furnished by the sixth and seventh cervical nerves, with a filament, not constant, from the fifth. It enters the thoracic cavity, and passing to the inner side of the axillary artery receives a filament from the sympathetic; thence it travels between the two layers of the mediastinum, and reaching the centre of the aponeurotic portion of the diaphragm, divides into numerous branches, which are carried towards the periphery of the muscle.

The Brachial Plexus.—The brachial plexus comprehends that large bundle of nerves formed of the inferior branches of the sixth, seventh, and eighth cervical, and the first and second dorsal nerves, all of which converge towards the intestine between the two divisions of the scalenus muscle, where they unite, and, passing out, turn round the first rib. Below the arm, the plexus divides into numerous branches distributed to the muscles and teguments of the anterior extremity (Pl. XXIX. fig. 1, and description).

The Anterior scapular is a large branch which supplies the muscles on the dorsum of the scapula; it turns round the anterior border of the bone, a little above its neck, and passing under the antea-spinatus, to which and to the postea-spinatus it gives twigs, terminates in the caput magnum.

The Thoracic (Pl. XXIX. fig. 1, *e*, *f*) consists of six or seven branches of unequal size and length, distributed to the muscles between the shoulder and the trunk; three or four are directed

obliquely downwards, losing themselves in the muscles attached to the sternum—one, winding round the posterior border of the caput muscle, becomes superficial, and is distributed to the panniculus and skin; and the remainder, carried backwards, are distributed to the latissimus dorsi and serratus magnus.

The Subscapular includes two principal cords, the smallest of which goes to the subscapularis, and the larger, the *posterior scapular nerve*, turning round the scapulo-humeral articulation, terminates in a subcutaneous branch which descends the arm. It supplies the subscapularis, teres minor, and levator humeri, and furnishes articular and cutaneous filaments.

The Posterior humeral or Spiral nerve (Pl. XXIX. fig. 1, *l*, *m*), a considerable branch of the brachial plexus, is principally furnished by the first dorsal. It arises behind the humeral artery, and is directed backwards and downwards under the subscapularis and teres major muscles, being accompanied for a short distance by the artery. Near the deep humeral, it turns round the back of the humerus, between the caput magnum and humeralis obliquus muscles, and passing down the outer surface of the bone gains the face of the elbow joint, and terminates in the flexor metacarpi externus. In its course it gives off branches to the caput muscles and scapulo-ulnaris, to the elbow joint, and to the skin covering the arm as low down as the knee.

The Ulnar or Cubital cutaneous nerve (Pl. XXIX. fig. 1, *k*; fig. 2, *s s'*) is formed of fibres from the second pair of dorsal; it is less than the spiral, and originates on the outer side of the humeral artery, which it accompanies to below the origin of the deep humeral, which it crosses, and passing between the scapulo-ulnaris and caput parvum muscles, gains the inner side of the elbow. Afterwards, descending to the bend of the knee, it passes under the annular ligament and divides into two branches, one of which unites with a branch from the radial to constitute the external metacarpal nerve, and the other, traversing the space between the tendons of the extensor meta-

carpi externus and medius, is distributed by numerous branches to the skin, covering radius, knee, and outer side of cannon.

In its course, the ulna nerve gives off a branch which proceeds downwards between the scapulo-ulnaris and pectoralis transversalis, furnishing many filaments to the latter, and becoming cutaneous, is distributed to the skin below the elbow. It also furnishes a branch to the flexor metacarpi muscles.

The Radial nerve (Pl. XXIX. fig. 1, *o*, *p*), composed of fibres from the two dorsal and the eighth cervical, descends the humerus in company with the humeral artery to the inner side of the elbow, runs down the side of the radius till it reaches the knee, and then passing under the posterior annular ligament, divides into the *internal metacarpal*, and a branch to the external metacarpal nerves. In its course it gives off, under the axillary artery, a branch to the pectoral muscles; and near the middle of the humerus, a long branch which passes obliquely under the coraco-humeralis and radialis muscles, where it divides—one branch going to the humeralis externus, while the other, passing between this muscle and the coraco-humeralis, gains the inner face of the arm, where it becomes subcutaneous, and ramifies on the ante-brachial fascia, sending its branches down to the knee. It also supplies numerous filaments to the elbow joint, and to the flexor muscles of the phalanges and internal metacarpus.

The Metacarpal nerves run down the leg by the side of the flexor tendons, to which they give filaments, and terminate at the fetlock. Midway down the cannon bone, they anastomose by means of an oblique branch. At the fetlock, near the insertion of the suspensory ligament into the sesamoid, each metacarpal nerve divides into three branches—anterior, middle, and posterior.

The *anterior branch* descends in front of the plantar vein, and distributes its branches on the anterior surface of the foot. The *middle branch* frequently anastomoses with the others, and always with the anterior branch. It supplies the fetlock pad

and sensible sole. The *posterior branch*, by far the largest, and the true continuation of the metacarpal nerve, is continued behind the plantar artery to the basilar process of the os pedis entering the lateral fissure, and being distributed to the substance of the bone and the laminæ. It gives off branches to the flexor tendons, and a filament which is carried forwards and distributed to the fatty frog.

The Lumbo-Sacral Plexus.

(Pl. XXIX. fig. 3, and description).

This plexus, formed by the inferior branches of the two last lumbar and the three first sacral, is divided into two portions—an anterior or lumbar, and a posterior or sacral, each of which has a large trunk for its centre. The anterior division is constituted by the above mentioned lumbar nerves receiving, after a short course, a branch from the fourth; the posterior division is formed by the first three sacral, which unite to form a single bundle. These trunks are re-united by anastomosing branches.

The *anterior division* is buried under the psoas parvus, and is separated from the posterior division by the internal iliac artery. The *posterior division* is placed above and on the sides of the pelvic cavity. The anterior division furnishes iliaco-muscular branches, and terminates in the crural and obturator nerves. The posterior division gives off ilio-muscular and ischio-muscular branches, and terminates in the greater and lesser femoro-popliteal nerves.

The Iliaco-muscular are numerous small branches which accompany the iliaco-muscular artery, and are distributed to the psoas and iliacus muscles.

The Crural, or Anterior Femoral (Pl. XXIX. fig. 3, *b*), is the largest branch of the anterior division. It descends between psoas magnus and psoas parvus, and passing under the sartorius, plunges between the rectus femoris and vastus internus, distributing branches to these muscles. Near the groin, it sends a

ong subcutaneous branch down the leg, in company with the nternal saphena vein, which, gaining the inner face of the leg, s continued to the hock, and, by delicate branches, as far as the etlock and pastern. In its course, this branch furnishes filanents to the stifle, to the adductors and pectineus muscles, and o the skin of the anterior and inner part of leg.

The Obturator, or Sub-pubic femoral nerve (Pl. XXIX. ig. 3, *c c*), situated at first under the peritoneum, accompanies he obturator artery through the obturator foramen, and gaining he muscles on the internal face of the thigh, terminates in the bturator externus, abductors, pectineus, gracilis, and short adluctor muscles, also giving twigs to the obturator internus.

The Ilio-muscular or Anterior Gluteal nerves (Pl. XXIX. ig. 3, *d*), four or five in number, leave the pelvis through the ciatic notch. The principal branch loses itself in the gluteus naximus, another crosses the neck of the ilium, and underneath he gluteus internus is directed outwards, and distributed to the ensor vaginæ. The last passes to the gluteus internus, in the substance of which it terminates.

The Ischio-muscular, or Posterior Gluteal nerves (Pl. XXIX. fig. 3, *d'*), are superior and inferior. The first, the course of which lies between the sacro-sciatic ligament and the gluteus maximus muscle, to the posterior portion of which it gives a small branch in passing, and sends another to the gluteus externus, terminates by numerous branches in the adductor magnus muscle. The second (*posterior gluteal nerve*) is situated below the preceding, and supplies the biceps rotator tibialis muscle and skin of the posterior part of the haunch.

The Sacro-sciatic nerve is the largest nerve in the body. It divides into lesser and greater sciatic nerves (Pl. XXIX. fig. 3, 4).

The Lesser Sciatic, or Lesser Femoro-popliteal nerve Pl. XXIX. fig. 3, *e e'*), is placed in front of the greater sciatic. It leaves the pelvis in company with that nerve, through an opening in the anterior part of the sacro-sciatic ligament, and is directed downwards along the posterior face of the femur.

Entering the muscles, it passes between the adductor magnu and gastrocnemius externus, and arrives at the superior extremit of the leg, behind the lateral ligament of the femoro tibia articulation, when it terminates in two branches—one short, an plunged into the muscles fixed to the superior extremity of th anterior face of the tibia in which it ramifies, the other (th *anterior tibial nerve*), larger and cutaneous, which turns down wards by the outer side of the anterior surface of the leg, an passing the hock, metatarsal bone, and fetlock, terminates at th pastern. It gives off numerous cutaneous, muscular, and cuta neous filaments.

The Greater Sciatic, or Greater Femoro-popliteal nerve the largest branch of the lumbo-sacral plexus, leaves the pelvi through the foramen, in the anterior part of the sacro-sciati ligament, and descends the femur in the same direction as th smaller nerve. Near the stifle, it passes between the two por tions of the gastrocnemius externus, where it forms two branches —a short one, which enters the muscles attached to the posterio part of the tibia, and is distributed to the flexor pedis, popliteus and flexor pedis accessorius muscles; and a principal branch the *tibial* or *popliteal*, which descends at the posterior part o the tibia, below the gastrocnemius internus, and divides at th hock into *external* and *internal metatarsal* branches. In it course, the sciatic nerve furnishes filaments to all the muscles situated at the posterior part of thigh, viz., two or three branches to the biceps rotator tibialis, and branches to the gastrocnemius externus and internus.

The External and Internal Metatarsal nerves pass down the side of the flexor tendons, and terminate as the planta nerves. Towards the superior extremity of the cannon bone the external metatarsal nerve is carried outwards between th small splint and the tendon, while the internal is placed on th inner side of the tendon, and gains the posterior border of th inner small splint. The *plantar nerves* are distributed in a similar manner to the nerves of the fore feet.

Sympathetic Nerves.

The *sympathetic* (trisplanchnic or ganglionic system of nerves), he nerve of organic or vegetable life, consists of two large cords r chains of nerves, which extend from the head to the posterior xtremity of the sacrum under the lateral parts of the bodies of he vertebræ on each side of the vertebral column. These nerve ords are furnished with a number of ganglia, which both give nd receive numerous communicating filaments from the other erves. As a system, it is specially destined for the use of the lood-vessels and viscera.

For the convenience of description, the sympathetic may be ivided into five regions, viz., the cephalic, cervical, dorsal or horacic, lumbar or abdominal, and sacral or pelvic.

The cephalic portion consists of the *opthalmic* or *lenticular*, *pheno-palatine* or *Meckel's*, *otic*, *submaxillary*, and *Andersch's anglia.*

The Lenticular ganglion is situated between the optic nerve nd the inferior oblique muscle of the eye, in close contact with he motor oculi nerve and the ophthalmic artery. Its motor root s furnished by the third pair, and its sensory is derived from the alpebro-nasal. It also communicates with the superior cervical anglion. Its efferent branches are the ciliary nerves, which accom- any the ciliary arteries, and supply the tunics of the eye-ball.

Meckel's ganglion, much larger than the ophthalmic, is ituated between the pterygoid process of the palatine and the uperior part of the maxillary bones, in close contact with the uperior maxillary division of the fifth pair. Its motor root is ormed by the Vidian nerve, by which it is also attached to the uperior cervical ganglion, and its sensory roots are derived from he spheno-palatine nerve. Its emergent branches are numerous, nd are sent to the muscles and vessels of the orbit, to the soft nd hard palate, to the nose, and to the superior cervical and phthalmic ganglia.

The Otic ganglion (Arnold's) is inconstant; it is connected with the inferior division of the fifth pair, under the guttural pouch and close to the Eustachian tube; its sensory root is derived from the buccal nerve, and its motory from the small superficial petrosal. It also communicates with the cervical ganglion. Its emergent branches are to the muscles of the middle ear, to the Eustachian tube, and to the pterygoid and tensor palati muscles.

The Submaxillary Ganglion is situated above the submaxillary gland, in close relation with the gustatory nerve. Its emergent branches are sent to the submaxillary gland, Wharton's duct, and the mucous membrane of mouth.

Cervical Portion of the Sympathetic Nerve.

The cervical portion of the sympathetic chain is formed of two large ganglia, connected by an intermediate cord, and placed one at the superior, and the other at the inferior extremity of the neck.

The Superior Cervical or Guttural ganglion, a long, fusiform body in close connection with the internal carotid artery, and included with it in a fold of the membrane of the guttural pouch, is situated in front of the wing of the atlas, and in close proximity to the ninth, tenth, eleventh, and twelfth cranial nerves, and the sub-occipital, from all of which it receives efferent branches. These filaments form a plexus round the ganglion, known as the *superior cervical plexus*. The emergent branches of the superior cervical ganglion are divided into three orders, viz.—1*st*, Those accompanying the internal carotid into the cranium; 2*d*, A large bundle, which gains the origin of the terminal divisions of the primitive carotid; and 3*d*, Small filaments supplying the guttural pouch and pharynx.

1. The branches which accompany the carotid, generally two in number, the anterior being largest, wind round the artery, and anastomose one with the other. Penetrating the cavernous sinus,

hey form the *cavernous plexus*, by which they communicate with nany of the cranial nerves, and send filaments to join analagous ilaments from the opposite side. A branch from this plexus oins the superior petrosal nerve, and contributes to the for- nation of the Vidian nerve, which joins the spheno-palatine ganglion. In company with fibres from the opthalmic branch of the fifth, it communicates with the opthalmic ganglion, and lso sends a filament to the Gasserian ganglion, and mingles its ibres with those of the third, fourth, and sixth pairs, or motor nerves of the eye.

2. The fasciculi joining the common carotid leave the inferior part of the ganglion in numerous branches united by communi- ating filaments; at the division of the artery, they anastomose vith branches from the glosso-pharyngeal and pneumo-gastric, orming the *carotid plexus*, the ramifications of which are almost xclusively distributed to the external carotid and salivary glands, ne twig being sent to the otic ganglion.

3. The guttural or pharyngeal are very delicate branches, which eave the anterior border of the ganglion, and, gaining the supe- ior walls of the pharynx, anastomose with filaments from the losso-pharyngeal and pneumo-gastric, and form the *pharyngeal lexus.*

The intermediate cord leaves the inferior part of the ganglion, nd passes down the neck in company with the par vagum to the ntrance to the thorax, where it joins the inferior ganglion.

The Inferior Cervical ganglion, larger than the superior, s placed on the inner side of the costal insertion of the scalenus nuscle and against the trachea, the right ganglion being always little in advance of the left, which is separated from the trachea y the œsophagus. The form of this ganglion is variable and regular, sometimes being lenticular and sometimes elongated, ut always more or less radiated. Occasionally it is double: in his case, which occurs more generally in the right than in the eft ganglion, the two portions are distinguished as anterior and osterior—the former, which is the smaller, being the *middle*

cervical ganglion of the human anatomists, the two being joine by a short ribbon of grey matter.

This ganglion receives two branches from the cervical nerve one being formed by filaments which emanate from the secon to the seventh pairs, inclusive, the other being a single branc from the eighth. In addition to these, several filaments ar transmitted to it from the pneumo-gastric.

The emergent branches detached from the inferior and poste rior parts of the ganglion chiefly supply the heart, some fila ments being sent to the anterior mediastinum and the arterie of the brachial trunk.

The CARDIAC NERVES which accompany the aorta are distri buted to the tissue of the ventricles and auricles; some follow the divisions of the pulmonary artery, and assist in the formation of the brachial plexus; and others, following the axillary arteries and trachea, form, on the inferior face of the latter, a very large fasciculus known as the *tracheal plexus*. This plexus is tra versed by the two recurrent nerves, which give and receive numerous filaments as they pass.

THORACIC PORTION OF THE SYMPATHETIC NERVE.

(Pl. XXX. fig. 1, and description).

The cord which represents the dorsal portion of the sym pathetic chain, extends from the inferior cervical ganglion to the diaphragm, crossing the intercostal arteries and passing under the vertebro-costal articulations, against which it is fixed by the pleura. Passing through the arch at the superior border of the diaphragm by the side of the psoas parvus muscle, it is con tinued into the abdominal cavity by the lumbar portion. During its passage through the thorax, seventeen small fusiform ganglia, one at each intercostal space, present themselves. The afferent branches, from one to three generally, are furnished by the inferior branches of the dorsal nerves, which pass through the holes of conjugation to each ganglion. The emergent

PLATE XXX.

VISCERAL NERVES.

Fig. 1.—The Cavity of the Chest opened from the Left Side, showing the Branches of the Phrenic and Pneumo-gastric Nerves, along with those of the Thoracic Portion of the Great Sympathetic.

1. Heart. 2. Anterior aorta. 3. Posterior aorta. 4 4. Trachea. 5 5. Œsophagus. 6. 7th Cervical nerve. 7. 8th Cervical nerve. 8. 1st Dorsal nerve. 9 9. Diaphragm. *a.* Spot where the pneumo-gastric nerve separates from the sympathetic. *b.* Pneumo-gastric nerve. *c c.* Its recurrent branch. *d.* Nerves of the heart. *e.* Superior branch of 10th cranial nerve. *f.* Its inferior branch. *g g g.* Phrenic nerve. *g′.* Its origin from the 6th cervical nerve. *g″.* Its origin from the 7th cervical nerve. *h.* Termination of cervical portion of sympathetic nerve. *i.* Its inferior cervical ganglion. *k.* Its first dorsal ganglion. *l l l.* Thoracic portion of great sympathetic nerve. *m m.* Points of communication between it and twigs of the inferior branches of the spinal nerves. *n.* Continuation of the sympathetic nerve. *o.* Splanchnic nerve.

Fig. 2.—Abdominal Portion of Great Sympathetic Nerve, along with the Splanchnic Nerve, seen from the Left Side of the Abdominal Cavity.

1. Abdominal portion of posterior aorta. 2. Liver. 3. Stomach. 4. Spleen. 5. Anterior root of mesentery. 5′ 5′. Coils of small intestine. 6. Left kidney. 7. Posterior root of mesentery. 7′. Rectum. *a a.* Abdominal portion of great sympathetic nerve. *a′ a′.* Twigs of communication between the lumbar and sympathetic nerves. *a″ a″.* Branches of communication between the symphatetic nerve and posterior mesenteric plexus. *b.* Splanchnic nerve. *c.* Solar plexus. *d.* Hepatic plexus. *e.* Gastric plexus. *f.* Splenic plexus. *g.* Anterior mesenteric plexus. *h.* Left renal plexus. *i.* Posterior mesenteric plexus. *k.* Left spermatic plexus.

branches are some small fibres, which supply the pleura and the large and small splanchnic nerves.

The GREAT SPLANCHNIC NERVE (Pl. XXX. fig. 2, *b*) is detached from the sixth or seventh ganglion, and receives, in its backward course, reinforcement from all the other ganglia except the last two or three. It penetrates the abdominal cavity by the arch of the psoas, when it presents a small ganglionic mass, and is then bent inwards, and terminates in a large ganglion, the semilunar or solar ganglion, between the cœliac axis and the anterior mesenteric trunk.

The SEMILUNAR GANGLIA, the largest of all the sympathetic ganglia, are elongated from before backwards, and flattened from above downwards. They communicate by means of a large and strong grey cord, which passes behind the mesenteric trunk, and by a number of filaments which proceed from right to left in front of this artery. On the inferior face of the aorta these filaments form the *solar plexus*, which receives branches from the superior cord of the par vagum, and is divided, at its periphery, into numerous secondary plexuses, from which numerous ramifications interlace and anastomose in a very complex manner round the divisions of the arteries which they accompany into the neighbouring organs.

Of these secondary plexuses, the *gastric* distributes its branches to the stomach, on the walls of which they anastomose with the pneumo-gastric; the *hepatic* supplies the liver, duodenum, pylorus, and pancreas; the *splenic*, the spleen and part of the stomach; the anterior *mesenteric*, the largest of all, the viscera supplied by the anterior mesenteric artery; and the *renal* and *supra-renal*, double and less distinct than the others, the kidneys and supra-renal capsules.

The numerous strong branches which leave the solar plexus, behind the anterior mesenteric artery and run along the inferior face of the aorta, frequently anastomosing with each other, form the *lumbo-aortic plexus*, which unites with the posterior mesenteric plexus.

The Lesser Splanchnic nerve is formed by filaments from the last dorsal ganglia, which, instead of uniting with the great splanchnic, are sent direct to the solar plexus, and commingle with the nerves of the kidneys and supra-renal plexus.

Lumbar Portion of the Sympathetic Nerve.

(Pl. XXX. fig. 2.)

The lumbar or abdominal portion of the sympathetic chain is a continuation of the dorsal, and, like it, has fusiform ganglia at each lumbar nerve. It rests against the psoas parvus muscle, near the inferior common vertebral ligament, and is covered, on the left, by the aorta, and, on the right, by the posterior vena cava. It is directly continuous with the sacral portion at the sacro-lumbar articulation.

The afferent branches to the lumbar ganglia are furnished by the inferior branches of the lumbar nerves; the emergent branches, analogous to those which form the splanchnic nerves, are not constant in number, but are generally fewer than the ganglia. Two or three of them unite with the lumbo-aortic plexus, and the others, gaining the origin of the posterior mesenteric artery, and anastomosing with posterior branches of the lumbo-aortic, form the *posterior mesenteric plexus*, which contains a ganglion more or less voluminous in its centre. The ramifications of this plexus are carried under the different branches of the posterior mesenteric artery to be distributed to the floating colon and rectum; and two or three large branches join the anterior mesenteric plexus, after having sent numerous divisions to the colic mesentery. Branches from it also embrace and accompany the spermatic arteries, constituting the *spermatic plexus;* and, lastly, two other long divisions enter each side of the pelvis, and being distributed over the external surface of the peritoneum, gain the side of the rectum, where they meet filaments which emanate directly from the sacral nerves. The anastomosing of these divisions results in a rich

nervous net-work, the *pelvic* or *hypogastric plexus*, which supplies all the organs contained within the pelvis.

Sacral Portion of the Sympathetic Nerve.

The sacral or pelvic portion of the sympathetic is the continuation of the lumbar, and is situated under the sacrum, and to the inner side of the sacral nerves. It presents four ganglia, which communicate with these nerves by numerous filaments, and give off several small twigs, which are lost in the cellular tissue on the inferior face of the sacrum.

The termination of the sympathetic nerve is not always the same, and while it often ends in a delicate filament, which is carried under the middle sacral artery, and anastomoses with that of the opposite side, it sometimes terminates in a filament which communicates with the last pair of sacral nerves.

THE ORGAN OF HEARING.

(Pl. XXVII. figs. 7, 8, 9.)

The apparatus of hearing is composed of three parts—the external, middle, and internal ears; the two first being accessory for the collection and transmission of sounds, and the latter the essential organ which receives the impressions.

The External ear consists of the *concha*, already described, and the *meatus auditorius externus* or passage, which extends from the base of the concha to the tympanum. It is partly osseous and partly cartilaginous, and is narrower in the middle than at either extremity. Its lining is a continuation of the skin of the concha, which gradually becomes thinner as it descends, and is perforated by numerous small openings from the *ceruminous glands*, which secrete the wax of the ear.

The Middle ear, or Tympanum, is an irregular bony cavity within the petrous temporal bone. It is bounded *externally* by the membrana tympani; *internally*, by the bony walls of the

internal ear; *anteriorly*, by the Eustachian tube; and *posteriorly*, by the mastoid cells.

The Membrana tympani, or Drum of the ear (Pl. XXVII. fig. 7, *a*), is a semi-transparent, nearly circular membrane, with its middle drawn inwards. It is inserted into a groove round the inner end of the meatus, and is composed of *three layers*—*external* or epidermic, a prolongation of the skin lining the meatus; *middle* or fibrous, the fibres being in two sets, one radiating from the centre to the circumference, the other scattered and indistinct, except near the periphery, where they form a dense ring; and *internal* or mucous, derived from the mucous lining of the middle ear.

A chain of small bones—Ossicula auditus—stretch across the tympanum. They are the malleus, incus, stapes, and orbiculare.

The Malleus or Hammer (Pl. XXVII. fig. 7, *c*) presents a rounded head (*capitulum*), a neck, a handle (*manubrium*), a long process (*processus gracilis*), and a short process (*processus brevis*). The head articulates with the incus; the handle is received between the inner and middle coats of the membrana tympani; the long process, very slender, extends to the Glaserian fissure; and the short process, very obtuse, lies in contact with the drum.

The Incus or Anvil, which in shape somewhat resembles the bicuspid tooth of man, has a body and two crura or processes. The body is concave on its surface, and articulates with the head of the malleus; the short crus is connected with the posterior wall of the tympanum; and the long crus bears the *os orbiculare*, a round bone, about the size of a grain of sand, at its extreme point.

The Stapes or Stirrup possesses a base, two crura, and a head. The base is oval, and placed in the fenestra ovalis; the crura converge from each extremity of the base to a constricted portion termed the neck, on which is placed the head, which articulates with the os orbiculare.

The inner wall of the Tympanum (Pl. XXVII. fig. 8) is very uneven, and presents several eminences and openings. The

val opening, near its upper part, is the *fenestra ovalis*, which eads into the cavity of the vestibule. Above this fenestra, etween it and the roof, is a ridge formed by the aqueduct of allopius, and beneath it is the round opening of the *fenestra otunda*. The latter opening leads into the cochlea, and in the ecent subject is closed by the lining membrane of the cavity. Between the two fenestræ is the projection termed the *pro-montory;* and at the posterior part of the tympanum, numerous penings lead into the *mastoid cells*, which are small, irregular, reely-communicating cavities in the mastoid process of the tem-oral bone. Behind the fenestra ovalis is a conical eminence, he *pyramid*, in the apex of which is a foramen for the tendon f the stapedius muscle. The anterior part of the tympanum arrows towards the opening of two canals, separated from each ther by a lamina of bone—the *processus cochleariformis;* the pper and smaller of these canals contains the tensor tympani uscle, and the other leads into and forms the bony portion of he *Eustachian tube*—a tube partly osseous and partly cartila-inous, which extends from the tympanum to the guttural pouch, nd is the passage through which air is supplied to the middle ar. The Glaserian fissure, opening into the glenoid cavity of he temporal bone, is immediately in front of the ring to which he membrana tympani is inserted.

The bones of the middle ear are united and kept in their ositions by muscles and ligaments. The Muscles are—the *tapedius*, which has its origin in the interior of the pyramid, nd is inserted into the neck of the stapes; the *tensor tympani*, hich arises from the cartilaginous portion of the Eustachian ibe and surface of sphenoid, and, passing through a small anal, becomes inserted into the handle of the malleus; the *axator tympani*, which arises from the sphenoid, and, passing rough an opening in the Glaserian fissure, is inserted into the eck of the malleus; and the *laxator tympani minor*, which ises from the upper margin of the meatus, and is inserted into .e processus brevis and handle of the malleus. The Ligaments

are—the *suspensory*, which attaches the head of the malleus to the upper wall of the tympanum; the *posterior*, which attaches the short crus of the incus to the margin of the mastoid cells; and the *annular*, which attaches the foot of the stapes to the margin of the fenestra ovalis.

The tympanum is lined by a vascular mucous membrane, which is continuous, through the Eustachian tube, with that of the guttural pouch and pharynx, and is reflected into the mastoid cells. The whole of this membrane is lined with epithelium, that in the tube being ciliated. The arteries of the tympanum are derived from the internal maxillary, the internal carotid, and posterior auricular. The veins join the internal jugular.

The Internal ear, from its complexity termed the Labyrinth (Pl. XXVII. fig. 9), is the essential part of the organ of hearing. It consists of two structures—osseous and membranous; the osseous portion being an irregular cavity, divided into three separate parts—the vestibule, semicircular canals, and cochlea.

The Vestibule is an irregular, oval-shaped cavity, situated between the cochlea and the semicircular canals, having the fenestra ovalis penetrating its outer wall, and the five round openings of the semicircular canals at its back. At the upper part of its inner wall are two depressions, the *fovea elliptica* and *fovea hemispherica*, separated by a ridge, the *eminentia pyramidalis*, all of which are pierced by numerous small openings, *macula cribrosa*, for the passage of nervous filaments. Behind the fovea hemispherica is the opening of the *aqueduct of the vestibule*, which extends to the posterior surface of the petrous temporal bone, and gives passage to a process of dura mater and a vein. At the lower and anterior part of the vestibule is the large opening—*apertura scalæ vestibuli*—of the vestibular canal of the cochlea.

The Semicircular Canals are three half-circular passages communicating with the vestibule, into which they open by both extremities, and having, near one extremity of each, a dilatation termed the *ampulla*. These canals are

distinguished as *superior* or *perpendicular*, *posterior* or *oblique*, and *inferior* or *horizontal*. The anterior or dilated end of the superior canal enters the vestibule by a distinct orifice, while its posterior or non-dilated end joins the anterior non-dilated end of the oblique; and the two enter the vestibule by one common opening, the posterior end of the oblique canal being dilated, and entering by a distinct opening. The inferior canal has two openings, of which the anterior is dilated.

The COCHLEA, or SNAIL SHELL, is the anterior division of the labyrinth, and the most complex of the three. It consists of a gradually tapering spiral canal, which takes two and a half turns round a central axis. This axis, termed the *modiolus*, is widest at its base, where it is pierced by numerous small openings, through which pass the filaments of the cochlear branch of the auditory nerve. The spiral canal is divided into two compartments (*scalæ*) by a partition, partly bony and partly membranous, the *lamina spiralis*, which is wound spirally around the modiolus in the direction of the canal, and terminates, at the apex of the cochlea, by a hook-shaped process, the *hamulus*. The two compartments are completely separated, except at the apex, where they communicate by means of an opening—the *helicotrema*—over the hamulus; inferiorly, one scala terminates in the vestibule—it is hence called the scala vestibuli. The other opens into the tympanum at the fenestra rotunda, and is called the scala tympani.

The whole of the bony labyrinth is lined by a thin fibro-serous membrane, which closes the openings of both the fenestra rotunda and fenestra ovalis, and, adhering to the bone, acts the part of a periosteum. The inner surface of this membrane is smooth, and secretes a thin limpid fluid, the *perilymph* or *liquor Cotunnii*, which entirely fills the cochlea, and, in the canals and vestibule, separates the bony from the membranous labyrinth.

The MEMBRANOUS LABYRINTH, though smaller in size, is the exact counterpart in respect to form of the vestibule and semicircular canals, and consists of two sacs within the vestibule,

the larger of which, the *sacculus communis* or *utriculus communis*, is elongated and lodged in the fovea elliptica; the smaller or *sacculus proprius* is round, and lodged in the fovea hemispherica; and the semicircular canals, which are about one third the size of the bony canals, and open by five orifices into the sacculus communis. This labyrinth is filled by a limpid fluid, termed the *endo-lymph* or *liquor Scarpæ*, and is constructed of four coats—an external serous, a vascular, a nervous, and an inner serous, from which the endo-lymph is secreted.

Within each saccule is a small rounded calcareous body, the *oto-conia*, which consist of particles of carbonate and phosphate of lime, held together by animal matter; these oto-coniæ are suspended from the membrane, and float freely in the endo-lymph; oto-coniæ are *soft* otoliths.

The Meatus auditorius internus is a bony canal, which leads from the cranial cavity to the vestibule, and terminates in the cribiform plate of the fovea hemispherica and eminentia pyramidalis.

The Guttural Pouches.—The mucous membrane, after leaving the inferior extremity of the Eustachian tube, becomes dilated into a large pouch (the guttural pouch), *which is peculiar to monodactyles*. These pouches, which meet in the middle line, are irregular in form, are related above with the base of the sphenoid and occipital bones, descend to the lateral sides of the pharynx and larynx, where they terminate in a cul-de-sac, and extend from the inferior extremity of the parotid gland to the anterior face of the atlas. They communicate with the pharynx.

THE EYE, WITH ITS APPENDAGES.

(Pl. XXXI., and description of plate.)

The apparatus of vision comprises the essential organ—the globe of the eye or eyeball—and its accessory parts or appendages.

The Globe of the eye is spherical in form, having the segment of a smaller sphere engrafted upon its anterior surface, and

PLATE XXXI.

THE EYE.

Fig. 1.—Right Orbit opened from the outer side, with Nerves of the Eye.

a a. Optic nerve. *b*. Oculo-motar nerve. *c*. Pathetic nerve. *d*. First division of 5th cranial nerve. *d'*. Lachrymal nerve. *d''*. Frontal nerve. *d'''*. Nasal nerve. *e*. Abducent nerve. *e'*. External rectus muscle. *f*. Inferior palpebral branch of second division of 5th cranial nerve.

Fig. 2.—The Eye-ball, with a Portion of the Sclerotic thrown back, the Choroid seen from the Side.

a. Sclerotic. *b*. Membrana fusca. *c*. Choroid-proper.

Fig. 3.—Eye-ball, with the Retina exposed, seen from the side.

a. Sclerotic. *b*. Membrana fusca. *c*. Choroid coat. *d*. Retina.

Fig. 4.—Anterior Part of the Choroid, seen from the inner side.

a. Pupil. *b*. Ciliary processes.

Fig. 5.—The Crystalline Lens and Vitreous Body after Removal of the Cornea, Iris, and Anterior Part of Sclerotic, seen from the front.

a. Crystalline lens. *b*. Vitreous body.

Fig. 6.—The Eye with the Lachrymal Apparatus, shown on the right side.

a. Lachrymal gland. *b*. Openings of excretory ducts. *c c*. Puncta lachrymalia. *d*. Lachrymal canal. *e*. Its opening into the cavity of the nose. *f*. The caruncle.

increasing its antero-posterior diameter. It consists of a membranous sac, containing certain transparent humours of different density which serve as refracting media, is attached to the orbit by the muscles which execute its movements, and reposes on a cushion of fat, which not only maintains it in its proper position, but also assists in steadying its movements.

The Tunics of the eyeball are three in number—1. The *sclerotic* and *cornea;* 2. The *choroid, iris,* and *ciliary processes;* 3. The *retina* and *zonula of Zinn* (*zonula ciliaris*). The Humours are also three—*aqueous, crystalline* (*lens*), and *vitreous.*

First Tunic.—The sclerotic and cornea form the external tunic, and it is to them that the eyeball owes its peculiar shape. Four-fifths of the globe are invested by the sclerotic, the remaining fifth by the cornea.

The Sclerotic (Pl. XXXI. fig. 2, *a;* fig. 3, *a*) is a dense white fibrous membrane, which extends from the insertion of the optic nerve, with the sheath of which it is continuous, to the cornea. Its external surface is in connection with the cellular and adipose tissue and with the muscles of the eyeball, the tendons of the four recti expanding over it and forming a thin tendinous layer, the *tunica albuginea,* which is partly covered by the conjunctiva, and forms the "white of the eye." Its internal surface is in contact with the choroid coat, from which it receives a stain, and to which it is united by a very delicate cellular tissue and by minute nervous filaments and vascular ramifications. Its anterior opening is elliptical, and presents a bevelled edge, which receives the cornea in a manner similar to that in which a watch-glass is received by the groove in its case. Posteriorly, it is pierced for the passage of the optic and ciliary nerves and ciliary arteries, the optic nerve filaments passing through numerous minute openings in the *cribriform lamella* (*lamina cribrosa*), which it forms, the larger opening in the centre, the *porus opticus,* being for the passage of the arteria centralis retinæ.

The Cornea is transparent, elliptical in shape, and fitted into

the bevelled edge of the sclerotic, to which it is firmly adherent. Its anterior surface is convex, and covered by a continuation of the conjunctiva; and its inner surface concave, and covered by the lining membrane of the anterior chamber of the eyeball.

The cornea is composed of two layers—the *cornea propria* and the *cornea elastica*. The former consists of several thin lamellæ, held together by extremely fine areolar tissue; the latter is a fine, elastic, and exquisitely transparent membrane, closely applied to the inner surface of the propria. It retains its transparency long after the other has become opaque, and, from its great elasticity, its use is supposed to be that of preserving the correct curvature of the flaccid cornea propria.

The proper cornea is continuous with the sclerotic coat, and the elastic with the ciliary ligament.

Second Tunic.—The second tunic of the eyeball is formed by the choroid, iris, ciliary ligament, and ciliary processes.

The Choroid (Pl. XXXI. fig. 2, *c*; fig. 3, *d*; fig. 4) is a thin vascular membrane, of a brownish or black colour. Externally, it is connected to the sclerotic by means of a fine areolar tissue, minute blood-vessels, and nerves; internally, it is in simple contact with the retina; posteriorly, it is pierced for the passage of the optic nerve; and anteriorly, at the junction of the sclerotic and cornea, it is connected to a white circular ring, the *ciliary circle* or *ligament*, which is continuous with the circumference of the iris.

The choroid membrane is composed of three layers—external, middle, and internal. The *external layer* consists principally of veins, *venæ vorticosæ*, arranged in peculiar curves, all of which converge to four or five trunks, which pierce the middle of the sclerotic; the larger branches of the short ciliary arteries mingle with the veins, and the numerous pigment cells, to which the outer colour of the choroid is due, are interspersed among the vessels. This layer is connected with the ciliary ligament. The *middle layer* is formed by the ciliary arteries, which ramify into a fine capillary plexus, the *tunica Ruyschiana*, which is reflected

inwards, and is continuous with the ciliary processes. The *internal* or *pigmentary layer* is composed of laminæ of hexagonal cells, containing black pigment granules, arranged in the form of a tesselated pavement. On the posterior wall, the black pigment is replaced by a peculiar bluish layer of considerable extent, which, owing to its metallic brilliancy, has received the name of *tapetum lucidum*.

The *ciliary ligament* is a white ring of fibres, which forms the bond of union between the external and middle tunics of the eye, and serves to connect the cornea and sclerotic with the external layer of the choroid and with the iris. A minute vascular canal, the *ciliary canal*, exists between this ligament and the sclerotic.

The CILIARY PROCESSES (Pl. XXXI. fig. 4, *b*), from sixty to eighty in number, and arranged in a circle, are formed by the plaiting or folding inwards of the middle and inner layers of the choroid; their circumference is attached to the ciliary ligament, and their central border is received between corresponding foldings of the suspensory ligament of the crystalline lens. The anterior face of these processes is turned towards the back of the iris, and the posterior face closely connected with the zonula of Zinn, through which connection a communication is established between the inner and choroid tunics of the eyeball. Externally, they are covered with a thick layer of pigmentary cells.

The IRIS is a thin diaphragm or curtain, suspended in the aqueous humour immediately in front of the crystalline lens, its periphery being connected with the choroid and ciliary ligaments, and its centre pierced by an elliptical opening, the *pupil*. It is variously coloured, but in the HORSE is brown, with more or less of a yellow tinge; sometimes, however, it is almost white or grey, when the animal is said to be "wall-eyed." Its anterior surface is slightly convex, and its posterior surface covered with a deep purple pigment called the *uvea*, from its resemblance in colour to a ripe grape.

Two sets of fibres enter into the formation of the iris, one of which, converging from the circumference towards the centre,

has the power of dilating the pupil; the other, surrounding the margin of the pupil on its posterior surface, and blending with the radiating fibres, has the power of contracting it.

In the fœtus, the pupil is closed by a delicate transparent vascular membrane—the *membrana pupillaris*—which begins to be absorbed a short time before birth, the absorption commencing at the circumference. At the period of birth, it is nearly entirely removed.

The small bodies situated on the pupillary margin of the iris—three above and three below, the superior being the largest—are the *corpora nigra*, their use appearing to be that of concentrating the rays of light, and preventing their too direct passage through the pupil.

Third Tunic.—The last tunic of the eye is the Retina, which is prolonged forwards to the lens by the ciliary zone. The retina is the terminal expansion of the optic nerve over the internal face of the choroid, from which it is easily separated. It is composed of three layers—external, middle, and internal. The *external layer*, or *Jacob's membrane*, is very thin, and consists of cylindrical and conical cells, arranged side by side in a tessellated manner. The *middle*, or *nervous membrane*, is the expansion of the optic nerve, which forms a thin, semi-transparent layer, thicker behind than in front, which extends forwards, and terminates in a scalloped margin at the ciliary processes. The *inner*, or *vascular layer*, consists of the ramifications of the arteria centralis retinæ and its satellite vein, their branches being continued into the zonula of Zinn.

The Ciliary zone (*Zonula ciliaris*, or *Zonula of Zinn*) is a thin vascular layer, which connects the anterior margin of the retina with the anterior surface of the lens, and presents a number of folds which are received between the corresponding folds of the ciliary processes. The under surface of this zone is in contact with the hyaloid membrane, and is separated from the circumference of the lens by the small space termed the *canal of Petit*.

Humours.—The *aqueous humour* consists chiefly of water, possessing an alkaline reaction, and completely fills the anterior and posterior chambers of the eye. The *anterior chamber* is the space intervening between the internal face of the cornea and the iris, pupil, and ciliary ligament. The *posterior chamber* is the very narrow space bounded, in front, by the iris and pupil, and, behind, by the capsule of the lens and zonula ciliaris. Both chambers are lined by the thin membrane which secretes the aqueous humour.

The *vitreous humour* (Pl. XXXI. fig. 5, *b*) occupies about four-fifths of the whole interior of the globe. It is a highly albuminous, and perfectly transparent fluid, of the thickness of jelly, enclosed in a delicate membrane, the *hyaloid*, from the inner surface of which numerous lamellæ are sent inwards, to form the compartments in which the fluid is contained.

The *crystalline humour*, or *lens* (Pl. XXXI. fig. 5, *a*), is situated immediately behind the pupil, in front of the vitreous humour, and is surrounded by the ciliary processes, which slightly overlap its margin. It is biconvex, the convexity of the posterior face being greatest, and is enveloped by a transparent elastic membrane, the *capsule of the lens*, which is connected to its surface by a layer of transparent cells. After death, these cells absorb fluid from the eye, and break down into the *liquor Morgagni*. The lens is constructed of concentric layers or laminæ, of which the external are the softest and the internal the hardest. It is supported in its place by the ciliary zone.

Muscles of the Eye.

The intrinsic or motor muscles of the globe of the eye are eight, five of which are the straight muscles, viz., the posterior or retractor, the superior or levator, the inferior or depressor, the external or abductor, and the internal or adductor; the remaining three being the oblique muscles, distinguished as superior, middle, and inferior.

The Rectus oculi posterior, or Retractor oculi, completely envelopes and forms a sheath round the extra cranial portion of the optic nerve. It originates from the edge of the optic foramen, and is inserted into the posterior part of the external face of the sclerotic, its action being to retract the eye within the orbit.

The remaining four Recti muscles have their origin round the margin of the optic foramen, within the orbit, and become inserted by a broad expansion, which forms the tunica albuginea, on the anterior portion of the sclerotic. These four muscles form a fleshy sheath round the eyeball, similar to that which the retractor forms round the optic nerve. They are all flat and ovoid in form, the narrowest part being at their origin. Acting together, they retract the eyeball: singly, the superior rectus turns the eye upwards; the inferior turns it downwards; the internal turns it inwards; and the external turns it outwards.

The Superior Oblique muscle is situated at the side of the internal and superior recti. It arises from the base of the orbit, and is directed forwards against the internal wall of the cavity, passing through a cartilaginous loop at the base of the orbital process of the frontal in the inner canthus, from which point it is directed backwards and under the terminal extremity of the superior rectus, to become inserted into the sclerotic, between the superior and external recti. The action of this muscle is to elevate and rotate the eyeball.

The Inferior or Lesser Oblique arises from the lachrymal fossa, is carried obliquely outwards, and is inserted into the sclerotic between the external and inferior recti muscles. Its action being to depress and turn the eye inwards, is antagonistic to the superior oblique.

The Middle Oblique originates by a delicate tendon, from a minute depression in the superior part of the orbital plate of the frontal bone, midway between the origin of the inferior oblique and the loop through which the belly of the superior oblique passes. From this point it runs obliquely upwards and out-

wards by the side of the external rectus, and blends its tendon of insertion with that of the superior oblique. The action of this muscle is accessory to the superior oblique, and, at the same time, to prevent the belly of that muscle becoming fixed in the loop through which it has to pass at such an acute angle. (*Vide* APPENDIX.)

APPENDAGES OF THE EYE.

The accessory parts or appendages of the eye, are the *eyebrows*, *eyelids*, *membrana nictitans*, *conjunctiva*, *carnucula lachrymalis*, and *lachrymal apparatus*.

The EYEBROWS, very rudimentary in the HORSE, are the eminences formed by the orbital processes of the frontal bone. They are furnished with a few long hairs, and serve to interrupt the too vivid rays of light, and prevent foreign bodies from descending into the eyes.

The EYELIDS are the two movable curtains—superior and inferior—which protect the eye. Both are capable of expansion and contraction, though the inferior is the larger, and more movable of the two. When drawn apart, they form an elliptical opening, the angles of which are termed canthi. The outer canthus, or temporal angle, is very acute; the inner canthus, or nasal angle, is very obtuse or rounded, and contains the caruncula lachrymalis. The external surface of the eyelids is covered with fine short hairs; the internal surface is smooth, is lined by the conjunctiva, and is in contact with the globe of the eye. Their free borders are thick, having the tarsal cartilages for their base, and on their margins rows of long hairs—the *eyelashes*—which serve to prevent the intrusion of insects. The ciliary borders of the lids also present a series of minute openings, which are the *ducts of the Meibomian glands*. Entering into the structure of the eyelids, are skin muscles, fibrous tissue, tarsal cartilage, Meibomian glands, and conjunctiva. The skin covering the eyelids is very fine, and adheres intimately to the levator palpabræ and orbicularis palpebrarum

muscles. The fibrous tissue, thickest in the inferior eyelid, is firmly attached by its adherent border to the periosteum of the orbit and the bone under the eyebrow, and by its free border to the tarsal cartilages, hence it is sometimes termed the tarsal ligament. The *tarsal cartilages* are the two cartilaginous plates which form the solid framework of the free border of the eyelids. They are elongated, narrowest at their extremities, and thin on their attached borders, which are continuous with the fibrous membrane. These cartilages afford a firm and very pliant support to the eyelids, and present on the side next the globe of the eye a series of vertical furrows, which lodge the ciliary follicles. The tarsal cartilage of the superior lid is longer and thicker than that of the inferior.

The Ciliary Follicles, or Meibomian Glands, are situated between the tarsal cartilages and the conjunctiva. Each gland consists of a single tube, into which a cluster of follicles opens, and the whole row of glands along the edge of the cartilage bears a strong resemblance to a string of pearls. These glands secrete a sebaceous fluid, which prevents the eyelids gluing together during sleep.

The Conjunctiva, the mucous membrane of the eye, is very thin and very vascular, its vascularity being greatest on the inner surface of the lids, and least on the cornea, where no vessels are traceable in health. It lines the entire inner surface of the eyelids, being continuous with the skin on their edges, covers the anterior part of the membrana nictitans, passes down the nasal duct to join the mucous lining of the nasal fossa, and is reflected over the whole of the anterior portion of the globe; adhering very loosely to the sclerotic and aponeurotic expansion of the recti muscles, and very firmly to the cornea, where it is extremely delicate.

The Membrana nictitans, or accessory eyelid, vulgarly the "haw of the eye," is situated in the nasal angle, between the globe and the side of the orbit. It is composed of fibro-cartilage, and is irregular in form, being thick and somewhat prismatic at

s base, and thin anteriorly, where it is covered by a fold of onjunctiva. Posteriorly, it is continuous with the pad of fat hich is insinuated between all the muscles of the eye. Its xternal surface is convex, and its internal concave. When the ye is in its natural position, the margin of the membrana nic-tans, covered by conjunctiva, is only to be perceived, the rest eing buried in the ocular sheath; but when, by the contraction f the straight muscles, the globe presses upon the pad of fat, ne membrane is forced out, and covers more or less of the ransparent cornea. This movement, which is instantaneous, is or the purpose of removing any offending agent from the sur-ace of the eye. In some diseases, as tetanus, this membrane is orced outwards, and remains so. It is smaller in the horse han in the Ox, in which animal, as well as in the Pig, the *land of Harden* is associated with it in the angle of the eye. his gland secretes a thick, whitish humour, which is poured ut through two openings under the cartilage, the use of this uid being to favour the movements over the eye.

The Caruncula lachrymalis (Pl. XXXI. fig. 6, *f*) is the mall round body, of a reddish colour, seen in the inner can-hus. It consists of a number of follicles, and the bulbs of soft, ne hairs. Its use is to direct the tears towards the puncta achrymalis.

Lachrymal Apparatus.

The lachrymal apparatus consists of the lachrymal gland, achrymal canals, lachrymal sac, and nasal duct.

The Lachrymal gland (Pl. XXXI. fig. 6, *a*), situated between he orbital process and the superior straight muscle, is convex uperiorly, concave inferiorly, thickest and broadest anteriorly, nd thinnest and narrowest posteriorly. It belongs to the class f conglomerate glands; is of a pale yellow colour; and consists f numerous lobules, which are composed of granules held ogether by cellular tissue. The secretion, which constitutes ne tears destined to lubricate the anterior surface of the eye,

escapes through numerous straight ducts which open on the upper surface of the conjunctiva towards the inner face of the outer canthus, is carried between the lids and the globe towards the inner canthus, and enters two small holes, *puncta lachrymalia* (Pl. XXXI. fig. 6, *c*, *c*), one on each side of the caruncula lachrymalis. These puncta lachrymalia are the openings of the minute *lachrymal canals*, which are formed in the substance of the eyelids, and are lined by a continuation of the conjunctiva; the superior, being the longer, on entering the lachrymal sac, a little behind the inferior.

The Lachrymal sac is a small reservoir lodged in a fossa in the lachrymal bone, and is the entrance of the lachrymal duct.

The Lachrymal duct (Pl. XXXI. fig. 6, *d*) (ductus ad nasum) is a long membranous canal, which begins at the sac, descends a conduit in the bone, and terminates on the internal face of the nasal opening, near to and a little above the inferior commissure of the ala. It is lined by a continuation of the conjunctiva, which also lines the lachrymal conduits and lachrymal sac, describes numerous flexures after leaving the bone, and sometimes terminates in two openings.

THE SKIN AND ITS APPENDAGES.

It consists of two parts, the dermis, cutis vera or corium, and the epidermis or cuticle.

The Epidermis, cuticle, or scarf skin, is an epithelial structure, forming a protective covering to the corium. It varies in thickness, is quite insensible and non-vascular, and consists of agglutinated cells which are formed in the liquor sanguinis, and poured out on the surface of the true skin; they contain nuclei, vary in form, the deep layers being columnar, those above rounded, flat on the free surface, finally dry, desquamating membranous scales. They also change in physical and chemical constitution, the deep ones being soft and opaque, the superficial dry, horny, and soluble in acetic acid. Their fluid portion,

ıow pressed out, serves to cement them together. The epider-
nis is divided into a firm and transparent superficial and a deep
oft layer. The latter is the *rete mucosum*, in whose cells the pig-
nent exists which gives colour to the skin. The deep surface of
he epidermis is accurately moulded on the papillary layer of the
rue skin, and, when removed by maceration, presents depres-
ions, which correspond to the elevations on the dermis; from
he cuticle, tubular prolongations pass into the sebaceous and
udorific glands. The outer surface is marked by a net-work of
arrows, the deep ones forming lozenge-shaped spaces.

The Dermis is vascular and highly sensitive, being the seat
f touch. It is covered by epidermis, and attached to the under-
ying parts by a layer of areolar tissue, which usually contains
it, hence called *panniculus adiposus*. The cutis consists of
bro-areolar tissue and vessels of supply. It is divided into two
ayers, the *deep* or *true corium* and the *upper* or *papillary*. The
orium consists of strong interlacing fibrous bands, chiefly white;
ts meshes are larger, and more open towards the attached sur-
ace, giving lodgment to the sweat-glands and fat. The papil-
ary or superficial layer is formed of a series of small conical
minences or papillæ, which are highly sensitive, and consist of
homogeneous transparent tissue. The blood-vessels form dense
apillary plexuses in the corium, terminating by loops in the
apillæ. The papillary nerves run in a waving manner, usually
erminating in loops.

Hair is an appendage of the skin, and forms its external
overing. It is a special modification of epidermis, having the
me essential structure. It consists of a root, shaft, and
oint. The root has a bulbous enlargement at its extremity, is
ghter and softer than the stem, and lodged in a recess or hair
llicle, which may either be in the corium or subcutaneous
eolæ. The follicle is dilated at the bottom to correspond with
e root bulb, and the ducts of one or more sebaceous glands
en into it. It consists of two coats—an *outer* or *dermic*, an
ner or *cuticular*. The outer, composed of areolar tissue, is

highly vascular, continuous with the corium, and possesses numerous minute nervous fibrils; the inner, continuous with the cuticle, is attached at the base of the follicle to the root of the hair. The lining adheres to a hair when plucked out, forming the root sheath. At the bottom of each follicle is a conical vascular papilla, similar in every respect to those on the surface of the skin. This papilla fits into a corresponding depression in the root of the hair. The shaft consists of a centre or medulla, a surrounding fibrous portion, and an external coating or cortex. The medulla consists of cells containing pigment or fat, is opaque, and deeply coloured. All hair has not this medulla. The fibrous portion occupies the bulk of the stem, and is composed of elongated cells, which form fusiform fibres. The cortex is merely a single layer of thin flat imbricated scales.

The Glands of the skin are the *sebaceous* and *sudoriferous*.

The Sebaceous, lodged in the corium, are most abundant in parts exposed to friction. They generally open into the hair follicles, occasionally on the surface of the body. Each gland consists of a small duct, which terminates in a lobulated recess. These lobules vary, and are, as is the duct, lined with epithelium. They are filled with sebaceous matter, which, as it grows, is detached into the sacs. They are very plentiful between the digits of cattle.

The Sudoriferous or sweat glands are situated in the subcutaneous areolar tissue, surrounded by a quantity of fat. They are small, round reddish bodies, each of which consists of one or more fine tubes coiled into a ball, the free end of the tube being continued up through the true skin and cuticle, and opening on the surface by a funnel-shaped orifice. Sometimes there are two apparent ducts, which unite at a short distance from the glands. The ducts are slightly curved as they pass through the corium. Where the scarf skin is thick, they assume a cork-screw appearance; where it is thin, they open directly out. They consist of two coats—an outer, continuous with the corium, and an inner epithelium one, which is continued to the surface. Each sweat-

HOOF

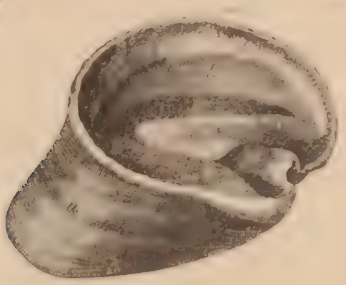



PLATE XXXII.

THE HOOF.

Fig. 1.—Right Forefoot of Horse, with the Hoof-cartilages.

1. Hoof-cartilage. *a*. The outer surface. *b*. Anterior end. *c*. Posterior end. *d*. Upper border. *e*. Lower border.

Fig. 2.—Fleshy Parts of Hoof—Lateral View.

a. Coronary band. *b*. Sensitive laminæ.

Fig. 3.—Horny Hoof—Plantar Aspect.

a a. Bars. *b*. Solar border of hoof. *c c*. White line. *d*. Under surface of sole. *d' d'*. Points of sole. *e*. Cleft of frog. *e' e'*. Sides of frog. *f*. Posterior end of side. *g*. Anterior end of side.

Fig. 4.—Fleshy Parts of Hoof—Plantar Aspect.

a. Fleshy sole. *b*. Fleshy frog.

Fig. 5.—Horny Hoof, viewed lateraly from above.

a. Outer surface of hoof. *b*. Its inner surface. *c*. Coronary border. *d*. Groove on coronary border. *e*. Upper surface of horny sole. *f*. Upper surface of frog. *f'*. Central elevation of frog (frogstay).

Fig. 6.—The Sole which fils up the Interval between the Inferior Borders of the Walls of the Hoof.

Fig. 7.—Shows the Anterior Normal Angle of Inclination of a well-proportioned Hoof. It is about 45°.

Fig. 8.—Lateral View of Frog and Frog-band.

Fig. 9.—Solar View of Frog and Frog-band.

gland is supplied with a cluster of capillary blood-vessels. Their size vary, being very large where perspiration is excessive. The contents of the smaller are quite fluid, of the larger semifluid, with fine granules and nuclei.

THE FOOT OF THE HORSE.

(Pl. XXXII. and description of plate.)

The study of the foot of the horse is of the greatest importance, owing to the many diseases and injuries to which it is liable. It naturally resolves itself into the consideration of the hoof or horny box, and the parts contained within it.

The Hoof of the horse, which varies considerably in colour, represents a sort of horny box, enveloping the inferior extremity of the digit, applied in an exact manner to, and united most intimately with, the sensible plates or laminæ which clothe the os pedis, this union being by reciprocal depressions and elevations of the two surfaces, which fit into or dovetail with each other. The general form of the hoof is the section of a cylinder which has been mesially truncated or cut obliquely across the section, representing the base of the hoof (Pl. XXXII. fig. 3). Viewed casually, it presents an appearance somewhat conical.

By maceration, the hoof is divided into three distinct parts—*wall, sole,* and *frog.*

The Wall or crust is that part which is visible when the hoof rests on the ground, and is generally divided into the toe or fence, quarters, heels, bars, internal and external surfaces, and superior and inferior borders. The *toe* forms the front of the hoof, and is the deepest as well as the thickest part of the wall, which gradually declines in height as it passes backwards to form the *quarters.* These occupy the space between the toe and heels. The wall decreases in thickness from before backwards, more markedly so at the inner surface. It also apparently decreases in obliquity; but on careful examination, it is found that the fibres of the quarters have the same degree of obliquity as those

of the toe. At the posterior part of the foot, the walls take a sudden bend, forming an acute angle, and are continued inwards to the centre of the foot, where they unite with the sole. The angles of inflection are called the *heels*, the inflections themselves the *bars* (Pl. XXX. fig. 3, *a*, *a*), these latter forming stays to the quarters. The *external surface* of the wall is convex, smooth, and covered by a thin epidermis, which conserves the moisture of the wall beneath, and is continued above with the coronary frog band. The *internal surface* of the wall presents throughout its whole extent white parallel perpendicular plates or processes of horns, which extend from the coronary border to the sole, and are continued over the inner surface of the bars. These insensible or horny laminæ vary from 500 to 600 in number, and are separated from each other by deep fissures, in which are inserted the sensible laminæ. In the recent subject, these laminæ are soft, elastic, and consist of two layers of fibres—one running parallel with themselves, the others obliquely intersecting them. The *superior* or *coronary border* of the wall presents an excavation or groove, which slopes somewhat obliquely downwards and inwards, forming a circular gutter, in which is lodged the coronary ligament. In this groove are numerous minute orifices, into which are inserted the secretory villi of the coronary ligament. The *inferior border* is that part in contact with the ground to which the shoe is fitted. In an unshod animal, it is always in wear, and protrudes beyond the rest, more especially round the outer quarter, and is known as the *spread*. The inner surface of inferior border is united in a very intimate manner with the periphery of the sole.

The Sole (Pl. XXXII. figs. 3, 4, and 6) is a thick plate of horn, which occupies the inferior surface of the hoof. It is comprised between the inner border of the inferior part of the wall and the inflections or bars, and presents two surfaces and two borders. The *inferior* or *external surface* forms a vault, which is more or less concave in different animals. The *superior* or *internal surface* is unevenly convex, and is studded

with a number of small orifices, which run obliquely forwards. Into these are inserted the vascular papillæ of the sensible sole. The *external border* or circumference of the sole is convex, abuts upon, and is united throughout its whole extent to the internal part of the inferior border of the wall, the union between the two being very intimate, through the intervention of horny matter. The inner border represents a deep cut or notch in the form of the letter V, and is related to the bars, excepting at the narrow part, where it is bounded by the frog. The two angles uniting the outer and inner circumferences correspond to the heels, and are received between the outer walls and bars. It is this part of the sole which is most liable to injuries, especially to bruises or corns.

The Frog (Pl. XXXII. figs. 4, 5, 7, and 8) is the prominent, somewhat pyramidal mass of spongy horn, lodged between the bars, and filling up the triangular space. It has four surfaces, a base, and an apex. The *inferior* or *external surface* is very irregular, and presents a longitudinal triangular cavity, which varies in breadth and depth, *being broadest and deepest in well-formed feet.* This cavity is the *cleft* of the frog (Pl. XXXII. fig. 2, *e*), bounding which are two sloping projections or branches, which unite at the apex of the frog anteriorly, and diverge posteriorly, where they join the heels. The *superior* or *internal surface* is also very irregular, but exactly the reverse of the inferior; where the one is hollow the other has a projection, and *vice versa.* It presents over its whole surface numerous small foramina, into which are inserted the vascular or secreting papillæ of the fatty frog, likewise a triangular excavation, which is divided posteriorly into two lateral gutters by a long projection or elevation, corresponding to the cleft or outer surface. This somewhat conical eminence is called the *frog stay* (Pl. XXXII. fig. 5, *f*), and serves to establish a firm union between the frog and fatty frog. The *lateral surfaces* have a direction obliquely from above downwards, and from without inwards. In their upper third they are firmly united to the external surface of the

bars, and anteriorly, to the notch in sole. Between the inferior part of the lateral surfaces of the bars and the frog are deep triangular hollows, called the *commissures* of the frog. The base or exterior extremity constitutes the *heels* or *bulbs* of the frog. These are two round flexible and elastic eminences, formed by the extremity of the two, and separated by the cleft. They cover the angles of inflection of the walls, and are continued round the external part of the superior surface of the wall in the form of a *white band* (Pl. XXXII. fig. 3, *c*, *c*), which constitutes the *coronary frog band*. The use of this band is to unite the solid hoof with the skin. It is from the inferior border that the thin covering of the hoof is continued. The *summit* or *toe of the frog* is the anterior pointed portion, which is inserted into the narrow part of the notch in the sole.

The Horn of the hoof (Pl. XXXII. fig. 5) presents a fibrous appearance, very distinct in the wall, less so in the deep-seated parts of the sole and frog, and scarcely traceable in the superficies of the sole, where there is a continual disintegration or separation of the horns in layers more or less extensive. It consists of minute cylindrical *tubes* or *fibres*, which commence and are secreted from the villi or papillæ in the coronary ligament. These tubes have a direction obliquely downwards and forwards, and are arranged in parallel rows, forming concentric layers, placed one over the other, and lamellæ or plates, interposed transversely, united together by an amphorus or inter-tubular substance. The *lamellæ* consist of thin, pale, and generally oblong epithelial scales, the external being more compact than the internal. They also contain a white opaque substance, which is not uniformly disposed throughout the tube, but in a bead-like manner. Independent of these fibres, plates, and amphorous inter-tubular substance, there is always more or less *pigmentary matter*, which consists of colour-cells distributed amongst the concentric plates or layers forming the walls. The horny fibres of the sole have the same obliquity as those of the walls, are secreted from the villi on the sensitive sole, and

finally united to the wall round the outer circumference, they receive a few villi from the interior extremity of each sensible lamina.

The HORN OF THE FROG differs considerably from that of both wall and sole. The tubes are much finer and softer, and have a flexuous arrangement. They are united to those of the walls at the base, and are secreted from the papillæ on the surface of the sensible frog. The fibres of the coronary frog-band are very fine, and are continued by a layer of epithelial cells, which cover the external surface of the hoof. *Horn* is tough, elastic, flexible, and admirably adapted for protecting delicate parts. It is secreted in the form of cells, which become elongated. The *colour of the hoof* varies, but it generally corresponds with that of the skin of lower extremity. It is an acknowledged fact, that white hoofs, like white skin, are more delicate, porous, and prone to disease than dark ones.

The *parts contained within the hoof* are the os pedis, os naviculare, the distal extremity of os coronæ, the ligaments by which these are connected together, the insertions of extensor and flexor perforans tendons, and vessels and nerves. There are also certain structures proper to the foot, viz., the lateral cartilages, fatty frog, coronary ligament, sensitive laminæ, and sensitive sole.

The LATERAL CARTILAGES (Pl. XXXII. fig. 1) are two thin plates of fibro-cartilage, of an irregular quadrangular form, which surmount the wings of the coffin bones. Each represents two surfaces and four borders. The external surface is convex, the internal one concave, presenting numerous vascular grooves, and is continuous postero-interiorly with the fatty frog. The superior border is thin, generally convex, and pierced by several foramina for vessels to pass to the frog; the interior border is attached to the wings of os pedis posteriorly, it is inflected inwards, and is continuous with the interior surface of the fatty frog; the posterior border is slightly convex, and has a direction obliquely downwards and backwards, joining the superior and inferior borders,

being separated from the former by an obtuse angle; the anterior border, also directed obliquely downwards and backwards, becomes intimately blended with the anterior lateral ligament of the coffin joint. The anterior borders of the two lateral cartilages are united by fibrous expansions from the extensor tendon and the anterior lateral ligament of the coffin joint.

The Fatty or Sensitive frog occupies the posterior and central parts of the foot, filling up the irregular space between the lateral cartilage, flexor tendon, and os pedis. Bounded laterally by the cartilages; superiorly, by the perforans tendon and common integument; infero-externally, by the horny frog; it is continuous with the sensitive bars, the sole, and coronary ligament. Like the horny frog, it presents two surfaces, two lateral borders, a base, and an apex. The supero-anterior surface is related with, and attached to the flexor tendon, the ligament of the navicular joint, and the ala of the os pedis; the infero-posterior surface is covered by villi, from which the horny frog is secreted. In its centre, is a deep cavity for the insertion of the frog stay. The base looks backwards, and is divided into two bulbous enlargements, which are united to the lateral cartilages. The summit looks forwards, and is attached to the plantar surface of the os pedis in front of the semilunar ridge. The lateral surfaces correspond to the commissures of the frog, and are continuous with the inner surface of the lateral cartilage. The *fatty frog* is made up of an external layer of cuticular structure, the villi of which secrete the horny frog; below this, is a layer of capillary blood-vessels; its base is made up of fibro-cartilage intermixed with an interstitial yellow fibro-cellular tissue of a peculiar elastic nature, which used to be described as fat.

The Coronary ligament (Pl. XXXII. fig. 2, *a*) or coronary substance, is that vascular structure which occupies the concavity on the superior border of the walls. It consists of a fibro-cartilaginous band, which connects it to the coffin bone and extensor tendons through the medium of dense cellular tissue. Reposing on this is a plexus of blood-vessels, which is covered by a con-

tinuation of the true skin, on which are numerous villi, which enter the funnel-shaped openings of the tubules of the walls.

The SENSITIVE LAMINÆ (Pl. XXXII. fig. 2, *b*) are the continuation of the coronary substance, and are attached to the coffin bone by a dense fibrous membrane, in which ramifies the vascular plexus emanating from the bone. These highly organised plates are interposed between, and firmly attached to, the horny laminæ on the wall, and are covered by minute papillæ, which secrete the horny laminæ. They are the seat of the tactile sensibility of the foot; on their inferior extremity are five or six villi which help to secrete the sensible sole.

The SENSIBLE SOLE is firmly attached to the coffin bone; like the sensible laminæ, it is made up of an elastic fibro-vascular membrane, clothed by a continuation of the corium, which is covered by the villi. The villi secrete the horny sole.

APPENDIX.

No. I.

DISSECTIONS.

Compiled from "Traité d'Anatomie Comparée des Animaux Domestiques par A. Chavaux, chef des travaux anatomiques à l'Ecole impériale vétérinaire de Lyon." Paris, 1857.

I. DISSECTION OF THE ARTICULATIONS AND LIGAMENTS.

1. In order to prepare the articulations, the student should select young, in preference to subjects advanced in age, because in the former the density of the cellular tissue is less than in the latter. As the ligaments are prepared with difficulty when their external surface is dried up, care should be taken to keep them protected from the air until the time to dissect them, by covering them with wet linen rags, or with the hide of the animal.

2. It is convenient to separate the articulation which one wishes to study, by cutting the bone a certain distance from the articulatory surfaces. The handling of the piece is thus more easy, and the dissection is made in the most favourable conditions.

3. It is important, as much as possible, to take care of the muscles which surround the articulations, so as to be able to study their connections with the ligaments which are related to the joints. If it is absolutely necessary to take away the muscles, all the corresponding insertions should be preserved.

4. Study first the capsular ligaments, and then remove them so as to display the fascicular bands. The latter, in their turn, are to be

sacrificed so as to expose, by means of different sections, the inter-osseous cords, if any exist. Separate at last, in a complete manner, the two articular surfaces, laying them bare, and then examine their conformation.

5. The synovial membranes, with their different *cul-de-sacs*, being a very important subject of study with reference to the diagnosis and treatment of articular tumours, the student is recommended to preserve a special piece or preparation for the study of these serous membranes. He may also very easily inject their interior with plaster or with tallow, coloured black, so as to distend their *cul-de-sacs*, and favour the study of the connections which they make with the ligaments, tendons, or muscles.

II. DISSECTION OF THE MUSCLES.

1. General directions as to the Choice of a Subject, and Method of Dissection, etc.

If a number of subjects are at the disposal of the student, so that he has it in his power to make a choice, he should give the preference to those in which the muscular system is best developed, avoiding enormously fat animals. Subjects of small or middle size are always more convenient than those having great masses of muscle and fat. Asses and mules, when they are very lean, show the muscular system very distinctly.

Position of the Subject.—It is important to place the subject, immediately after death, in a convenient position, as cadaveric rigidity preserves it. Without this precaution, the different parts of the body of the animal may take an inconvenient attitude, and all attempts to rectify the position will be powerless, especially in animals of great size.

The subject may be placed in three different positions :—

1. The animal is placed in the *first position* when it is laid upon its back, and the four extremities are raised in the air, and supported by means of cords or ropes fixed to the pastern, and passed through movable rings, which are fixed to the extremity of four upright bars or posts at the corners of the table upon which the animal is laid. The head passes over the end of the table, and rests upon a stool, on a lower level, so that the neck may not be twisted.

2. To place the animal in the *second position*, it is turned upon its

belly, the two thighs flexed, the extremities extended upon the table, and the head supported between two upright bars, by means of a rope passed under the jaw.

3. The subject is said to be in the *third position* when it reposes on its side.

2. Rules to be observed during the Dissection.

1. As far as possible the skin should not be removed, except from those regions which are to be dissected at the time. If it can be done, the student should take the precaution of wrapping up the parts with cloths wet with the blood of the animal, to prevent the drying up of the aponeurosis and the superficial muscles.

2. To dissect a muscle, raise the aponeurosis, or the other muscles which cover it, and dissect off the cellular tissue which enwraps it, the fat, the ganglia, and the vessels and nerves lodged in the interstices. Dissect the aponeurosis in strips, seizing them firmly with the forceps, and make the scalpel glide between the fibrous and muscular surfaces, holding the blade always parallel to the surfaces. The muscles covering it ought to be entirely cut away, by being divided near the middle, across their fibres, the two ends reflected to the side, and the study of their attachments is thus more easily made. Remove the cellular tissue by lifting it with a pair of forceps, and carrying the edge of the scalpel in the angle formed by the cellular tissue and the surface of the muscle. This proceeding may also be convenient in removing aponeuroses, when they adhere feebly to the muscular fibres. For removing fat, ganglia, &c., scissors may be used with great advantage.

Order in which to dissect all the muscles upon the same subject.

1. First of all, place the subject in the first position, and commence the study of the muscles of the inferior abdominal region. Then cut off these muscles, the one extremity from the sternal attachments, the other from the prepubial tendon and crural arch. The cavity of the abdomen and viscera will thus be displayed; and the student should then prepare for the consecutive study of the diaphragm, internal crural region, the deep muscles, the sublumbar region, the patella region, and the posterior crural region, as also the superficial muscles of the inferior cervical region and the pectoral region.

2. After having detached and laid aside the fore limbs for dissection at another time, turn the animal over and place it in the second position. Dissect by turns the muscles of the ears, those of the superior cervical region, the region of the croup, the costal region, and the spinal region of the back and the loins.

3. The regions of the fore limb may be prepared at the same time, or immediately thereafter.

4. Afterwards, separate the two hind limbs by sawing the femurs through the middle, and then proceed to the dissection of the muscles of the leg and hind foot.

5. By means of another cut of the saw carried through the middle of the loins, isolate completely the pelvis, to make a dissection of the coccygeal muscles and the deep muscles of the internal crural region.

6. The animal having been turned upon its side, open the cavity of the chest and saw the ribs near their extremities, thus procuring two special pieces which should be carefully studied,—the one containing the triangularis sterni, the other, the deep muscles of the inferior cervical region, that is to say, the long muscles of the neck, and the right anterior and right lateral muscles of the head.

7. Before disarticulating the head, dissect the last or deep origin of the muscles of this region. The subject may afterwards serve for the study of nearly all the joints.

3. Special Dissections of Muscles.

Panniculus carnosus.—Place the animal upon its side, and dissect off the skin from the lateral parts of the trunk, taking care that no muscular fibres are raised along with it.

Superior Cervical Region.—Place the subject in the second position, and dissect successively the four layers of the region. In order to study the first layer, formed by a single muscle,—the cervical trapezius,—raise the skin, the cellular tissue and the fibrous fascia, which cover the muscle. The preparation and study of the second layer, composed of the rhomboideus longus and the splenius, may be made in two ways. The first is to reflect the trapezium and the levator humeri, preserving only the cervical insertions of this last muscle; then remove the fore limb, sawing through the shoulder beneath the insertion of the serratus magnus muscle. But if only the cervical and dorsal insertions of the splenius are shown, then proceed to the second part of the

operation, which is to raise the rhomboideus, the levator humeri, and upper extremity of the shoulder. To prepare afterwards the third layer, which comprises the complexus major and complexus minor, it is sufficient to cut the splenius, following the direction of the chest, and turning back the two flaps of the muscle. Finally, display the deep layer, which is composed of the spinalis colli, the intertransversales colli, the obliquus capitis inferioris et superioris, and the rectus capitis posticus major and minor, as also the cervical ligament, by raising the complexus major and minor muscles and the longissimus dorsi.

Inferior Cervical Region.—1. Place the animal in the first position. 2. Remove the integument from the region, so as to demonstrate and study the panniculus. 3. Raise this muscle with the parotid gland, in order to show the levator humeri, the sterno-maxillary, the sterno-hyoid, and the sterno-thyroid. 4. Cut transversely the levator humeri, near the angle of the shoulder, and isolate and demonstrate the omo-hyoid; preserve the jugular vein and the parotid gland, so as to study their attachments with it. 5. Remove the two fore limbs; open the thoracic cavity, sawing through the first eight ribs, near their superior extremity; remove the viscera contained in this cavity, also the trachea, œsophagus, pharynx, and the larynx, and thus lay bare the longus colli, the rectus capitis anticus major and minor, and the scaleni.

Spinal Region of the Back and Loins.—1. Place the animal in the second position. 2. Raise the skin, with the panniculus and the mass of olecranon muscles, to prepare, by a first operation, the trapezium and latissimus dorsi. 3. In the second place, expose the rhomboideus by cutting the trapezium and a portion of the aponeurosis of the latissimus dorsi. 4. In a third operation, remove the entire forelimbs, along with the last-named muscle, so as to study its attachments; then dissect the serratus parvus posticus and serratus parvus anticus. 5. Raise these two muscles, as well as the trachelo-mastoideus and the splenius, to lay bare the common intercostal and longissimus dorsi. The superior part of the latter being concealed by the complexus major, cut this muscle, preserving only its insertions into the transverse processes of the dorsal vertebræ, so as to see how they are enclosed between the two divisions of the longissimus dorsi. Finally, dissect the spinalis dorsi and the semi-spinalis dorsi, sawing through and reflecting the angle of the ilium.

Sublumbar and Inferior Lumbar Region.—1. Place the subject

in the first position; open the abdominal cavity, removing completely the inferior walls; examine this cavity and the viscera it contains, and proceed to remove the diaphragm so as to expose the anterior parts of the psoæ muscles. 2. Study, in the first place, the iliac fascia, its form, relations with the adductor longus, its attachments, its continuity with the tendon of the psoas parvus, and the reflection of the aponeurosis of the great oblique of the abdomen. 3. Expose the three psoæ by raising the iliac fascia, the sartorius, the gracilis, and the rectus. 4. Raise the psoæ in order to dissect the semi-spinalis dorsi, and the intertransversales lumborum.

Muscles of the Head.

Labial Region.—Raise with the scissors the skin which covers the two portions of the labial muscle; then remove the lip to show its internal surface, dissecting the buccal mucous membrane and the glands lying under it.

Buccinator Region.—Separate the masseter; dissect the external surface of the muscle, removing carefully the risorius and zygomaticus, which are conjoined with it; then split it down the middle, parting the commissure of the lips; flatten each strip backwards upon the jaws, raise the buccal mucous membrane, and study the internal surface of the muscle along with its attachments to the superficial plane of the maxillary bone.

Masseteric and Temporo-maxillary Region.—1. In the first place, study the digastric and its stylo-maxillary portion, and the pterygoideus internus. 2. Lay bare the pterygoideus externus, raising upon this same preparation the hyoid bone and its attachments so as to point out the two preceding muscles. 3. To prepare the temple, remove the pterygoideus externus, proceeding along its inferior border, an operation which shows the orbital fascia of the temple; then reflect the piece, divide the orbital arch by two cuts of the saw, or by the aid of the hoof-parer, and raise the eye along with the auricular muscles. 4. Dissect the masseter, removing from its external surface the panniculus, and the vessels and nerves which cover it.

Hyoid Region.—1. Separate the head from the trunk, raising the muscles of the cheeks on one side along with the parotid gland. 2.

The ramus of the inferior maxilla being thus exposed, cut it into two parts; immediately behind the last, and before the first molar. 3. Before demonstrating separately the pterygoidei and the upper portion of the stylo-maxillary—that is to say, the part which rests upon the condyle and the coronoid process—remove them where they antagonise each other posteriorly; afterwards cut away the pterygoidei and the digastricus. 4. Turn back the lower fragment of the ramus, that is to say, the portion which carries the molars, isolating the mylo-hyoid and the buccal mucous membrane. 5. Raise the tongue, separating carefully the genio-hyoidei, the anterior cornu of the body of the hyoid bone, the transverse muscle, and kerato-hyoideus parvus.

Muscles of the Axillary, Costal, and Abdominal Regions.

Axillary Region.—1. Place the animal in the first position. 2. Detach one of the fore limbs. 3. Skin the region carefully, and dissect, the other limbs being relaxed, the pectoralis anticus et transversus. 4. Prepare the pectoralis magnus upon the opposite side. To do this, raise the panniculus carnosus, taking the precaution not to cut the substance of the muscle to be examined; cut transversely the pectoralis anticus and transversus, reflecting the two portions to the right side and to the left; cut also the levator humeri, and cervical trapezius near their insertion into the limb, and flatten back these muscles upon the chest.

Costal Region.—1. Place the subject in the second position. 2. Remove the fore-limb and all the muscles which attach it to the trunk, sawing through the shoulder to show the serratus magnus and the intercostals; complete the dissection of the serratus magnus by removing the yellow fibrous tissue which covers its posterior serrations. 3. In order to study the external intercostals and the transversales costarum, raise the external oblique of the abdomen, the serratus magnus, and serrati parvi antici et postici, the common intercostal, and the ilio-spinal. 4. Remove some of the external intercostals, to lay bare the corresponding internal intercostals. 5. Prepare the sterno-costales upon a separate portion; to do this, separate the sternum from the thorax, cutting the sternal ribs a little above their inferior extremity.

Inferior Abdominal Region.—Place the animal in the first posi-

tion, make a large opening into the pectoral cavity by the removal of a certain number of ribs which are to be sawn through from above the costal attachments of the great oblique muscle. Remove the heart and the lungs; then cut through the diaphragm to get out the digestive viscera confined in the abdominal cavity. The cavity of the abdomen may not be examined at present, but if so, the great intestine must be punctured in several places to let out the accumulation of gas in the digestive tube, and thus relieve the great distention of the abdominal walls. These preliminary precautions having been taken, proceed to the following dissections:—1. Skin the region, leaving the panniculus upon the inner surface of the skin, and study the external face of the abdominal tunic. 2. Prepare the external oblique, raising the yellow fibrous tissue covering the fleshy portion of the muscle, along with the pectoralis magnus. Lay bare the inguinal ring by removing the dartos of the sheath of the penis or of the teats. 3. Upon the opposite side, demonstrate the internal oblique by cutting the external, at least the portion of the aponeurosis which is confused with that of the former muscle. Having studied the external oblique, dissect on the same side the rectus abdominis, separating from the linea alba, by a longitudinal incision, the aponeurosis common to the two obliques, dividing this aponeurosis and the fleshy portion of the internal oblique by another incision carried transversely from the umbilicus to the middle of the lumbar region, and flattening back one of these musculo-aponeurotic flaps upon the thigh, the other upon the ribs. 5. Prepare the transversalis abdominis where the dissection of the external oblique has been made. To lay bare this muscle, it is sufficient to make two incisions resembling the above, but between the two oblique and the rectus, and then throw back the two flaps as above described. 6. Before opening the abdominal cavity, cut the transversalis in the same manner, and study the muscular digitations of this muscle, the internal orifice of the inguinal canal, and the reflected fold of the aponeurosis of the external oblique.

Diaphragmatic Region.—Place the subject in the first position; open the abdomen and remove the viscera which it contains, also the great vascular trunks which run through it from the sub-lumbar region; detach the peritoneum from the fleshy portion of the muscle to see better the digitations of the latter; take care not to make an opening through which air might pass into the thoracic cavity, because this accident would destroy the concavity of the diaphragm.

Muscles of the Anterior Extremity.

External Scapular Region.—Separate the limb from the trunk. Raise the trapezius and levator humeri, to show the external surface of the aponeurosis; remove entirely the pectoralis anticus, after having studied the mode of its insertion into this aponeurosis. The latter having been studied, remove it to lay bare the antea-spinatus, postea-spinatus, and teres externus; preserving only the portion which is attached to the tuberosity of the spine—the anterior portion of this last muscle. Afterwards, in order to study the humeralis externus, cut transversly the teres externus along with the postea-spinatus, and throw back the muscular flaps, an operation which must be done with care on account of the intimate adherence of this group of muscles.

Internal Scapular Region.—Return to the limb which served for the dissection of the preceding region. Remove the light fascia which constitutes the internal scapular aponeurosis or fascia. Take care to preserve the termination of the latissimus dorsi, in order to study the connections and relations of this muscle with the teres internus; observe also the humeral insertion of the pectoralis magnus, so as to see its union with the tendon of the coraco-brachialis. The scapulo-humeral, which this preparation shows, is to be dissected at the same time as the humeralis obliquus.

Anterior Brachial Region.—1. The *Flexor Brachii*.—Place the limb upon its inner face; reflect upon the external muscles of the forearm the brachial insertion of the levator humeri, the sterno-humeral, and the sterno-aponeurotic; divide longitudinally the inferior extremity of the antea-spinatus, to lay bare the tendon of this muscle. The inferior insertion will be studied at the same time as that of the humeralis obliquus.

2. The *humeralis obliquus*.—Place the limb upon its inner face and divide the teres internus, the antea-spinatus, the caput magnum, caput medium, and caput parvum (extensors of the forearm), to lay bare the middle part and the upper extremity of the muscle; then turn the limb upon its external face so as to see the inferior extremity. It will be well, in studying the latter in all its details, to cut the internal ligament of the elbow joint, and the muscles of the forearm which are attached to the epi-condyle.

Posterior Brachial Region.—The muscles of this region ought to be studied before those of the preceding region. To prepare the caput magnum, medium, and parvum, turn the limb upon its internal face, raise the delicate fibrous tissue which covers these muscles, and raise up the teres externus and postea-spinatus minor, which conceal a great part of their origin. Leave the limb in the same position to lay bare the anconeus, an operation which must be done with great care, because this muscle is almost entirely covered by the caput medium, and adheres to it very intimately. In order to dissect the scapulo ulnaris, and the caput magnum, turn the member upon its external side, and raise the vessels, nerves, and lymphatics which cover its posterior surface. Being united in a very intimate manner with the internal face of the caput magnum, the aponeurosis of the scapulo-ulnaris must be very carefully isolated.

Muscles of the Fore-Arm.—Raise the fascia of the fore-arm and the adipose tissue to lay bare these muscles, and isolate the one from the other. As the terminal insertions of some of these muscles are confined in the interior of the hoof, it is absolutely necessary, in order to see them, to break open this horny case, and we will describe some of the methods of performing this operation with little difficulty and fatigue. 1. The instruments necessary for breaking open the hoof are: a scalpel, a hoof-parer, a hammer, and a pair of strong forceps. 2. The limb is fixed by one or two assistants holding it in a vertical position, the foot resting upon the table, upon a stool, or a solid block of wood. 3. Push in, as deeply as possible, the blade of the scalpel between the pad and the horny cavity; move it about from right to left, and make it follow the inner contour of the wall, commencing the separation of the latter along with the living tissues. 4. By means of the hoof-parer and the hammer, split the wall into four or five fragments by a convenient number of vertical incisions. 5. When the wall has been thus divided into several segments, detach each of these, by again inserting the point of the hoof-parer into one of the incisions, and, using this instrument as a lever, throwing back the portion of horny substance to the right or left. The flap of the opposite side is then raised and separated from the subjacent tissues. Their complete detachment will be affected by means of the strong forceps, and by twisting them with considerable force, the portion of hoof will be torn from the sole. 6. In order to uncover the sole, pass the blade of the scalpel between the upper face of the horny arch

and the plantar surface of the third phalanx ; push the point of the hoof-parer into the space near the mameter, raising lightly the external edge of the sole. Then seize the latter with the forceps, and detach it, as well as the fourchette, by one wrench, giving the instrument a vigorous movement backwards and forwards, the assistants holding the limb tightly and with a force opposed to that of the operator.

Muscles of the Posterior Extremity.

Muscles of the Croup or Gluteal Region.—1. Place the animal upon its side, or better still, in the second position. 2. Skin the region to lay bare the iliac aponeurosis, studying its extent, attachments, and relations. 3. Raise this aponeurosis to show the commencement of the semi-tendinosus and fleshy portion of the gluteus maximus ; to display the tendinous portion of this last muscle, detach with the scalpel the sacro-sciatic insertion of the vasti, and reflect it. 4. Divide the gluteus maximus near its femoral insertion, and throw it back upon the sacral spine, to show the external surface of the semi-tendinosus. 5. Cut the gluteus maximus near its femoral insertions, so as to raise the entire mass of the muscle, observing the nature of its relations with the muscle beneath it, namely, the gluteus internus, which will then appear so as to be conveniently studied.

Anterior Crural Region.—1. Place the subject in the first position. 2. Study the tensor fasciæ latæ which invests the region. 3. Raise this muscle with the gluteus maximus, the vasti, the semi-tendinosus, the semi-membranosus, the two adductors of the leg, the pectineus, and the two adductors of the thigh, to show the three portions of the triceps. Separate these three muscular portions the one from the other, proceeding from above where the adhesion between them is very slight. Dissect at the same time the ilio-femoral.

Posterior Crural Region.—Place the subject in the first position. Then release one of the hind legs, and turn the subject on the corresponding side. The other member is fixed to the pillar supporting it, and the thigh is easily flexed to make tense the muscles. These preliminary arrangements having been made, proceed in the following manner :—1. Cut transversely the adductor longus, and reflect the two flaps to the right and left, to show the whole of the adductor magnus, and afterwards separate it from the semi-tendinosus and the

great adductor of the thigh. 2. After having raised the aponeurosis which covers the vasti and the semi-tendinosus, dissect this last muscle, preserving as well as possible its two superior insertions. 3. Prepare afterwards the vastus, isolating its two component parts, and expose the insertion of the sacro-sciatic ligament, cutting the analogous insertion of the semi-tendinosus; afterwards raise the whole mass of the vastus, and study its deep surface, its femoral insertion, and its relations with the subjacent organs.

Internal Crural Region.—1. Place the subject in the first position. 2. Prepare on one side the two muscles of the superficial layer, raising a delicate fibrous membrane which covers them and the inferior wall of the abdomen—the internal crural aponeurosis. 3. Demonstrate upon the opposite side the three muscles of the middle layer, cut the two adductors of the leg, reflecting their flaps to the right and left; then isolate the semi-membranosus from the adductor magnus. It will be also useful, to make the dissection of this last muscle more complete, to raise the entire mass of the triceps abductor femoris, the biceps rotator tibialis, and the ischio femoralis. 4. Dissect the small deep muscles upon a separate preparation.

Muscles of the Legs.—Separate the member from the trunk by cutting the femur through the middle. Dissect the insertions of the vastus, the adductors and the semi-tendinosus, to see the continuity of these muscles with the fascia of the leg; study the insertions of this fascia, especially where it is inserted into the summit of the calcaneum. To expose the muscles, raise their aponeurotic envelope, and take care to preserve the strong aponeurotic band with its various insertions. Finally, isolate the muscles one from the other, a very simple operation requiring no particular explanation.

III. DISSECTION OF THE ORGANS OF DIGESTION.

The Mouth.—The whole of the mouth ought to be examined by an antero-posterior and vertical section of the head.

The Palate.—Separate the head from the trunk; then saw through the ramus of the inferior maxillary bone above the angle of the jaw and the crown of the last molar tooth, in such a manner as to pass between the velum palati on the one side, the base of the tongue on the other, and leave this latter organ adherent to the lower law. Separate the lower jaw from the upper by cutting the masseter and

alveolo-labial muscles, and in this way expose the palate and the velum palati upon which it will then be possible to execute easily the special dissection necessary for their study. For the palate, these dissections consist in raising the mucous membrane which conceals the deep venous plexus, and of the partial removal of the latter so as to see the artery and the palatine nerves.

The Tongue.—1. Make, by means of a strong saw without a back, an antero-posterior and vertical section of the head, to study the general disposition of the tongue. 2. Remove from another head the lower jaw, leaving the tongue in the intra-maxillary space, so as to examine the internal conformation of the organ. 3. Upon another piece intended for the study of the muscles, lay bare these structures in the following manner:—Remove entirely the masseter; detach the cheek from the lower jaw and reflect the flap upon the upper; saw through the ramus of the jaw transversely, immediately behind, and then before the line of the molar teeth; remove and dislocate from the temporo-maxillary articulation the upper fragment of the bone, destroying the capsular ligament and the insertions of the pterygoid muscles; reverse the lower fragment so as to show the line of the molar teeth below, and the inferior border of the bone above in the bottom of the inter-maxillary space; it is sufficient in performing this last operation, to separate the buccal mucus membrane from the mylo-hyoid muscle, proceeding from above downwards. The dissection thus made is convenient not only for the study of the muscles of the tongue, but also for the study of the deep salivary glands, the pharynx, the larynx, the guttural pouches, the nerves and arteries of the head, &c. It is always well, to facilitate this dissection, to keep the jaws open by inserting into the mouth a piece of wood between the incisor teeth, immediately after the death of the animal.

The Velum Palati.—Study the velum palati: 1. By an antero-posterior and vertical section of the head. 2. Make the dissection described under "The Palate," page 456, and dissect off the mucous and glandular layer, so as to lay bare the fibrous membrane and the two intrinsic muscles; the extrinsic muscles ought to be studied with those of the pharynx.

The Sub-maxillary Gland.—To show this gland and the sub-lingual, make the section of the jaw described under "The Tongue," *ut supra.*

The Parotid Gland.—This gland is discovered, with its excretory

canal, after the removal of cervico-facial portion of the panniculus and the abducens aurem deprimens.

The Pharynx and Fauces.—1. Study, upon the antero-posterior and vertical section of the head, the general disposition and situation of the parts. 2. In order to examine easily the interior, separate the head from the trunk, leaving a portion of the trachea and œsophagus; then, by means of a transverse cut of the saw, separate all the cranial cavity behind the temporo-maxillary articulations; pass the saw through the middle of the articulations, and thus display the posterior wall of the pharynx, which may be opened in the median line to reach the interior of the cavity. 3. The muscles are prepared with those of the tongue, and after the same manner.

The Œsophagus.—Place the subject in the first or second position; raise the cervical panniculus from the left side; remove the corresponding fore-limb, and proceed to remove the ribs of the same side except the first; dissect afterwards the vessels and nerves which surround the œsophagus, having preserved their connections.

The Stomach.—In order to study the organ in its connections, it is sufficient to open the abdomen, and raise the intestinal mass, proceeding in the following manner:—The animal is placed in the first position, and slightly inclined to the left side; make a crucial incision upon the inferior abdominal wall, or surround all this wall by a circular incision, taking care not to wound any part of the intestine; the whole mass of the viscera is then drawn out of the abdominal cavity and brought upon the table which supports the subject; do not allow any part of this mass to slip down upon the ground, to avoid tearing either the intestine or the parts which the student desires to preserve intact in the abdominal cavity; afterwards cut the floating colon, at the point of its union with the rectum, and the duodenum, where it passes behind the great mesenteric artery; detach the base of the cæcum from the sublumbar wall by the rupture of the cellular tissue which connects this organ with the right kidney and the pancreas; detach it from the same cellular union which exists between the pancreas and the terminal extremity of the fourth part of the colon; separate the mesentery along with the vessels contained between its folds; the intestinal mass is thus at last expelled from the abdominal cavity, and a convenient preparation is made, not only of the stomach, but also of the spleen, liver, pancreas, kidneys, ureters, &c. The following is the method of turning the stomach inside out, so as to study

its internal surface, and to dissect its muscular coats:—Cut out the stomach, with about three inches of the œsophagus, and six inches of the duodenum, and then proceed to wash out the interior of the organ in the following manner:—Introduce a certain quantity of water into the stomach, by fixing the duodenum to the stop-cock of the cistern; then with the right hand, relax the stomach, holding firmly the duodenum with the left hand to prevent the escape of the liquid. The alimentary substances contained in the viscus are thus mixed with the water, and may be expelled by a little pressure made upon the stomach; repeat this four or five times, thus completely washing the inner surface of the organ. To invert the stomach, making the external surface the internal, introduce through the duodenum a loop of iron-wire, passing out through the œsophagus; pass through the loop a very strong waxed ligature, and then tie it securely round the œsophagus; by pulling the iron-wire passed through the pylorus, the latter will be sufficiently dilated to permit the passage of the cardiac end, and the stomach will be completely inverted. By inflating it, the stomach may be easily restored to its normal form and disposition, with this difference, that the mucous surface is external, and the serous internal.

The Intestine.—The study of the intestine must be made on a special preparation; open the inferior wall of the abdomen to show the organs. But as the mass which constitutes it is heavy and difficult to move, proceed to expel the contents by a proceeding analagous to that described under "The Stomach," *ut supra*. A puncture is made in the cæcum, sufficient to permit the escape of the substances accumulated in this reservoir. Those accumulated in the colon are got rid of by an incision in the pelvic flexure; those in the rectum, through an opening made in the floating colon; the small intestine is cut into three or four nearly equal parts. This operation having been completed, inflate the intestines so as to show their normal size; and thus the general disposition of the intestinal mass may be studied with the greatest ease in the interior of the abdomen. It will also be well to take the whole intestine out of the body of the animal, and placing it upon the table, isolate the different parts, study their succession, and give a complete account of their form.

The Accessory Digestive Organs.—To study easily the liver, pancreas, and kidneys, remove the intestinal mass, proceeding in the manner already described. To examine the details of their organisa-

tion, it will be well to detach these viscera, *en masse* with the diaphragm and the kidneys, and expose the whole upon one table.

IV. DISSECTION OF THE ORGANS OF RESPIRATION.

The Nasal Cavities.—Remove the lower jaw from three heads. On the first head, make two transverse sections, the one passing between the second and third molar, the other behind the dental arch. Saw through the second head longitudinally and vertically, a little to the side of the median line. Upon the third head, make a horizontal section, a little above the horizontal plane of the base of the cranium.

The Larynx.—1. Make a longitudinal section of the head, so as to study the general disposition of the larynx. 2. Isolate the cartilages, so as to examine their external conformation. 3. Raise the muscles from a third preparation, to examine the mode of articulation of the different cartilages. 4. Dissect the muscles. 5. Raise the larynx itself, taking care as much as possible of the walls of the pharynx, so as to study the internal surface of the organ, and, above all, its pharyngeal opening.

The Bronchial Tubes.—After having extracted the lungs from the thoracic cavity, fill them with water, by fixing the trachea upon the stop-cock of the cistern; then dissect the bronchial tubes, tearing away the pulmonary tissue by teasing and trituration.

The Lungs.—Study the disposition of the lungs in the thoracic cavity, by placing the subject in the second position, opening the chest by cutting away the ribs, and inflating the organ through the trachea, as already described. In order to study their external conformation, the lungs ought to be removed from their cavity, along with the heart and great vessels, and inflated.

V. DISSECTION OF THE URINARY ORGANS.

Place the animal in the first position. Remove one of the hind limbs. Take the intestines out of the abdomen with the usual precautions. Saw through the symphysis pubis; saw through the neck of the ilium on the side opposite; and remove the coxal portion between the two sections made by the saw. The pelvic cavity being thus exposed, the urinary apparatus is seen, and the scalpel will complete the dissection. In dissecting the kidneys, preserve their vessels and

connections with the pancreas and supra-renal capsules. Open the peritoneum to see the ureters. The bladder is to be inflated: to preserve the orbicular peritoneal fold which envelops the *cul-de-sac* of this organ, it may be necessary to detach this membrane from the pelvic wall. Independently of this dissection, the whole urinary apparatus should be removed from the body, and arranged upon a table. Then study, by means of sections, the structure of the kidneys, the arrangement of the pelvis, the mode of termination of the ureters, and the interior of the bladder.

VI. DISSECTION OF THE ORGANS OF CIRCULATION.

Structure of the Heart.—Before proceeding to the dissection of the muscular fibres of the heart, it is indispensable to boil this viscus in water for half-an-hour or three-quarters of an hour.

The Pericardium.—Place the animal in the second position; remove the sternal ribs, separating them from their cartilages; then dislocate the costo-vertebral articulations. This dissection permits the study of the situation and general disposition of the heart and of the pericardium. To examine with ease the reciprocal arrangement of these two organs, remove them from the thoracic cavity by detaching the sternal insertion of the pericardium.

Preparation of Arteries.—The preparation of arteries consists of two successive operations—1. Injection; 2. Dissection.

Injection of Arteries.—Injection is an operation consisting of the introduction into the interior of the vessels of a solidifiable substance, intended to give to their canals the volume and conformation which they present during life when they are filled with blood. Suet mixed with lamp-black is the material usually employed. Another injection sometimes used consists of gelatine, mixed with a certain quantity of plaster of Paris; but this is little used in the French school. A copper or brass syringe and a nozzle, fitted with a stopcock upon the extremity of the syringe, is necessary for pouring the injection into the arterial vessels. The method of making a general injection is as follows:—The animal having been laid upon a table, the carotid artery is laid bare by means of an incision made in the jugular fossa. The vessel is opened longitudinally. A ligature is applied above the opening, and the nozzle is securely fixed in the artery, upon the cardiac side, by aid of a second ligature. The injection, prepared beforehand, is drawn

into the syringe. The syringe is then carefully screwed upon the nozzle, and the piston is pushed steadily onwards, so as to make the injection pass into the arterial canals.

To succeed well in this operation, attend carefully to the following precautions :—

1. Inject an animal which has been killed by bleeding, and before it is cold.

2. Heat the suet (if it is suet which is employed, and which is recommended by Chaveau) to a degree of temperature which the finger can bear without pain. If it is colder, the suet solidifies too soon ; if it is warmer, it will shrivel up the sigmoid valves, pass into the left ventricle, and destroy the valves of the pulmonary veins, an accident which is also sometimes caused by pushing the piston of the syringe with too much force.

3. Avoid applying too much force to the piston, which would cause the sigmoid valves to yield to too great an extent.

4. Stop the injection when the arteries react, by their elasticity, upon the piston, so as to drive it with considerable force from one end of the syringe to the other.

Instead of making the injection into the carotid, fix a long curved nozzle into the aortic trunk itself, after having made an opening into the left side of the chest, on the plane of the heart, by cutting away two segments of the ribs, and by making an incision into the pericardium over the left ventricle, so as to introduce the nozzle directly into the aorta. This proceeding allows the injection of suet to be as hot as possible, and gives sufficiently good results, because the suet then penetrates, if it be injected under favourable conditions, almost into the capillary vessels ; and in some organs, forces the injection even into the veins.

But whichever method is followed, there are certain parts which cannot be reached by a general injection—such as the four extremities. A special operation must be performed to force the injection into the vessels of the extremities. After having separated them from the trunk, by sawing them through above the knee or the ham, they are allowed to remain for two hours in a bath of water, kept constantly at a temperature of from 60 to 70 degrees, or more, and then they are very easily injected through the posterior radial artery or the anterior tibial, or through any of the other arteries which present their open mouths upon the section of the limb. If we wish to make partial in-

ections of other parts of the body, it may be found easier not to eparate them completely from the trunk, but then the student should ake the precaution of cutting off or tying the vessels which establish nastomatic communications between the arteries injected and those which he does not wish to inject. For example, if he wishes to inject he arteries of the head, it is sufficient to inject one of the two common carotids, having tied the other in the middle of the neck, and the wo vertebral arteries in the interstice between the two portions of the scalenus muscle.

To inject the capillary system, recourse is had to other substances, and to a different method. The following may be used: varnish, alcohol, essence of turpentine, holding in suspension very fine colouring materials, gum arabic, dissolved and coloured by any colouring matter capable of dissolving it, and colours beaten up in oil, or suspended in essence of turpentine.

Dissection of Arteries.—There are no general rules to be given for the dissection of arteries.

Pulmonary Artery.—It is evident the pulmonary artery will not be reached by the general injection already described. Inject it directly by passing the suet into the right side of the heart, through the vena cava anterior, after having tied the vena cava posterior.

Internal Iliac Artery.—Place the subject in the first position; remove one of the hind limbs; leave the rectum and the bladder in the pelvis; inflate slightly this last viscus by insufflation. Dissect, upon the side from which the member has been removed, the origins and the visceral branches furnished by the trunk. Follow upon the opposite side the twigs running from these branches into the muscular masses. Finally, so as to prepare easily the coccygeal arteries, having raised the great ischiatic ligament and dissected the internal artery of the bulb with its sub-sacral trunk, raise the rectum and the bladder by means of dissecting hooks-and-chain.

The Popliteal Artery.—The preparation which served for the study of the femoral artery having been arranged, raise the gemellus internus and the popliteus muscles.

Anterior Tibial Artery.—Expose this artery by elevating the muscles of the legs.

Arteries of the Head.—After having carefully raised the skin, dissect on one side the superficial arteries—that is to say, the external maxillary, the maxillo-muscular, the temporal and posterior auricular,

having removed the parotid gland to expose the origin of these three last vessels. Upon the opposite side display the deep arteries, and make a section of the orbital zygomatic processes, by means of three sections made by the saw.

Injection of Veins.—It will make the study and dissection of veins easier, to fill them with suet or any other solidifiable substance; but to do this, a different proceeding is followed from that described for arteries. In place of making the injection flow from the trunks towards the branches, as in arteries, *it must flow from the branches to the trunks* in the case of the veins, owing to the presence of valves. Fix the nozzle above many successive veins. Four injections are in general sufficient to fill the whole venous system in a satisfactory manner: the first is poured through the alveolar vein under the masseter muscle; the second, into a digital vein of one or two fore-limbs, on the side of the foot, after having destroyed with a stylette the several valves which are sometimes found near the point of union of the roots of this vein, upon the cardiac side; the third, into the postero digital veins, under the same conditions; the fourth, into an intestinal vein. If any important veins require to be studied after these four operations (which are done consecutively), they are separately injected.

VII. DISSECTION OF THE LYMPHATIC SYSTEM.

The lymphatic plexuses are studied after having been injected with mercury, a proceeding which may be very briefly described, as it is seldom done by those for whom this work is intended. The apparatus commonly used consists of a tube of glass, continued by a flexible tube, which carries at its lower end an iron stop-cock and a fine cannula made of iron or glass. To use this apparatus, fill the tube with mercury and suspend it; seize hold of the cannula with the right hand, holding it parallel to the membrane which is to be injected, and push it into the superficial layer of this membrane. The extremity of the cannula is then introduced into the middle of the meshes of the plexus, and of course wounds one of the small vessels which compose the plexus; then turning the stop-cock, permit the mercury to flow into the vessels through the rents. In this way they may be perfectly filled. The lymphatic plexuses being always placed above sanguineous plexuses, always take the precaution of puncturing the membranes as

superficially as possible, because if the point of the cannula penetrate too deeply, mercury passes into the veins, the operation is a failure, and must be done over again.

The study of the branches and trunks of the lymphatics may also be facilitated by inflating them from their origin to their termination. If well done, this proceeding, which was almost exclusively followed by the ancient anatomists, gives very satisfactory results It is sufficient to demonstrate the texture of the ganglia.

The Thoracic Duct.—Ligature the jugular and axillary veins near their termination, as also the vena cava inferior about its middle; lay bare the thoracic duct by cutting the right ribs; open it near the pillars of the diaphragm, and pour into it two injections of suet, the one before and the other behind the incision. The first injection will fill the duct along with the venous reservoir, which is intercepted between the ligatures applied to the vessels, as already described; the second, since it is directed in the opposite direction to the valves, overcomes the resistance offered by them, and expands the canal of Pecquet and the chief branches which end in it. Another method is as follows:—One of the branches in the abdominal cavity may be selected, as, for example, one of those united to the colic arteries, near their origin, and the thoracic duct completely injected from its origin to its termination. But this operation requires more practical dexterity than the first, in order to reach the vessel into which the nozzle is to be inserted; and it is not at all easy to perform it upon very fat animals.

VIII. DISSECTION OF THE NERVOUS SYSTEM.

The Spinal Cord.—Separate the cranium from the vertebral column and all the other parts of the body; then open the spinal canal, with the encephalic cavity, upon the superior surface, making a section, by the aid of the hoof-parer and a hammer, of the cranial vault and the ring of all the vertebræ. Study at once the surface of the organ thus laid bare, lying in its osseous tube and enveloped in its membranes, then remove entirely the cerebro-spinal axis contained in the dura mater, and cut this last membrane by an incision down the middle, thus laying bare the spinal cord.

The Brain.—To study the brain, it is first removed from the cranial cavity. This is done by two operations. The first consists of opening

the cranium by removing its vault, using the hoof-parer and a hammer, after having removed all the parts covering it. Then open the dura mater with the scissors, and arrive directly upon the brain, which is to be completely isolated by raising its posterior extremity, and cutting from behind forwards all the nerves issuing from the base of the cranium, with the pituitary gland, as far forwards as the end of the olfactory lobes. This operation is quickly performed, but it does not permit of the preservation of the pituitary gland, which is strongly fixed in the sella turcica, an inconvenience avoided by employing the next proceeding. To perform this, open the cranium at the base or inferior plane,—thus: after having separated the head from the trunk, remove the superior maxillary, the tongue, the hyoid bone, and lay bare the osseous surfaces, cutting away all the soft parts. The head, thus prepared, is held by an assistant, the cranial vault being laid upon the table or a block of wood. Armed with the hoof-parer and a hammer, the operator divides the zygomatic arches and the styloid process of the occipital; then attacks in succession the condyles of the same bone, the basilar process, the sphenoid, the palatines, the ethmoid; and returns to the lateral parts which he detaches successively from the occipital and the ethmoid. The brain having been thus sufficiently exposed, the dura mater is set free as in the first operation, and raising it with the left hand, the adhesions by which it is yet fixed to the vault of the cranium,—adhesions chiefly composed of the veins of the brain, which disgorge themselves into the sinuses of the dura mater,—are divided by the scissors held in the right hand. Break down the adhesion in the ethmoidal fossa with the point of the scalpel, detach the olfactory lobes, and the mass of the brain is then set quite free. This proceeding is an operation more difficult than the first, but it has many advantages, preserving intact not only the pituitary gland, but also the ethmoidal lobes; and the ganglia of the cranial nerves are exposed as distinctly as the nerves themselves. Having thus described the means of removing the brain from its osseous cavity, a few words may be said as to the method of studying its structure with advantage. It will be well to have two brains, hardened by soaking for several weeks in alcohol, or in water having a little nitric acid added to it (1 to 10), so as to contract the nervous substance, and make more apparent the outline of the cavities of the brain. Rapidly examine the whole of the external surface, and then pass to the study of the pons,—isolating it upon a hard piece of brain, by making a section

of the peduncles of the cerebellum, and cutting away the cerebral hemispheres, proceeding from below upwards and from behind forwards; the remains of the hemispheres and the cerebellum being preserved for the further examination of their minute structure. The pons thus isolated permits the examination of its external conformation and of its cavities; that is to say, the ventricle of the optic thalamus, and the aqueduct of Sylvius, which are displayed by a longitudinal and superior incision. Then proceed to the study of the cerebellum, noticing its shape and surfaces upon the fragment of brain untouched, and its internal conformation and structure upon the fragment already cut off. Finish off with the cerebrum, the surface of which ought to be carefully examined. The study of the interior of the cerebrum is to be made in the following manner:—Commence by examining the lateral ventricles, and the communication of these cavities with all the other cavities in the brain; this is easily done by inflating these organs through a straw, the inflation raising the pituitary gland, the cerebral lobes, and the cerebellum. Then pass on to the corpus callosum, which is laid bare by a horizontal section of the hemisphere passing across the centrum ovale. Remove the corpus callosum upon each side of the median line, so as to reach the interior of the lateral ventricles. Study the septum lucidum, the corpora striata, the hippocampi, the tænia semi-circularis, the choroid plexus, the velum interpositum, and the foramen of Monro. Afterwards return to the foramen of Monro, to study its communication with the fifth ventricle; it will be well also to see the communication of the aqueduct of Sylvius and the fourth ventricle. Two longitudinal and vertical sections of the brain, the one in the middle, the other at the side, will be useful in studying these peculiarities. They may be made by means of a saw, the organ remaining fixed in the cranial cavity.

The Cranial Nerves.—Four dissections are necessary for the study of the cranial nerves:—1. A brain, removed by making a section of the base of the cranium, and hardened for a long time in alcohol or nitric acid, is used. This preparation permits the study of the origin of the nerves. 2. The superficial nerves of the head; that is to say, the auricular nerves and the divisions of the subzygomatic plexus, with the sub-orbital and mental branches, as also the superficial small branches of the three nerves of the ophthalmic branch of the fifth pair. 3. The method of preparing a dissection to study the maxillary nerves is as follows:—Raise the greater part of the masseter muscle, and dissect

the masseteric nerve: remove the globe of the eye, cut through the orbital and zygomatic processes, and thus uncover the antrum of Highmore, and expose the infra-orbital nerve; dissect afterwards the anastomoses of the facial nerve with the sub-zygomatic, by removing the parotid gland. 4. The deep nerves, comprising those of the globe of the eye, are demonstrated by a dissection the same as that already described for the arteries of the head (see p. 463). The pneumo-gastric and spinal nerves, which are not mentioned in this place, are prepared and studied along with the great sympathetic (see p. 469).

Brachial Plexus.—Place the animal in the first position, and slightly inclined to the side, releasing one of the fore limbs so as to allow it to fall over; cut through the three pectoral muscles near their insertion, upon the limb set loose, and reflecting them, keep them in this position by iron hooks-and-chain, attached above to the extremities of two suspensory bars. Then separate the pectoralis magnus from the panniculus, allowing this last muscle to fall upon the table along with the fore limb. By removing the mass of cellular tissue in which the nerves of the brachial plexus lie, the nerves are well seen, and may be isolated with great ease. It is well in this dissection to preserve the arteries. It is important also to preserve the perforating intercostal branches, to see their anastomoses with the subcutaneous thoracic division. To see the chief branches of the plexus, remove the limb from the trunk, and, if possible, inject the arteries. The nerves are then seen in their natural relations, and may be easily dissected.

Lumbo-sacral Plexus.—Having skinned the subject, and removed the viscera contained in the abdomen, isolate the posterior end of the trunk by cutting the vertebral column behind the last rib: then, by means of a median section of the pelvis, remove one of the hind limbs; the part is maintained in the first position—that is to say, the croup rests upon the dissecting-table, near one of the bars, and the foot is then suspended to the ring in the bar by means of a cord. Make two dissections—1. Dissect, after the removal of the pelvic organs and psoæ muscles, the whole of the plexus and its branches; 2. Lay bare, upon the other side, the posterior part of the plexus along with the nerves which issue from it, cutting the greater part of the gluteus magnus and the anterior portion of the vastus. To see the termination of the different parts of the nerves issuing from the plexus, it is well

to use the other limb, which, without being fixed, may be studied upon the table.

The Great Sympathetic.—(*The dissection of the pneumo-gastric and spinal nerves should be made on the same piece*). Having placed the subject in the first position, and raised the intestinal mass, proceed to the dissection of all the abdomino-pelvic portion of the system, and the terminal branches of the pneumo-gastric, after having removed one of the hind limbs, and divided the coxal end of the trunk by sawing the sacro-iliac articulation. The fore limb of the same side is then removed, the shoulder being easily sawn transversely through its middle, and the chest opened by the removal of all the costal wall, an operation performed by two cuts of the saw—the one making a section of the sternal cartilages, the other a section of the ribs near their upper end. The whole of the thoracic portion of the ganglionic system and the pneumo-gastric nerve may be thus demonstrated. The dissection of the sympathetic and the vagus in the cervico-cephalic region, along with the spinal nerves, is an operation which presents no difficulty, and is preceded by the extirpation of the inferior maxillary branch.

No II.

MORPHOLOGY OF THE VERTEBRATE SKELETON.

Transcendental anatomists have long been accustomed to regard the skeleton of vertebrate animals as being composed of a series of segments, and such men as Oken, Geoffroy St Hilaire, and Carus, among continental anatomists, and Maclisle, Owen, and Goodsir, among the anatomists of Great Britain, have proposed schemes or plans according to which they built up the framework of a vertebrate animal. It will suffice for the purposes of this work to describe briefly the ideal segment conceived by the philosophical minds of Richard Owen and John Goodsir; and for details, the student is referred to the published works of these anatomists. The nomenclature may appear uncouth and cumbrous to the student of osteology; but to avoid repetition, and to give precision and distinctness to the discussion of such abstruse and abstract inquiries, it will be found of great service, and it is well to remember that each term is essentially a generalisation from a vast number of facts collected laboriously by these anatomists.

Professor Owen's *type segment* or *vertebra* is composed of a central piece, with an arch above and an arch below. The upper arch is called the *neural* arch, because it contains a segment of the nervous axis (either brain or spinal cord), and is made up of two flat plates of bone, termed *neurapophyses* (*neuron*, nerve; *apophasis*, a projecting part), and a terminal spine of bone, sometimes bifid, called the *neural spine*. The upper arch sometimes includes another pair of plates of bone, situated between the neurapophyses and neural spine, termed the *diapophysis* (*dia*, across; *apophasis*). The lower arch has received the name of the *hæmal* arch (*haima*, blood), because it contains the great blood-vessels and the viscera, and, like the neural arch, it is composed of two plates of bone, called *pleurapophysis* (*pleura*, rib; *apophasis*), and another pair, called *hæmapophysis* (*haima*; *apophasis*), the arch being terminated by a keystone, or spine, sometimes bifid, termed the *hæmal spine*. Occasionally, the hæmal arch includes parts, or bones, called the *parapophyses* (*para*, across; *apophasus*); and other bones may diverge as rays from one or more of the preceding—such as *zygapophyses* (*zugus*, yoke;) *anapophyses* (*ana*, backwards), *metapophyses* (*meta*, between), *hypapophyses* (*hupo*, below), and *epipophyses* (*epi*, above).

These parts of a typical vertebra, or *vertebral elements*, as they are termed, are subject to many modifications in shape, number, and position, in various parts of the skeleton of the same animal, and in the same parts of the skeleton of different animals; and often it is only by studying the process of development that the anatomist is able to refer a particular bone to its proper place in his ideal vertebra. For example, in the cranium, the neural arch is enormously developed for the reception of the brain proper and ganglia, and the hæmal arch is very small. In the thorax, on the contrary, the hæmal arch is the larger, because it contains the great vessels and viscera, while the neural arch in this region is merely a small canal for the spinal marrow. In other regions, such as the neck of a bird, or the tail of a crocodile, both arches are small; and as we proceed backwards, we find one element of the vertebra after another removed until, in the tail, only the centre remains. It is easy to recognise a type-vertebra in the thorax, but it is difficult to do so in the cranium, where the parts are so much modified; and, accordingly, we find anatomists differing very much as to the parts of a cranial vertebra.

Professor Owen regards the skull as being composed of four verte-

bræ, the neck of seven, the true thorax of seven, the false thorax of five, the loins of five, the sacrum of five, and the tail of an indefinite number. He considers the extremities as merely appendages, the anterior extremity being an appendage of the occipital segment attached to the scapular girdle which forms its hæmal arch; while the posterior extremity is an appendage of the pelvic girdle, or hæmal arch.

The late Professor Goodsir brought his powerful mind to bear upon this subject, and his views, which in many respects differ from those of Owen, will be found expounded at great length in the papers he read before the British Association in 1856 (see vol. ii. Anatomical Memoirs). The following is an epitome of his views:—A constituent segment, with its appendages, is a *somatome* (*sōmo*, body; *temnō*, I cut); and every segmented animal, whether an annulose or a vertebrate animal, is an *entomosome* (*entomos*, cut in pieces; *soma*). As the segments or somatomes are arranged in groups, the term *syssomatome* (*sun*, along with; *sōma; temnō*) designates a group, *e.g.*, the head is the cephalic syssomatome. The entire framework of an entomosome, whether it be fibrous, cartilaginous, or osseus, is termed a *sclerome* (*sklēros*, dry, hard, with the termination of completeness); the segment of a sclerome is a *sclerotome* (*sklēros*, *temno*); and an aggregation of sclerotomes is a *syssclerotome* (*sun*, *sklēros*, *temno*.) Goodsir also recognised the fact, that in tracing backwards the sclerotomes in a vertebrate animal, they become modified in proportion as the organic systems are withdrawn, until at last the sclerotome may become a mere nodule; and he also states that a certain amount of "deterioration" takes place in the sclerotomes of the anterior, or cephalic, part of the framework. Each sclerotome is a segment of the fibrous sclerome recognised in early development, and the bones and cartilaginous parts of a sclerotome are formed and embedded in this fibrous structure. The number of sclerotomes in the head of the fish is six; in that of the amphibia and reptilia, six (except in the crocodilia, where a seventh is feebly developed); in that of birds, six; and in all mammals, except proboscidians, such as the elephant, seven.

Goodsir did not agree with Owen's view of the nature of limbs. Instead of regarding the extremities as mere appendages of *one* vertebral segment, developed into separate bones by vegetative repetition, Goodsir held that a limb does not necessarily derive all its parts from one sclerotome, but that several may contribute towards its formation. He did not agree with Owen in regarding the scapular girdle as the

hæmal arch of the occipital segment of the head, because that segment had already a hæmal arch in the transitory sclerous elements developed in the third pair of visceral laminæ, and also because the scapular girdle is always developed in the part of the trunk where it is ultimately situated. Goodsir determined the number of sclerous elements in a limb by the number of nervous elements entering it, and it was his opinion that at least *five* spinal nerves, each pair of course proceeding from a different vertebral segment, transmit filaments to the five distal divisions of the limb. Each sclerotome yielding elements to the structure of a limb, supplies as a sclerous element a single actinapophysis (*aktin*, a ray, and *apophusis*), or a pair of actinapophyses. The phalangeal, metacarpal, and metatarsal bones of the higher vertebrata, are more or less persistent conditions of the distal segments of the first actinapophyseal elements of a limb; and by atrophy or otherwise, one or more of these segments may disappear, leaving, as in the horse, four elements in *each* carpal row, two in the fore-arm, one in the arm, two in the next row for the coracoid and clavicle, and one in the proximal row for the scapula.

No. III.

ON A SUPERNUMERARY OBLIQUE MUSCLE OF THE EYEBALL.

By Thomas Strangeways, Professor of Veterinary Anatomy, Edinburgh.

(*Journal of Anatomy and Physiology, second series, No. II. May* 1868.)

A few days ago, when dissecting the muscles of the eyeball of an ass, in the dissecting room of the Veterinary College, I was somewhat astonished at finding a small but well-defined muscle, situated between the superior and inferior oblique muscles. It originated by a delicate tendon from a minute depression, in the superior part of the orbital plate of the frontal bone, about midway between the origin of the inferior oblique and the loop or pulley through which the belly of the superior oblique passes. The tendon of origin was succeeded by a fusiform fleshy belly of about three lines in diameter and about an inch in length, which passed obliquely upwards and outwards on the

outer side of the external rectus. The belly, embedded in a quantity of adipose tissue, terminated in a thin, flat tendon, which, after running nearly parallel for a short distance with, and loosely attached by cellular tissue to, the upper part of the belly of the superior oblique, became blended with the tendon of insertion of that muscle just as it passed under the tendon of insertion of the superior rectus.

As there are some slight differences between the arrangements of the oblique muscles of the eyeball of the Equinæ and those of Man, it may be necessary to point these out, so as to prevent any misunderstanding as to the position of this small oblique muscle.

The superior oblique muscle in the horse and ass is—1*st*, Relatively longer and larger than in man, and is fleshy for some distance after it has passed through the loop, which loop is situated at the base of the orbital process of the frontal bone; 2*d*, The muscle, after passing through the loop, extends almost directly outwards under the tendon of the superior rectus, to gain its insertion between the tendons of insertion of the superior and external recti. The point of insertion is thus not so far to the back of the eyeball as in man.

The inferior oblique, arising from the lachrymal fossa, is directed forwards and upwards, its belly running in the same direction as the reflected portion of the superior oblique, and becomes finally inserted between the tendons of insertion of the external and inferior recti, much lower down and also further forwards than in man.

So far as my researches have gone, this small muscle has not hitherto been described, either in consequence of being an exceptional occurrence in this animal or of having been overlooked. There can be no doubt, I think, of its being an accessory or check muscle of the superior oblique, placed there for the purpose of preventing the belly of that muscle becoming fixed in the loop through which it has to pass at such an acute angle, in the lower animals more especially.

Unfortunately, the other eyeball had been removed by one of the students, to whom the subject belonged, before I had commenced my dissections; but still, on searching within the orbit, I was enabled to find part of the belly and the tendon of origin of a similar muscle, which had precisely the same point of origin, and, in all probability, a similar insertion.*

* Since the above was published, Dr Johnston has dissected the muscle in both eyes of two subjects.

No. IV.

UPON A NON-STRIPED MUSCLE CONNECTED WITH THE ORBITAL PERIOSTEUM OF MAN AND MAMMALS, AND ON THE MUSCULUS KERATO-CRICOIDEUS.

By Wm. Turner, M.B. (Lond.), F.R.S.E., Professor of Anatomy, University of Edinburgh.

(*Natural History Review, January* 1862.)

Whilst engaged in making a dissection, in the human subject, during the winter session of last year, of the superior maxillary, or second division of the fifth cranial nerve, my attention was attracted to a pale-reddish, soft mass, filling up the narrow chink of the spheno-maxillary fissure, and extending, from the sphenoidal fissure in the sphenoid bone to the infra-orbital canal in the superior maxillary bone. It was evidently connected to the superior (ocular) aspect of the periosteum of the orbit, and it was pierced by the orbital branch of the superior maxillary nerve, from which, as well as from the ascending branches of the spheno-palatine ganglion, it appeared to receive its supply of nerves. It completely shut off the superior maxillary nerve, with its infra-orbital continuation, from the cavity of the orbit.

Since the period of making the above observation, I have availed myself of several opportunities of examining the same region in other subjects, and have constantly observed appearances of a nature similar to those just described. The amount of the reddish mass, and the depth of its tint, varied slightly in different instances. Frequently, it was so pale as scarcely to attract attention, which may perhaps be the reason why it has so long been neglected by anatomists. When carefully examined with the naked eye, or, still better, with a single lens, it was seen to exhibit a fibrous appearance. A small portion snipped off with scissors, teazed out with needles, and placed on the stage of the microscope, under a quarter inch objective, was observed to be composed of pale, flattened, band-like fibres, having a faintly granular aspect, and presenting indications of elongated nuclei at intervals. From these characters I had little doubt that the structure in question consisted of the non-striped form of muscular fibre.

As considerable difficulty is always experienced in obtaining for examination the contents of the human orbit, in a perfectly fresh condition, I, in the next instance, proceeded to dissect the orbits of some of the more readily obtained mammals, with a view of ascertaining if a similar structure existed in them. In the orbit of the sheep I have most satisfactorily observed appearances which have fully confirmed the opinion of the structure already expressed. The orbit of this animal differs from that of man in possessing much less perfect walls. As a consequence of this, the orbital membrane, or periosteum, is a structure of much importance, for it stretches across the floor of the orbit from its outer to its inner wall, extends backwards to the optic foramen, and completes the boundary of the cavity at the spot where the bony wall is wanting.

If the contents of the orbit be carefully removed, and the orbital membrane examined from above, it will be seen to be a well-defined structure, distinctly fibrous, and in many places having an almost tendinous-like aspect. Intimately connected with, and forming an essential part of it, is a thin layer of a pale reddish substance, which extends across the greater part of the floor of the orbit, passing backwards to the optic foramen and sphenoidal fissure. In close contact with this structure, especially at the posterior part of the orbit, is a well-marked vascular net-work, sufficiently injected with blood to be distinctly visible. This vascular plexus constitutes a small rete mirabile, connected with the ophthalmic artery. By removing a small portion of the reddish mass, teazing it out with needles under water, and examining it with a quarter inch objective, it may be seen to be composed for the most part of flat, pale, non-striped fibres, collected together in bundles, having a faintly granular aspect, and exhibiting decided indications of nuclei in their interior. These bundles of flat fibres are mingled with ordinary fibrous tissue, both white and yellow, the latter becoming more distinct after the addition of acetic acid. The pale, non-striped fibres have all the characters of the involuntary muscular fibre. Being desirous, however, of ascertaining if these fibres could be resolved into their constituent fibro-cells, I adopted the plan which has been recommended by *Reichert*, and macerated a portion of the orbital membrane for forty-eight hours in dilute hydro-chloric acid. I then found that, by the aid of a very slight dissection, the fibres readily resolved themselves into the elongated fusiform cells of which they were composed. In no tissue which I have ever examined, con-

sisting of the non-striped muscle, have I succeeded in obtaining more beautiful and more perfect specimens of the contractile fibre-cell than in this muscle of the orbital membrane. The fusiform shape of the cells, their size, and the elongated rod-like nucleus in the centre of each cell, give to the texture a most characteristic appearance. I may also mention, that when the orbital muscle in the sheep was examined without the addition of any re-agent, besides distilled water, a number of elongated rod-like nuclei were always met with, lying free in the water surrounding the preparation, which had evidently been loosened and detached during the dissection with the needles. These nuclei corresponded in their characters to those met with in the interior of the fibro-cells. The characters which I have now enumerated render the muscular nature of the reddish texture connected with the orbital membrane sufficiently clear.

On referring to the authorities who have written on the structure of the orbital membrane I find that the following opinions have been expressed concerning it.

Bendz, in a paper "On the Orbital Membrane in the Domestic Mammals," describes it as distinctly fibrous, but possessing a considerable quantity of a yellowish tissue, which he considers to be elastic, interpolated with it. He regards the opinion, which had been previously advanced by *Gurlt*, that the tissue was muscular, to be erroneous. *Stannius* states that in those animals, in which the bony wall of the orbit is incomplete, the separation between the orbital cavity and the temporal fossa is mostly effected by a fibrous membrane, containing also abundant elastic tissue. He states that *Rudolphi* regarded these elastic fibres to be muscular in bears, and that *Meckel* described a muscle in the orbital membrane of Ornithorynchus. *Chauveau* speaks of the fibrous membrane which completes the cavity of the orbit as entirely composed of white inextensile fibres. *Gurlt* considers it to be a strong fibrous membrane, with yellow elastic fibres interpolated. *H. Müller*, in a very brief communication, states that he has found flat muscular fibres in the inferior orbital fissure in man, and corresponding structures connected to the membrana orbitalis of mammalia.

It was supposed by those, who held that the membrana orbitalis was a highly elastic and not a muscular structure, that it was through its elastic recoil that the eyeball was reprotruded in those animals which retracted the ball through the contraction of a retractor muscle. *H. Müller*, again, who speaks more positively than any who have preceded

him, not only of the existence of a muscle, but also of the kind of fibre of which it is composed, considers that it antagonises those muscles which retract the eyeball into the socket, and that thus, the reprotrusion of the globe is produced, not by a mere elastic recoil but by a muscular contraction.

If this hypothesis be correct, an arrangement exists in this locality, which is certainly to be regarded as an unusual one, viz.—an involuntary muscle acting as a direct antagonist to a voluntary muscle. Whether the hypothesis be correct or not, I am disposed to consider that the muscle has some especial relation to the vascular arrangements in the orbit. Its extension backwards to the foramina through which the orbital vessels proceed, and with which it is in immediate relation, and the very abundant vascular net-work found in connection with it, point, I think, to some special relation between the muscle and the vessels, a relation which is not at all inconsistent with what is known of the function of non-striped muscle in other localities.

* * * * * *

Note.—Since the above paper was in type, my attention has been directed, by Professor Huxley, to a communication by H. Müller, dated 15th Dec. 1860, entitled "On the Influence of the Sympathetic upon some Muscles, and on the extensive occurrence of unstriped Muscles in the Skin in the Mammalia."

As this paper throws some additional light upon the probable action of the orbital muscle, I append a short abstract of it:—

H. Müller, after referring to the many puzzling questions which have arisen respecting the function of the sympathetic nerve, and its relations to the muscles supplied by it, proceeds to ask two questions—

1*st*, Whether and which unstriped muscles are supplied by other nerves than the sympathetic?

2*d*, Whether and which transversely striped muscles are under the influence of the sympathetic?

In answer to the first, the action of the oculo-motor nerve upon the unstriped fibres of the iris cannot be doubted: the vagus also acts upon unstriped muscles, and the experiments of Schiff have shown that the greater part of the vascular nerves are not connected with the sympathetic.

The second question may be most effectively answered by considering the effect produced upon the eyeball by division or irritation of the

cervical sympathetic. Müller, for this purpose, refers to the experiments of Bernard, R. Wagner, and Brown-Sequard; the general tendency of which is to show, that division of the cervical sympathetic produces narrowing of the palpebral fissure, retraction of the bulb, projection of the nictitating membrane and narrowing of the anterior nares and the mouth. Irritation of the nerve by galvanisation, on the other hand, produces increase of the opening of the lids, projection of the bulb, retraction of the nictitating membrane, relaxation of several facial muscles. Respecting the causes which produced these changes there was some difference of opinion. R. Wagner could scarcely conceive that any force, save the contraction of the two obliqui, could produce projection of the eyeball, and yet he asks, "How could these transversely-striped muscles receive excito-motory fibres from the sympathetic?" Brown-Sequard, again, considered that retraction of the bulb, after section of the nerve, was produced by the active contraction of the retractor and recti, and that its reprojection by subsequent irritation was a reposition. Schiff regarded the projection of the bulb as due to the action of the obliqui: the movements of the lids he considered to be passive, and due to those of the bulb.

Remak, on the other hand, believed that the narrowing of the palpebral fissure was due to a relaxation of the levator palpebræ superioris, accompanied by a spasmodic contraction of the orbicularis. Moreover, he conceived that the sympathetic acted upon the voluntary muscles of the lids about the eye.

Müller considers that it is now no longer necessary to discuss the various probabilities respecting the influence of the sympathetic upon the voluntary muscles of the eye, as a complete series of unstriped muscles have now been observed, which will serve as a foundation for explaining the movements in question.

These muscles consist of three divisions—

1*st*, In the orbital cavity of mammals, a membrane (membrana orbitalis), consisting of unstriped muscles with elastic tendons, exists, which, by irritation of the cervical sympathetic, projects the contents of the orbit, especially the bulb, forwards. Retraction is produced by the transversely-striped retractor. In man, the orbital muscle is much reduced in size, and the retractor is wanting, so that a distinct projection of the bulb does not follow irritation of the sympathetic, as Wagner and H. Müller himself have observed.

2*d*, The projection of the nictitating membrane in mammals is mostly

due to the retractor bulbi under the influence of the N. abducens. Its withdrawal depends on some unstriped muscles which are under the influence of the sympathetic. In hares, however, the withdrawal is due to a transversely-striped muscle, which is not supplied by the sympathetic but by the oculo-motorius. In man, the lid and its muscles are rudimentary.

3*d*, The upper and lower lid possess in man, and in very many mammals, unstriped muscles, which have the power of drawing them back. They are more feeble in the upper than the lower lid, so that by irritation of the sympathetic the latter is drawn back in a more marked manner than the former. Narrowing of the palpebral fissure, after section of the cervical sympathetic, depends upon relaxation of these muscles. Yet recession of the eyeball may depend upon relaxation of the orbital muscle. Müller, then, concludes that the movements occasioned by experimenting on the cervical sympathetic are not such as to entitle us to infer an influence of that nerve upon voluntary striped muscle. He also considers that the movements about the nose and mouth, said by Bernard to be produced by section of the sympathetic, if they do take place, are owing to the presence of unstriped cutaneous muscles.

Müller next inquires into the existence of unstriped muscles in the skin of the ear. He has occasionally found, on galvanising the cervical sympathetic in cats, that a movement of the hairs growing upon the skin at the entrance of the concha has taken place. This experiment has, however, frequently failed both in cats and other animals. A careful examination of the skin of the part did not give any indications of unstriped muscles, but very distinct muscles were seen connected to the hair follicles. He considers these experiments of interest, as they appear to indicate whence the muscles of the hair follicles receive their nerves. Owing to the movement of the hairs being limited to a very small locality, during the irritation of the sympathetic, one must suppose that only a very small part of the unstriped muscular apparatus of the skin of the cat can be regulated by the cervical sympathetic.

No. V.

ON THE DENTITION OF THE DOMESTIC ANIMALS.

By Dr Wilson Johnston.

In working out the dentition of the domestic animals, I have traced out the following approximate numerical sequences which will prove a useful *memoria technica* to the student:—

I. In the Horse.

The Keynote for the *Milk* Incisors is 9.

1. Foal may be dropped with central deciduous teeth, or they are up by the 19th day.
2. Lateral incisors are up by the 9th week.
3. Corner incisors are up by the 9th month.

The Keynote for the *Permanent* Incisors is EVERY YEARS.

1. At 3 years, central permanent incisors are up.
2. At 4 years, lateral permanent incisors are up.
3. At 5 years, corner permanent incisors are up.
4. At 6 years, infundibulum of central permanent is gone.
5. At 7 years, infundibulum of lateral permanent is gone.
6. At 8 years, infundibulum of corner permanent is gone.

When the horse is aged.

II. In the Ox.

The Incisors are developed in *Upper* Jaw only.

The Keynote for *Milk* Incisors is 4.

1. The calf is usually dropped with 4 central deciduous incisors.
2. The lateral pair are up in 14 days.
3. The corner pair are up in 4 weeks.

The Keynote for *Permanent* Incisors is 6, there being a graduation of 6 Months between appearance of each pair.

	Year.	Month.
1. Central pair of permanent incisors are up at	1	9
2. Internal lateral pair of incisors are up at .	2	3
3. External lateral pair of incisors are up at .	2	9
4. Corner pair of incisors are up at . .	3	3

III. In the Sheep.

Incisors only in Upper Jaw.

The Keynote for Permanent Incisors is 9.

	Year.	Month.
1. Central pair are up at . . .	1	3
2. Internal lateral pair are up at . .	2	0
3. External lateral pair are up at . .	2	9
4. Corner pair are up at . . .	3	6

IV. In the Pig.

The Keynote is 4—the Teeth-Supply running in a gradual increment of 4.

1. The pig is dropped with 4 corner deciduous incisors and 4 deciduous tusks.

2. In a month, 4 central deciduous incisors are up.

3. In 3 months, 4 lateral deciduous incisors are up.

4. In 9 months, 4 permanent *corner* incisors replace the fœtal ones, and 4 permanent *tusks* are cutting.

5. In 12 months, 4 permanent *tusks* are up, and the 4 *central* incisors appear.

6. In 18 months, 4 lateral permanent incisors are up, and the dentition is complete.

INDEX.

Abdomen (*abdo*, I hide), dissection of, 457.
divisions of, 229.
fasciæ of, 136.
lining membrame of, 244.
muscles of, 136.
regions of, 229.
viscera of, 228.
position of, 228.
Abdominal, anterior, artery, 327.
Abdominal ring, external, 138.
internal, 138.
Abducens aurem deprimens, 172.
Abducent (*ab*, from; *duco*, I lead), nerves, 396.
Abduction, 112.
Abductor. *See* Muscles.
Absorbent glands. *See* Glands, Lymphatic.
system. *See* Lymphatic System.
Absorbents. *See* Lymphatics.
Abomasum of stomach of ox, 253.
Accelerator. *See* Muscles.
Acetabulum (a vessel for holding vinegar), 30.
Acoustic (*akouō*, I hear) nerve, 398.
Adduction, 112.
Adductor. *See* Muscles.
Adipose (*adeps*, fat) tissue. *See* Fat.
Afferent lymphatic vessels, 357.
nerves, 368.
Age indicated by teeth, 223.
Agminated (*agmen*, a troup) glands, 233.
Air cells, 298.
capillaries of, 298.
tubes of, 298.
Alæ of atlas, 19.
diaphragm, 170.
sphenoid bone, 70.
vomer, 78.
Albumen of blood, 301.
Alimentary (*alimentum*, food) canal, 207.
Alveoli (*alveolus*, a small hollow vessel) of lower jaw, 80.
of upper jaw, 73, 75.
lymphatic glands, 357.
stomach, 231.
Alveolo labialis. *See* Muscles.
Amphiarthrosis (*amphi*, on both sides: *arthron*, a joint), 111.
Ampullæ (*ampulla*, a flask) of labyrinth, 423.
Amygdalæ (*amagdalē*, an almond), 210, 226.
Anapophysis (*ana*, upwards; *apophysis*), 470.
Anastomosis (*ana*, through; *stoma*, a mouth)
of arteries, 312.
of veins, 342.
Anastomatic artery, 323.
Anatomical planes of description, 14.
Anatomy (*ana*, apart; *temno*, I cut)—
comparative, 1.
human, 1.
veterinary, 1.
Anconeus (*ankōn*, the elbow), 193.
muscle, 193.
of dog, 205.
Angeiology (*angeion*, a vessel; *logos*, discourse), 311.
Angular movement, 112.
processes of frontal bone, 65.
Ankle joint, 57.
bone, 58.
Annular (*annulus*, a ring), ligament of ankle, 131.
protuberance. *See* Pons Varolii.
Annulus ovalis (oval ring), 304.
Antea-spinatus. *See* Muscles.
Antrum (a cavern) of Highmore, 86.
Anus, 237.
Aorta (*aeiro*, I take up or carry), 315.
anterior, 325.
arch of, 316.
branches of, 325.
foramen in diaphragm for, 171.
posterior, 316.
parietal branches of, 316.
thoracic visceral branches of, 317.
abdominal visceral branches of, 318.
valves of, 308.
Apertura scalæ vestibuli, 422.

Aponeurosis (*apo*, from; *neuron*, a string), 129.
crural, 137.
of diaphragm, 170.
of external oblique muscle, 136.
internal oblique muscle, 136.
investment of, 130
of transversalis muscle, 140.
Apparatus lachrymal, 433.
Appendages of eye, 431.
Aqueduct (*aquæductus*, a conduit) Fallopius, 68.
Sylvius, 377.
vestibule, 68, 422.
Aqueous humour, 429.
Arachnoid (*arachnē*, a spider, or spider's web; *eidos*, shape), membrane of brain, 370.
membrane of spinal cord, 368.
Arch of aorta. *See* Aorta.
carpal, posterior, 42.
of colon, 234.
crural or femoral, 138.
plantar, 331.
pubic, 30.
tarsal, 59.
of a vertebra, 16.
ligaments of, 113.
zygomatic, 67.
Arches, coronary, 331.
dental, 73, 75, 80.
plantar, 331
sesamoidal, 325.
Areolar Tissue, 133.
serosity of, 134.
structure of, 133.
Arteries (*artēria*, *artēr*, that by which anything is suspended; originally applied to the wind-pipe, by which the lungs might be said to be suspended) general anatomy of, 311.
anastomosis of, 312.
coats of, 313.
contractility of, 314.
dissection of, 463.
distribution of, 311.
epithelium of, 313.
muscular tissue of, 313.
nerves of, 314.
physical properties of, 313.
sheath of, 313.
structure of, 313.
terminations of, 313.
vessels of, 314.
vital properties of, 314.
Arteries, Descriptive Anatomy of, 314.
Arteries or Artery.
abdominal, anterior, 327
anastomotic, 325.
asternal, 327.
auricular, anterior, 337
deep, 337.
posterior, 337.
superficial, 337.
axillary, 327.
basilar, 334.
bronchial, 317.
buccal, 340.
of bulb, 320.
carotid, common, 332.
external, 332, 335.
internal, 332, 334, 387.
central of retina, 340.
cerebral, anterior, 335
middle, 335.
cerebro-spinal of occipital, 3
334.
cervical, anterior, 327.
inferior, 327.
posterior, 326.
ciliary, 339.
circumflex, anterior, 328.
posterior, 328
iliac, 322.
foot, 332.
inferior, 332.
coccygeal, 321.
cœliac, 318.
cæcal, internal, 319.
external, 319.
colic, left, 319.
right, 319.
communicating, of brain, anterio
335.
posterior, 3
of cord, 332.
coronary of heart, 315.
of lips, 336.
cubital, 328.
dental, 338.
diaphragmatic, 317.
dorsal, of anterior innominate, 3
of posterior intercostal, 317
duodenal of hepatic, 318.
epigastric, 322.
facial, 336.
femoral, 323.
deep 322
femoro-popliteal, 324
of the frog, 321.
gastric, 318.
gastro-epiploic, left, 318.
right, 318.
glosso-facial, 335.

Arteries, gluteal, 321.
hepatic, 318.
humeral, 328.
deep, 328.
ileo-cæcal, 319.
iliac, external, 321.
internal, 320.
iliaco-femoral, 321.
infra orbital, 340.
inguinal, 323.
innominate, right, 325, 332.
left, 326.
intercostal posterior, 316.
ischiatic, 321.
labial, inferior, 336.
superior, 336.
lachrymal, 340.
laminal, lateral, 331.
anterior, 331.
lingual, 336.
lumbar, 317.
lumbo-spinal, 317.
mammary, external, 323, 327.
internal, 326.
masseteric, 337, 338.
mastoid, 333.
maxillary, internal, 335, 338.
inferior, 338.
superior, 340.
maxillo-muscular, 337.
meningeal, middle and great, 339.
ophthalmic, 339.
of posterior, 339.
of prevertebral, 333.
mesenteric, inferior, 319.
posterior, 320.
metacarpal, large, 330.
small, 329.
metatarsal, 325.
perforans or collateral, 325.
musculo-occipital, 333, 334.
nasal, lateral, of ophthalmic, 339.
obturator, 321.
occipital, 333.
œsophageal, 317.
ophthalmic, 339.
palatine, 338, 340.
paloto-labial, 340.
perineal, superficial, 321.
peroneal, 325.
perpendicular, 331.
pharyngeal, 335.
phrenic, inferior, 317.
plantar, external, 330, 324.
internal, 330, 324.
popliteal, 324.
prehumeral, 328.
prevertebral, 333.
Arteries, pterygoid, 337, 339.
pudic, 321.
internal, 321.
external, 323.
pulmonary, 314.
pyloric, 318.
radial, anterior or spiral, 329.
posterior, 329.
ramus anastomoticus of carotid 332.
ranine, 336.
recurrent, 333.
renal, 319.
sacral, middle, 317.
lateral, 321.
saphenic, 323.
scapular, anterior, 327
posterior,328
spermatic, 319.
spheno-palatine, 340.
solar, 332.
splenic, 318.
staphyline, 340.
of stifle, 325.
subcutaneous abdominal, 323.
sublingual, 336.
submaxillary, 335.
submental, 336.
subzygomatic, 337.
supra-orbital, 340.
temporal, 337.
anterior, 339.
deep, 339.
superficial, 335.
posterior, 339.
thoracic, external, 327.
internal, 326.
thyroid, accessory, 332.
laryngeal, 332.
superior, 332.
tibial anterior, 324.
posterior, 324.
transverse, 321.
of face, 338.
tympanic, 339.
ulnar, 328.
umbilical, 320.
uterine, 322.
utero-ovarian, 320.
vaginal, 321.
vertebral, 326.
vesico-prostatic, 320.
Arthritis, navicular, or groggy lameness, 52
Arthrodia (*arthron*, a joint), 111.
Articular (*articulus*, diminutive of *artus*, a joint), 105.
Articulation (*articulus*, a joint)—
general anatomy of, 105.

Articulation, astragalo-calcaneal, 127.
metatarsal, 127.
axo-atloid, 114.
calcaneo-cuboid, 127.
carpal, 119.
superior, 119.
inferior, 119.
radio, 120.
inter, 120.
carpo-metacarpal, 120.
cartilage of, 106.
articular, 106.
costal, 106.
membraniform, 106.
reticular, 106.
chondro-costal, 116.
costo-sternal, 116.
of ox, 116.
costo-vertebral, 115.
cubo-cuneiformal, 127.
metatarsal, 127.
distal inter-phalangeal, 123.
dissection of, 445.
hip joint, 125.
hock, 126.
humero-radio-ulnar (elbow), 118.
hyoid, 117.
of ox, 118.
ischio-pubic, 117.
maxillary of pig, 90.
membraniform, 106.
metacarpo-phalangeal, 121.
occipito-atloidean, 114.
axoidean, 114.
phalangeal, inter, distal, 123.
proximal, 122.
plantar, 128.
proximal inter-phalangeal, 122.
radio-ulnar, 118.
reticular, 106.
sacro-iliac, 116.
sacro-lumbar, 115.
scapulo-humeral (shoulder-joint), 118.
sternal, 116.
of ox, 116.
stifle joint, 124.
tarsus, 126, 128.
temporo-maxillary, 115.
of ox, 88.
tibio-fibular, 126.
varieties of, 105, 110.
vertebral, 112.
Arytenoid (*arutaina*, a pitcher or ladle; *eidos*, shape), 289.
cartilages of the larynx, 289.
Arytenoid ligaments, 292.
muscles, 291.
Asternal (*a*, neg.; *sternon*, the breast) ribs, 35.
artery, 327.
Astragalo-calcaneal ligaments, 127.
metatarsal ligaments, 127.
Astragalus (*astragalos*, the ankle-bone, or a dice, the astragali of the sheep having been used as dice by the ancients) 58.
Astragalus of ox, 97.
Atlas (*a*, euphonic; *stēmi*, I bear), 18.
of ox, 94.
of pig, 99.
of dog, 101.
ligaments of, 114.
Atloidean ligament, 114.
Atloido-muscles. *See* Muscles.
Attollens (*attollo*, I raise up). *See* Muscles.
Attrahens (*ad*, to; *traho*, I draw). *See* Muscles.
Auditory canal, external, 69.
meatus, external, 419.
internal, 68, 424.
nerve, 398.
Auricle (*auricula*, the outer ear)—
muscles of, 171.
nerves of, 397.
vessels of, 337.
Auricles of heart. *See* Heart.
Auricular arteries, 337.
muscles, 171.
nerves. *See* Nerves.
surface of sacrum, 26.
veins, 352.
Auriculo-temporal nerve, 395.
ventricular furrow, 302.
orifices, 304, 305.
rings, 309.
valves, 305, 307.
Axial fibre of nerve. *See* Axis, Cylinder.
Axillary artery, 327.
muscles of region, 140.
veins, 350, 352.
Axis (vertebra), 20.
of ox, 94.
of pig, 99.
of dog, 102.
ligaments of, 114.
cerebro-spinal, 365.
cœliac, 318.
cylinder of nerve fibre, 366.
of pelvis, 31.
thoracic, 326, 327.
Axo-atloid articulation, 114.
atloidean ligament, 114.
Axoido-atloideus. *See* Muscles.
Azygos (*azugos*, unyoked) vein, 350

Back, muscles of, 151, 156.
Band, primitive, of nerve fibre, 366.
Bars of hoof, 438.
Base, molecular, of chyle, 207.
Basilar (*basis*, a base) artery, 334, 386.
fissure of occipital, 63.
process of occipital, 63.
Basio-glossus (*basis*, a base; *glossa*, a tongue) muscle, 182.
Bendz on orbital membrane in domestic mammals, 476.
Bellini, ducts of, 261.
Bernard on movements of nose and mouth on dividing sympathetic, 479.
Biceps (*bis*, twice; *caput*, a head) muscle, 167.
Bicuspid (*bis*, twice; cuspis, the point) valve, 308.
Bile, 241.
Bile ducts, common, 241.
origin of, 240.
structure of, 240.
Bird, bone of, 3.
Bisexual reproduction, 264.
Bladder, gall. *See* GALL-BLADDER.
Bladder, urinary, 262.
coats of, 263.
detrusor muscle of, 262.
fœtus in, 263.
ligaments of, false, 262.
true, 263.
neck or cervix of, 262.
openings of ureters into, 263.
position of, 262.
structure of, 263.
trigone of, 263
urethral orifice of, 263
uvula of, 263.
vessels and nerves of, 263.
BLOOD, 300.
arterial and venous, 300.
chemical composition of, 282.
circulation of, 301.
in fœtus, 355.
coagulation of, 282.
colour of, 300.
corpuscles of, pale, 301.
red, 301.
differences of, in animals, 300.
composition of, 301.
structure of, 300.
fibrin of, 301.
liquor of, 301.
odour of, 300.
physical properties of, 300.
rinderpest in, 301.
serum of, 301.
specific gravity of, 300.
BLOOD, splenic, 243.
temperature of, 300.
typhoid fever in, 301.
Blood-vessels, general anatomy of, 311.
BONE, general anatomy of, 2.
cavities of, 10.
chemical composition of, 3.
classes of, 7.
compact or cancellated, 4.
corpuscles of, 5.
diseased bone, colour of, 2.
eminences of, 9.
external configuration of, 9.
formation and growth of, 11.
Haversian canals, 4.
spaces, 4.
lacunæ of, 5.
lamellæ of, 5.
marrow of, 7.
number of separate, in horse, 14.
periosteum of, 6.
physical properties of, 2.
processes of, 10.
structure of, 4.
vessels of, 5.
BONES, descriptive anatomy of, 15.
astragalus, 58.
of ox, 97.
of dog, 104.
atlas, 18.
of dog, 101.
of ox, 94.
of pig, 99.
axis, 20.
of dog, 101.
of ox, 94.
of pig, 99.
calcanium or os calcis, 58.
of ox, 97.
carpal, 42.
of dog, 103.
of ox, 98.
of pig, 101.
clavicle of dog, 103.
coccyx, 27.
of dog, 100.
of ox, 96.
of pig, 103.
coronal, 50.
cranial cavity, 85.
cranium, 62.
of ox, 87.
cuboid, 59.
of ox, 97.
cuneiform of carpus, 44.
of dog, 103.
of ox, 98.
of pig, 101.

Bones, cuneiform tarsus of dog, 104.
magnum, 60.
of dog, 104.
of ox, 89.
medium, 60.
of ox, 98.
parvum, 60.
ethmoid, 71.
of dog, 93.
of ox, 88.
of pig, 90.
face, 72.
femur, 53.
of dog, 104.
of ox, 97.
of pig, 101.
fibula, 57.
of dog, 104.
of ox, 97.
of foot, 36.
of fore extremity, 36.
fore-arm of, 40.
frontal, 65.
of dog, 92.
of pig, 90.
frontal sinus, 86.
hind extremity of, 53.
hock of, 57.
of dog, 104.
humerus, 37.
of dog, 103.
of ox, 98.
of pig, 100.
hyoid, 8.
of dog, 94.
of ox, 90.
of pig, 92.
ilium, 28.
of ox, 96.
incus, 420.
innominate, 27.
of dog, 104.
of ox, 96.
of pig, 101.
ischium, 29.
of dog, 104.
of ox, 96.
jugal, 76.
lachrymal, 76.
of dog, 93.
of ox, 89.
of pig, 91.
lenticular, 420.
lower limb of, 53.
lunate, os lunare, 43.
of dog, 103.
of ox, 98.
magnum, 45.

Bones, magnum, of pig, 101.
malar, 76.
of dog, 93.
of ox, 89.
of pig, 91.
malleus, 420.
maxillary superior, 73.
of dog, 93.
of ox, 89.
of pig, 91.
inferior, 80.
of dog, 94.
of ox, 90.
of pig, 92.
inter or anterior, 75.
of dog, 93
of ox, 89
of pig, 91.
sinus, 86.
metacarpal, 46.
of dog, 104.
of pig, 101.
os metacarpi magnum, 47.
of ox, 98.
ossa metacarpi parvi, 48.
nasal, 72.
fossæ, 86.
of dog, 93.
of ox, 89.
of pig, 91.
navicular of carpus, 52.
number of, 14.
occipital, 62.
of dog, 92.
of ox, 88.
of pig, 90.
palate, 77.
of dog, 93.
of ox, 89.
[illegible]
[illegible]
[illegible]
[illegible]
[illegible]
[illegible]
[illegible]
[illegible]
phalangeal of fore limb, 50.
of hind limb, 61.
of dog, 103.
of pig, 101.
pisiform, 46.
pterygoid, 78.
of dog, 94.
pubic, 30.
of ox, 97.
radius, 40.

Bones, radius, of dog, 103.
of ox, 98.
of pig, 100
ribs, 33.
of dog, 103.
of ox, 96.
of sheep, 96.
peculiarities of some, 35.
sacrum, 25.
of dog, 102.
of ox, 95.
of pig, 100.
scaphoid of carpus, 43.
of dog, 103.
of ox, 98.
of pig, 101.
scapula, 36.
of dog, 103.
of ox, 98.
of pig, 100.
semilunar of pig, 101.
sesamoid in fore limb, 50.
in foot, 47.
of dog, 104.
skull of, 62.
as a whole, 82.
spongy bones. *See* Turbinated.
sphenoid, 69.
of dog, 93.
of ox, 88.
of pig, 90.
sphenoidal sinus, 86.
stapes, 420.
sternum, 32.
of dog, 103.
of ox, 96.
of pig, 100.
suffraginis, 49.
tarsal, 57.
of ox, 97.
of dog, 104.
temporal, 66.
squamous, 66.
petrous, 67.
of dog, 92.
of ox, 88.
of pig, 90.
tibia, 56.
of dog, 104.
of ox, 97.
trapezium, 44.
of dog, 103.
of ox, 98.
trapezoid, 45.
of pig, 101
triquetral, 65.
turbinate superior, 79.
of ox, 89.
Bones, turbinate superior, of pig, 92.
inferior, 79.
of ox, 89.
of pig, 92.
ulna, 41.
of dog, 103
of ox, 98.
of pig, 100.
unciform, 46.
of pig, 101.
ungual, 76.
vertebra dentata, 21.
prominens, 21.
vertebræ cervical, 17.
of dog, 101.
of ox and sheep, 94.
of pig, 99.
sixth cervical, 21.
of dog, 101.
of ox, 95.
of pig, 99.
seventh cervical, 21.
of ox, 95.
of pig, 99.
dorsal, 22.
of dog, 102.
of ox, 95.
of pig, 99.
lumbar, 24.
of dog, 102.
of ox, 95.
of pig, 99.
vomer, 78.
of ox, 90.
Wormian, 65.
zygomatic, 76.
Brachial plexus of nerves, 407.
dissection of, 468.
muscles of regions, 190, 191.
veins of, 352.
Brain. *See* Cerebrum and Encephalon.
dissection of, 465.
vessels of, 386.
Brim of pelvis, 31.
Bronchi (*Bronchos*, the windpipe), 295.
dissection of, 460.
position of, at root of lungs, 295
structure of, 295.
vessels and nerves of, 295.
Bronchial artery, 317.
glands, 295.
veins, 343.
Brown-Sequard on narrowing of palpebra fissure on section of sympathetic, 478.
Brunner's glands, 233.
Buccal (*bucca*, the mouth) artery, 340.
nerve, 395.
vein, 354.

Buccinator (*buccina*, a trumpet) muscle, 177.
Bulb, olfactory, 391.
urethra, artery of, 320.
Bull, penis of, 278.
Bursa, 109.
Bursæ, synovial, 109.

Cæcum (i.e., *intestinum cæcum*, the blind gut), 233.
of ox, 254.
Calamus scriptorius, 377.
Calcaneo-cuboid ligament, 127.
metatarsal ligament, 128.
Calcaneum (*calx*, the heel), 58.
Calcification of teeth, 221.
Calf, rachitis in bones of, 3.
Calyces (*kalux*, a cup) of kidney, 261.
Canal, alimentary, 207.
auditory, external, 69.
internal, 424.
inguinal, 138.
lachrymal, 74, 434.
of Petit, 428.
of spinal cord, 372.
spiral, of cochlea, 423.
vertebral, 17.
Vidian, 69.
of Wirsung, 242.
Canaliculi in bone, 5.
Canals of Goertner, 279.
of Havers, 4.
semicircular, of ear, 422.
Cancelli (lattice-work) of bone, 4.
Canine teeth, 219.
Caninus, 177.
Cannon bone, 47
Capillary (*capillus*, a hair) vessels, 313.
Capitulum of Malleus, 420.
Capsular ligament. *See* Ligament.
Capsule, Glisson's, 439.
of lens, 429.
Capsules, supra-renal, 263.
synovial, 109.
Caput (a head) muscles. *See* Muscles.
Caput gallinaginis (woodcock's head), 270.
Cardiac (*kardia*, the heart) artery, 315.
nerves, 311.
orifice of stomach, 229.
[illegible]
Carotid (*karoō*, I cause sleep). *See* Artery, Carotid.
plexus, 415.
Carpal [illegible]. the wrist] arteries. *See* Artery.
ligament. *See* Ligament.
Carpo-metacarpal articulation, 120.
Carpus, articulations of, 119.
bones of, 42.
Carpus, bones of ox, 98.
of pig, 101.
of dog, 103.
Cartilage (*cartilago*, gristle), general [illegible]
tomy of, 106.
articular, 106.
cariniform, 32.
costal, 106.
cricoid, 288.
ensiform, 33.
of epiglottis, 289.
fibro, 107.
circumferential, 107.
connecting, 107.
inter-articular, 107.
stratiform, 107.
membraniform, 106.
reticular, 106.
of septum of nose, 284.
thyroid, 288.
xiphoid, 32.
yellow, 106.
Cartilages, arytenoid, 289.
of bronchi, 295.
cuneiform, 290.
of hoof, 441.
of larynx, 288.
tarsal, of eyelids, 432.
of trachea, 294.
Caruncula (*caro*, flesh) lachrymalis, 433.
Carunculæ myrtiformes, 274.
Cauda equinæ (horse's tail), 472.
Cavities of bones, 5.
of reserve teeth, 221.
posterior, 222.
Cavity, abdominal, 228.
cranial, 82.
glenoid, 36.
pulp, of tooth, 221.
visceral, 228.
Cells, ethmoid, 71.
hepatic, 240.
of nerve substance, 366.
sphenoidal, 71.
Cement of teeth, 217.
Central artery of retina, 340.
Centrum of vertebræ, 15.
ovale majus, 380.
[illegible]
Cephalic vein, 354.
Cerebellar arteries, 387.
veins, 389.
[illegible] brain), 376.
corpus dentatum of, 376.
crura of, 375.
falx of, 370.
fissures of, 376.

Cerebellum, internal structure of, 376.
lobes of, 376.
peduncles of, 375.
tentorium of, 370.
valve of Vieussens in, 376.
ventricle of, 377.
Cerebro-spinal arteries, 386.
Cerebro-spinal axis or centre, 365.
blood-vessels of, 386.
general anatomy of, 366.
membranes of, 368, 369.
fluid, 369.
nerves. *See* Nerves.
Cerebro-spinal branch of occipital artery, 333.
Cerebrum (the brain), 377.
arteries of, 335.
base of, 378.
convolutions of, 378.
commissures of, 377.
crura of, 378.
dissection of, 465.
exterior of, 377.
fibres, ascending or peduncular, 378.
transverse or commissural, 377, 380.
hemispheres of, 378.
internal parts of, 380.
lobes of, 378.
membranes of, 370.
peduncles of, 378.
sulci of, 377.
veins of, 388.
ventricles of, 384.
Cerumen (*cera*, wax), 419.
Cervical (*cervix*, a neck) arteries, 386.
nerves, 402.
plexus, 402, 414.
trapezius, 147.
Cervico-facial muscles. *See* Muscles.
Cervix, or neck, of bladder, 262.
uteri, 275.
Chambers of eye, 429.
Chamois, bones of, 3.
Cheeks, 208.
of ox and sheep, 245.
Chemical composition of the different solids and fluids. *See* under the several titles of these.
Choledochus (*chole*, bile; *dechomai*, I receive) duct, 241.
Chondro-costal articulations, 116.
Chorda tympani, 397.
Chordæ tendineæ, 305.
Chords, vocal, 293.
Choroid (*chorion*, the choroin or investing membrane of the fœtus; *eidos*, shape) plexus, 383.
Choroid plexus of lateral ventricles, 383.
tunic of eye, 426.
pigment cells of, 427.
structure of, 426.
Chyle (*chulos*, juice), 207, 231.
Chylification, 207.
Chymification, 207.
Ciliary (*cilium*, an eyelash) arteries, 339.
canal, 427.
ligament, 427.
processes, 427.
vessels of, 427.
Ciliated epithelium, 286.
Circle of Willis, 387.
Circulation of blood, 302.
in the brain, 386.
fœtal, 355.
organs of, 300.
dissection of, 461.
Circumflexus (*circum*, around; *flecto*, I bend). *See* Artery, Muscle, Nerve, and Vein.
Classification of cranial nerves according to their distribution and function, 390.
Clavicle of dog, 103.
of cat, 103.
Clitoris (*clitoris*, perhaps from *cleio*, I enclose), 274.
of cat, 280.
erectile tissue of, 274.
prepuce of, 274.
Coagulation (*coagulum*, a clot) of blood, 282.
Coccygeal (*coccyx*) artery, 321.
nerves. *See* Nerve.
Coccyx (*kokkux*, a cuckoo), 27.
of ox, 96.
of pig, 100.
Cochlea (*kocklos*, a shell-fish, with a spiral shell), 423.
central column of, 423.
nerves of, 398.
scalæ of, 423.
spiral canal of, 423.
Cœliac (*koilia*, the abdomen) artery or axis, 318.
Coffin bone, 50.
joint, ligaments of, 123.
Colic (*kolon*, the colon or large intestine) arteries, 319.
Colon (*kolon*, originally limb), 234.
arch of, 235.
flexuses of, 235.
Colostrum or beastling milk, 283.
Colt, teeth of, 224.
Columella cochleæ, 423.
Column, vertebral, 15.
of ox and sheep, 94.
of pig, 99.

Column, vertebral, ligaments of, 112.
Columnæ carneæ (fleshy columns), 305.
Columns of spinal cord, 372.
Commissura trochoides, 111.
Commissure (*con*, together; *mitto*, I send) cerebral, 380.
of frog of hoof, 440.
optic, 391.
of third ventricle, 384.
Communicating arteries of brain, 334, 335.
Compact tissue of bone, 5.
Comparative osteology, 87.
Complexus muscles, 148.
Compressor (*con*, together; *premo*, I press). *See* Muscles.
Concha (*konyché*, a shell), 419.
Conduit, parieto-temporal, 67.
Condyle (*kondulos*, a knuckle). *See* various Bones.
Condyles of femur, 54.
of humerus, 39.
of lower jaw, 80.
of occipital bone, 63.
Condyloid portions of occipital bone, 63.
Conjunctiva (*con*, together; *jungo*, I join), 432.
Connecting fibro-cartilage, 108.
Constrictor (*con*, together; *stringo*, I draw tight). *See* Muscles.
Contractility of arteries, 313.
muscular, 129.
Convolutions (*con*, together; *volvo*, I roll) of brain, 377.
Coraco-muscles, 189.
Coracoid (*korax*, a raven; *eidos*, shape) process of scapula, 37.
Cord, artery of, 322.
genital, 266.
gubernacular, 266.
spermatic. *See* Spermatic Cord.
spinal. *See* Spinal Cord.
Corium (skin), 435.
blood-vessels of, 435.
nerves of, 435.
papillæ of, 435.
structure of, 435.
Cornea (*corneus*, horny), 425.
elastica, 426.
propria, 426.
structure of, 426.
Cornua of hyoid bone, 82.
[illegible] 26.
Cornua of ventricles of brain, 380.
Coronal suture, 83.
Coronary arteries. *See* Arteries.
border of hoof, 438.
ligament, 230.
of hoof, 443.
Coronary plexus. *See* Plexus.
veins, 353.
vessels, 315.
Coronet bone, 50.
Coronoid fossa of humerus, 39.
Corpora albicantia, 379.
Arantii, 306.
cavernosa penis, 271.
trabeculæ of, 272.
geniculata, 384.
olivare, 374.
Morgagni, 306.
nigra of iris, 428.
quadrigemina, 384.
restiforme, 375.
striata, 382.
Corpus albicans, 379.
callosum, 377, 380.
fibres of, 380.
peduncles of, 380.
ventricle of, 380.
dentatum of cerebellum, 376.
fimbriatum, 382.
Highmorianum, 269.
luteum, 278.
Corpuscles (*corpusculum*, pl. *-a*, dim. from *corpus*, a body) of blood, red, 300.
red, proportion of, in blood, 300.
shape and size of, 300.
structure of, 300.
pale, 301.
Malphighian of kidney, 260.
of spleen, 243.
of nervous substance. *See* Nerve Cells.
Cortical substance of kidney, 260.
of lymphatic glands, 357.
Costæ or ribs, 33.
Costal cartilages, 33.
muscles, 153.
Costalis, 159.
Costo-abdominalis, 136.
Costo-muscles, 136, 145, 155, 153.
Costo-sternal ligaments, 116.
in ox, 116.
Costo-transverse ligaments, 116.
Costo-vertebral ligaments, 115.
Cotunnius, liquor of, 423.
Cotyloid (*kotale*, a cup; *eidos*, shape) cavity and notch, 30.
ligament, 123.
Cowper's glands, 269.
of ox, sheep, and ruminants generally, 278.
of dog and cat, 280.
Cranial nerves, classification of, 390.
dissection of, 467.

Cranial nerves, functions of, 390.
first pair, 391.
second pair, 391.
third pair, 392.
fourth pair, 392.
fifth pair, 392.
sixth pair, 396.
seventh pair, 396.
eighth pair, 398.
ninth pair, 398.
tenth pair, 398.
eleventh pair, 398.
twelfth pair, 401.
Cranial sinuses, 389.
Cranio-vertebral cavity, development of, 85.
Cranium (*kranion*, the skull), 62.
Cremasteric fascia, 266.
Crest of bone, 10.
external occipital, 63.
palatine, 78.
Cribriform (*cribrum*, a sieve; *forma*, shape) lamella of ethmoid bone, 71.
Crico-arytenoid muscles, 291.
Cricoid (*krikos*, a ring; *eidos*, shape) cartilage, 288.
Crico-thyroid ligaments, 292.
muscles, 290.
Crista galli (cock's comb), 71.
Croup, muscles of region of, 165.
Crucial (*crux*, a cross) ligaments, 125.
Crura of corpora cavernosa, 272.
cerebri, 378.
grey matter of, 378.
cerebelli, 375.
of diaphragm, 170.
of fornix, 382.
Crural nerve, 410.
region, muscles of anterior, 162.
posterior, 167.
Crureus muscle, 164.
Crusta petrosa, 217.
Crypts of Lieberkühn, 233.
Crystalline (*krustallos*, ice or crystal) lens. *See* Lens.
Cubital artery, 328.
nerve, 408.
Cuboid (*cubos*, a cube; *eidos*, shape) bone, 59.
of ox, 97.
Cul-de-sac of stomach, 229.
Cuneiform (*cuneus*, a wedge; *forma*, a shape) bones of fore foot, 43.
bones of hind foot, 60.
of ox, 98.
cartilages, 290.
Cupola, 64.
Curvator coccygis, 184.
Cuticle (*cutis*, the skin), 434.
Cuticle of enamel, 216.
Cutis vera (true skin). *See* Corium and Skin.
Cylinder axis. *See* Axis, Cylinder.
Cylindrical bones, 7.

Dartos (*dartos*, the skin of scrotum; *dero*, I flay), 266.
Decussation (*decusso*, I cut crosswise) of optic nerves, 391.
of pyramids, 373.
De Graaf, vesicles of, 278.
Defecation, 207.
Deglutition, 207, 228.
Dental arches, 217.
artery, 338.
Dentine (*dens*, a tooth), 216.
development of, 220.
secondary, 216.
Depressions on bones, 10.
Depressor. *See* Muscles.
Derma (*derma*, skin), 435
Descent of testicle, 266.
Diaphragm (*dia*, between; *phrasso*, I fence) 170.
of ox, 204.
Diaphragmatic artery, 317.
nerve, 407.
vein, 344.
Diapophysis (*dia*, apart; *apophysis*), 470.
Diarthrosis (*dia*, between; *arthron*, a joint), 111.
Digastric (*dia*, twice; *gaster*, a belly) muscle, 180.
Digestion, organs of, 207.
dissection of, 456.
physiology of, 207.
Dilatator. *See* Muscles.
Dissection, 445.
articulations, 445.
circulatory organs, 461.
anterior tibial, 463.
arteries, 463.
head, 463.
heart, 461.
injection of arteries, 461.
of extremities, 462.
of capillaries, 463.
of veins, 464.
internal iliac, 463.
pericardium, 461.
popliteal, 463.
preparation of arteries, 461.
pulmonary, 463.
digestive organs, 456.

Dissection, digestive organs—
accessory, 459.
fauces, 458.
intestine, 459.
mouth, 456.
œsophagus, 458.
palate, 456.
parotid gland, 457.
pharynx, 458.
stomach, 458.
submaxillary gland, 457.
tongue, 457.
velum palati, 457.
lymphatic system, 464.
injection of, 464.
thoracic duct, 464.
muscles, 446.
abdominal, inferior, 451.
anterior extremity, 453.
axillary, 451.
brachial, anterior, 453.
posterior, 454.
buccinator, 450.
costal, 451.
croup, 455.
crural, anterior, 455.
internal, 456.
posterior, 455.
diaphragmatic, 452.
fore-arm, 454.
general directions as to, 446.
gluteal, 455.
head, 450.
hyoid, 450.
inferior cervical, 449.
labial, 450.
legs, 456.
masseteric and temporo-maxillary, 450.
order in which to dissect, 447.
panniculus carnosus, 448.
posterior extremity, 455.
rules to be observed in dissection of, 447.
scapular, external and internal, 453.
spinal of back and loins, 449.
sublumbar and inferior lumbar, 449.
superior cervical, 448.
nervous system, 465.
brachial plexus, 468.
brain, 465.
cranial nerves, 467.
lumbo-sacral plexus, 468.
Dissection, nervous system—
spinal cord, 465.
sympathetic, 469.
respiratory organs, 460.
bronchial tubes, 460.
larynx, 460.
lungs, 460.
nasal cavities, 460.
urinary organs, 460.
Dog, for anatomy of, see under various organs, such as bones, &c.
Dorsal artery. *See* Artery.
ligaments. *See* Ligament.
muscles. *See* Muscles.
nerves. *See* Nerves.
veins. *See* Veins.
vertebræ, 22.
of ox, 95.
of pig, 99.
of dog, 102.
Dorso-muscles, 148, 149, 151, 152, 153.
Drum of ear, 420.
Duct bile, common, 241.
Bartholini of, in dog, 214.
hepatic, 240.
nasal, 286.
pancreatic, 242.
parotid, 213.
of Rivinius, 214.
Steno's, 213.
thoracic, 258.
Wharton's, 213.
Ducts of glands. *See* various Glands.
of Bellini, 261.
biliary, 240.
ejaculatory, 268.
galactophorous, 281.
of kidney, 261.
seminal, 268.
of sweat-glands, 436.
Ductus ad nasum, 286.
arteriosus, 355.
closure of, 436.
communis choledochus, 241.
et pancreaticus, 241.
valve of, 241.
venosus, 356.
Duodenal branch of hepatic artery, 318.
Duodenum (*duodeni*, twelve, from being twelve finger-breadths in length), 232.
position of, 232.
Dura mater of brain, 369.
of spinal cord, 368.
structure of, 368.

Ear, 419.
external, 419.

Ear, external, auditory canal of, 419.
structure of, 419.
internal, 422.
membranous, 423.
osseous, 423.
middle, 419.
bones of, 420.
ligaments and muscles of, 171, 421.
Ear-wax, 419.
Efferent nerves, 368.
Ejaculatory ducts, 269.
Elastic lamina of cornea, 426.
tissue, 108.
in arteries, 313.
Elbow, ligaments of, 118.
movements of, 118.
Eminences of bones, 9.
Eminentia pyramidalis, 422.
Enamel membrane, 221.
of teeth, 216.
development of, 221.
Enarthrosis (*en*, in; *arthron*, a joint), 111.
Encephalon (*en*, in; *kephale*, the head), 374.
blood-vessels of, 386.
grey matter of, 377.
internal structure of, 378.
membranes of, 369.
primary divisions of, 374.
weight of, 373.
Endocardium (*endon*, within; *kardia*, the heart), 309.
Endolymph (*endon*, within; *lympha*, water), 424.
Ensiform (*ensis*, a sword; *forma*, shape), cartilage, 33.
Entomosome (*entomos*, cut in pieces; *soma*, body), 471.
Epicondyle (*epi*, on; *condyle*), 38.
Epidermis (*epi*, on; *derma*, the skin), 434.
Epididymis (*epi*, on; *didumos*, a testacle), 267.
canal of, 268.
Epiglottis (*epi*, on; *glottis*), 289.
Epipophysis (*epi*, on; *apophusis*), 470.
Epithelium (*epi*, on; *thallo*, I grow) of air passages, 286.
alveoli of lungs, 298.
arachnoid, 371.
arteries, 313.
bile-ducts, 241.
choroid, 427.
endocardium, 309.
Eustachian tube, 422.
Fallopian tube, 277.
of intestines, 232.
of larynx, 293.
Epithelium of œsophagus, 227.
of stomach, 231.
trachea, 294.
of tubuli of stomach, 231.
tympanum, 422.
ureters, 262.
urinary bladder, 263.
uterus, 276.
ventricles of brain, 381.
villi of intestine, 233.
Epitrochlea (*epi*, on; *trochlea*), 38.
Erectile Tissue of penis, 272.
Erector. *See* Muscles.
Ethmoid (*ethmos*, a sieve; *eidos*, shape), bone, 71.
of ox, 88.
of pig, 90.
of dog, 93.
Eustachian tube, 421.
valve, 304.
Extensor. *See* Muscles.
Extostosis, 6.
Extremities. *See* Limbs.
Eye, 424.
appendages of, 431.
aqueous humour of, 429.
ball or globe of, 424.
chambers of, 429.
ciliary muscle, 427.
circular sinus, 428.
coats of, external, 425.
middle, 426.
lachrymal apparatus, 433.
lens of, 429.
membranes, 425.
of capsule of lens, 429.
choroid, 426.
conjunctiva, 423.
cornea, 425.
iris, 427.
Jacob's, 428.
pigment, 427.
pupillary, 428.
retina, 428.
Ruysch's, 426.
sclerotic, 425.
zonula ciliaris, 428.
muscles, moving the, 429.
nerve of. *See* Nerve, optic, and Retina.
refractory media of, 429.
shape and size of, 424.
tunics of, 425.
vitreous body of, 429.
Zonula of Zinn, 428.
Eyebrows, 431.
Eyelashes, 431.
Eyelids, 431.

Eyelids, cartilage of, 432.
conjunctiva of, 423.
glands of, 432.
muscles of, 174.
structure of, 432.
Eye-teeth, 219.

Face, bones of, 72.
muscles of, 175.
veins of, 353.
Facial artery, 336.
muscles of region of, 175.
nerves, 346.
Fallopian tubes, 277.
epithelium of, 277.
fimbriæ of, 277.
function of, 277.
position of, 277.
structure of, 277.
Fallopius, aqueduct of, 68.
ligament of, 138.
False vertebræ, 17.
Falx cerebelli, 370.
cerebri, 370.
Fang of tooth, 215.
Fascia (a band), 130.
abdominal, 136.
cremasteric, 266.
deep, 130.
infundibuliform, 266.
intercolumnar, 266.
investing, 130.
Fasciculi of muscle, 132.
unciformis, 378.
Fat in joints, 110.
Fauces (the throat), 209.
dissection of, 458.
isthmus, 209.
pillars of, 209.
Female generative organs, 273.
Femoral artery. *See* Artery.
nerve, 410, 411, 412.
region, muscles of, 160.
veins, 346, 349.
Femoro-tibial ligaments, 124.
Femur, 53.
of ox, 97.
of pig, 101.
of dog, 104.
Fenestra (a window or opening) ovalis, 421.
rotunda, 421.
Ferrein, pyramids of, 261.
Fetlock joint, ligaments of, 121.
Fibres, axial, of nerve tubes, 366.
of cerebellum, 376.
of cerebrum, 377.
dental, 216.
of lamellæ of bone, 5.
Fibres, of medulla oblongata, 374.
of muscle, 132.
structure of, 132.
of nerve-tissue. *See* Nerve-Fibre.
of roots of spinal nerves, 401.
Fibre-cells of involuntary muscle, 133.
Fibril (dim. of *fibra*, a fibre) of muscle, 132.
Fibrin (*fibra*, a fibre), 301.
of blood, 301.
in rinderpest, 301.
in typhoid disease, 301.
Fibro-cartilage, 107.
intervertebral, 112.
varieties of, 107.
Fibrous structure of heart, 309.
tissue, 108.
Fibro-vascular layer of corium, 435.
Fibula (a brace, a clasp), 57.
of ox, 97.
of dog, 104.
Filaments of areolar tissue, 133
of fibrous tissue, 130.
Filiform papillæ of tongue, 211.
Filum terminale of spinal cord, 369.
Fimbriæ (fringes) of Fallopian tube, 277.
Fimbriated (fringed) extremity of Fallopian tube, 277.
Fish, bones of, 3.
Fissiparous (*findo*, I cleave; *pario*, I produce) generation, 264.
Fissura palpebrarum, 431.
oris, 208.
Fissure of cerebellum, 376.
of cerebrum, longitudinal, 377.
longitudinal, of liver, 237.
mastoid, 68.
portal, 240.
sphenoidal, 87.
Sylvian, 378.
transverse, of liver, 237.
Vidian, 69.
Fissures of liver, 237.
of medulla oblongata, 374.
of spinal cord, 372.
Flat bones, 8.
Flexor. *See* Muscles.
Flexure, diaphragmatic, of colon, 235.
pelvic, of colon, 235.
substernal, of colon, 235.
Fluid, cerebro-spinal, 369.
prostatic, 269.
Foal, rachitis in bones of, 3.
bladder in, 263.
bones of, 7.
teeth of, 223.
Fœtus, circulation in, 355.
peculiarities of heart in, 355.

Follicle (*folliculus*, dim. of *follis*, a bag) of eyelids or ciliary, 432.
of hair, 436.
Follicles, closed, of intestines, 233.
lenticular, of stomach, 231.
of teeth, 220.
Follicular stage of development of teeth, 220.
Foot, articulations of, 119, 127.
bones of, 42, 48.
dissection of, 454.
muscles of, 193, 200.
nerves of, 409, 412.
vessels of, 424, 430, 431.
Foramen (*foro*, I pierce) cæcum of medulla oblongata, 374.
dental, 74.
inferior, 80.
dextrum of diaphragm, 170.
lacerum orbitale, 70.
magnum, 63.
mastoid, 67.
of Monro, 382.
obturator, 31.
optic, 70.
ovale of heart, 304.
closure of, 356.
vestige of, 304.
of pelvis, 31.
palato-maxillary, 74.
pathetici, 70.
pterygoid, 69.
rotundum, 70.
sinistrum of diaphragm, 170.
spheno-palatine, 74.
staphyline, 77.
stylo-mastoid, 69.
of a vertebra, 16.
Foramina of right auricle, 304.
condyloid, anterior, 63.
dental, 74.
of diaphragm, 170.
of ethmoid bone, 71.
Morgani of, in tongue, 210.
palatine, anterior and posterior, 73, 74.
Thebesii, 304.
Fore-limb, articulations of, 118.
bones of, 40.
dissection of, 453.
muscles of, 185, 193.
nerves of, 408.
vessels of 327.
Formula of teeth. *See* TEETH.
Fornix (an arch or vault), 381.
Fossa basilar of occipital, 64.
cavernous, 70.
glenoid, 37.
lachrymal, 77.
Fossa nasal, 72, 86.
ovalis of heart, 304.
pituitary, 70.
sphenoidal, 70.
supra-condyloid of femur, 54.
temporal, 84.
trochanteric, 54.
Fossæ, ethmoidal, 71.
nasal, 86.
Fovea (a pit or depression) elliptica, 422.
hemispherica, 422.
Fræna (pl. of *frænum*, a bridle) of lips, 208.
Frænum epiglottidis, 210.
labii, 208.
linguæ, 210.
Frog, artery of the, 321. *See* HOOF.
veins of, 347.
Frontal (*frons*, the forehead) bone, 65.
of ox, 87.
of pig, 90.
of dog, 92.
lobe of cerebrum, 378.
nerve, 393.
sinus, 86.
suture, 82.
Fronto-nasal suture, 83.
Fronto-superciliaris, 174.
Fundus (the bottom of anything) of bladder, 262.
stomach, 229.
uterus, 275.
Fungiform (*fungus*, a mushroom; *forma* shape) papillæ of tongue, 211.
Furrows of heart, 302.

Galactophorus (*gala*, milk; *phero*, I carry) ducts, 281.
Gall-bladder, 241.
dog, in, 258.
GANGLIA lymphatic, 359, 360, 364, 365.
of sympathetic nerves, 413, 414, 415.
Gangliated cord, sympathetic, 413.
cervical part, 414.
lumbar part, 418.
sacral part, 419.
thoracic part, 416.
GANGLION, Andersch's, 398.
Arnold's, 414.
brachial lymphatic, 365.
cervical, middle, 416.
inferior, 415.
superior, 414.
of fifth pair, or Gasserian, 393.
guttural, 414.
iliac lymphatic, 360.
inguinal, deep, lymphatic, 359.
superior, lymphatic, 360.
jugular, 399.

Ganglion, lenticular, 413.
Meckel's, 413.
ophthalmic, 413.
otic, 414.
petrosal, 398.
pharyngeal, lymphatic, 364.
popliteal, lymphatic, 360.
precrural, lymphatic, 360.
prepectoral, lymphatic, 364.
prescapular, lymphatic, 364.
sublumbar, lymphatic, 359.
semilunar (syn. of the ophthalmic or lenticular ganglion), 417.
submaxillary of sympathetic, 414.
submaxillary, lymphatic, 364.
Gasserian ganglion, 393.
Gastric (*gaster*, the stomach) artery, 318.
Gastrocnemius (*gaster*, the belly; *knemē*, the leg) muscles, 201, 202.
Gastro-colic (*gaster*, the stomach; *kolon*, the colon) omentum, 230, 244.
Gastro-epiploic (*gaster*, the stomach; *epiploon*, the omentum) arteries, 318.
veins, 345.
Gastro-hepatic (*gaster*, the stomach; *hepar*, the liver) omentum, 230, 244.
Gastro-phrenic (*gaster*, the stomach; *phrēn*, the diaphragm) ligament, 230.
Gastro-splenic (*gaster*, the stomach; *splēn*, the spleen) omentum, 230, 244.
Gelatinous nerve-fibres, 366.
Gemini, 169.
Gemmiparous generation, 264.
Generation, varieties of, 264.
Generative organs, female, 273.
male, 265.
Genio-hyo-glossus (*geneion*, the chin; *glossa*, the tongue) muscle, 183.
Genio-hyoid (*geneion*, the chin; *huoeidēs*, bone) muscle, 180.
Genital cord, 266.
Genu (a knee) of the corpus callosum, 380.
Ginglymus (*ginglumos*, a hinge), 111.
Gland or Glands.
Brunner's, 233.
buccal, 208.
ceruminous, 419.
Cowper's, 269.
gastric, lenticular, 231.
tubular, 231.
of Harderi in pig, 433.
kidney. *See* Kidney.
lachrymal, 433.
[illegible]
mammary, [illegible]
Meibomian, 431.
molar, 208.
Gland, pancreas. *See* Pancreas.
parotid. *See* Parotid.
peptic, 231.
of Peyer, 233.
pineal, 384.
pituitary, 378.
of prepuce, 271.
prostate. *See* Prostate.
salivary, 212.
functions of, 212.
sebaceous, 436.
of skin, 436.
small intestine, 233.
solitary, 233.
sublingual, 213.
submaxillary, 213.
sudoriferous, 436.
supra-renal, 263.
thymus. *See* Thymus.
thyroid. *See* Thyroid.
Glands, Lymphatic, general anatomy of, [illegible]
Descriptive anatomy, [illegible]
cervical, 365.
iliac, 360.
inguinal, 360.
lumbar, 359.
mediastinal, 362.
precrural, 360.
of thorax, 362
Glandulæ ceruminosæ, 419.
odoriferæ, 274.
solitariæ of the intestines, 233.
Glans (an acorn) penis, 272.
Glenoid (*glene*, a shallow pit of a [illegible] *eidos*, shape) cavity of scapula, [illegible]
of radius, [illegible]
fossa of temporal bone, 67.
Glisson's capsule, 439.
Globus major and minor of the epididymis, 267.
Glossal muscles, region of, 182.
Glosso-epiglottic (*glossa*, the tongue; [illegible] *glottis*) folds or frænula, 210.
Glosso-facial artery, 325.
veins, 353.
Glosso-pharyngeal (*glossa*, the tongue; [illegible] *ryngx*, the pharynx) nerve, 395.
Glottis (*glottis*, a tongue), 289.
Glutæus (*gloutos*, the buttock). *See* [illegible]
Gluteal artery, 321.
muscles, 185.
nerves, 411.
Goertner, canals of, 279.
Gomphosis (*gomphos*, a nail), 111.
Goodsir on development of teeth, 220.
on nature of limbs, 471.
Goodsir's nomenclature of vertebral elements, 471.

Graafian vesicles, 278.
Gracilis (slender) muscle, 160.
Grey matter of cerebellum, 376.
of cerebrum, 378.
medulla oblongata, 372.
pons Varolii, 375.
spinal cord, 373.
Gristle, 106.
Groove intercondyloid, 55.
longitudinal of parietal, 64.
palatine, 73.
Gubernaculum (*guberno*, I steer or guide) testis, 266.
Gullet, 227.
Gums, 208.
Gurlt on muscular fibres in orbital membrane, 476.
Gustatory (*gusto*, I taste) nerves, 395.
Guttural (*guttur*, the throat) pouches, 424.
Gyri (*guros*, a ring) of brain, 380.
operte (covered convolutions), 378.
Gyrus fornicatus (arched convolution), 380.

Hæmal (*haima*, blood) arch, 470.
spine, 470.
Hæmapophysis (*haima*, blood; *apophysis*), 470.
Hæmorrhoidal (*haima*, blood; *rheo*, I flow) artery. *See* Artery.
nerves. *See* Nerves.
Hairs, 435.
cuticle of, 435.
distribution of, 435.
follicles of, 436.
growth of, 436.
medulla or pith of, 436.
root of, 436.
stem of, 436.
Hamulus (dim. of *hamus*, a hook) of cochlea, 423.
Harden's gland in eye of pig, 433.
Harmonia (*harmoso*, I fit together), 82.
Haunch bone, 53.
Haversian canals, 4.
spaces, 5.
Haw of the eye, 432.
Head, bones of, 62.
dissection of arteries of, 463.
muscles of, 171.
of a bone, 10.
Heart,
annalus ovalis, 304.
arteries, 311.
auricles of, 303, 307.
fibres of, 310.
left, 307.
right, 303.
septum, 304.
Heart, auricles of, position of, 303, 307.
auriculæ or auricular appendage of, 303.
bone of, in ox, 309.
cavities of, 302.
chordæ tendineæ of, 305.
circulation, course of, in, 302.
columnæ carneæ, 305.
corpora aurantii, 306.
course of circulation in, 302.
covering of, 301.
cyanosis, cause of, 304.
dissection of, 461.
endocardium of, 308.
external form of, 303.
fibrous rings of, 309.
structure of, 309.
fœtal, 355.
foramina of. *See* Foramen and Foramina.
form of, 302,
fossa ovalis of, 304.
furrow auriculo-ventricular, 302.
isthmus, longitudinal, 302.
Vieussenı, 304.
length of, 302.
lining membrane, 308.
lymphatics of, 311.
muscular fibres of, 309, 310.
musculi papillares of, 305.
pectinati of, 305.
nerves of, 311.
orifices of aortic, 308.
auriculo-ventricular, left, 307, 308.
right, 304.
pulmonary, 306.
of venæ cavæ, 303.
position of, in the chest, 302.
septum auricular, 303.
fibres of, 303.
ventricular, 308.
serous coat, 302.
sinus coronary, 303.
Valsalva of, 306.
venosus, 303.
structure of, 309.
tubercle of Lower, 304.
valves of auriculo-ventriculo, 305 308.
left, 308.
right, 305.
Eustachian, 304.
mitral or bicuspid, 308.
sigmoid or semilunar, 306. 308.
left, 308.
right, 306.

Heart, valves of, Thebesian, 304.
tricuspid, 305.
veins of, 311.
ventricles in general, 305, 308.
fibres of, 310.
septum of, 308.
ventricle of left, 307.
walls of, 307.
right, 305.
walls of, 305.
weight of, 302.
Heel, 58.
Helicotrema (*helix*, a spiral; *trema*, a hole), 432.
Hepatic (*hepar*, the liver) artery, 240, 318.
cells, 240.
duct, 240.
vein, 240, 344.
Hermaphrodite reproduction, 264.
Hiatus (an opening, from *hio*, v. n., I open) external orbital, 69.
maxillary, 74.
optic, 70.
Hilus (or *hilum*, the mark or scar on a bean) of kidney, 260.
of lymphatic glands, 260.
Hind limb, bones of, 51.
muscles of, 160.
Hip joints, 123.
ligaments of, 123.
movements of, 124.
Hippocampi, fissure of, 382.
tænia (band of the hippocampus), 382.
Hippocampus (*hippocampos*, from *hippos*, a horse, and *kampto*, I bend, a coiled sea animal) major, 382.
Hock, bones of, 57.
ligaments of, 126.
Homologues of upper and lower limbs, 470, 471.
of vertebræ, 469.
Homology (*homos*, the same; *logos*, proportion), the doctrine of similarity of structure; *e.g.*, the fore limb of a horse and the wing of a bird are homologous, in opposition to analogy, or analogous (*ana*, again; *logos*, a portion), one part of an organised being having the same function as another part in another organised being, *e.g.*, the wing of a bird and the wing of an insect are analogous, not homologous, 469, 471.
Hoof, bars of, 438.
bones of, 441.
cartilages of, 441.
commissures of frog of, 440.
Hoof, coronary border of, 438.
frog band, 440.
ligament, 442.
fatty frog of, 442.
frog of, 439.
cleft of, 439.
stay of, 439.
toe of, 440.
heels of, 438.
of frog of, 440.
horn of, 440.
fibres of, 440.
lamellæ of, 440.
pigmentary matter of, 440.
tubes of, 440.
villi of, 440.
laminæ of, 438.
sensitive, 443.
parts within the, 441.
quarters of, 437.
sensitive frog of, 442.
laminæ, 443.
sensible sole of, 443.
shape of, 437.
sole of, 438.
sensitive, 443.
toe of, 437.
wall of, 437.
Horn of hoof. *See* Hoof.
core in ox, 81.
Humeralis. *See* Muscles.
Humeral region, muscles of, 189.
artery, 328.
vein, 352.
nerve, 408.
Humero-radio-ulnar articulation, 118.
Humero-muscles. *See* Muscles.
Humerus, the shoulder, 38.
of dog, 103.
of ox, 98.
of pig, 100.
Humour, aqueous, 429.
crystalline, 429.
vitreous, 429.
Hymen (*hemen*, a membrane), 274.
Hyoglossus (*huoides*, *hyoid*, bone; *glossa*, tongue) muscle, 182.
Hyoid (*υ*, the letter upsilon; *eidos*, shape) bone, 81.
of ox, 90.
of pig, 92.
of dog, 94.
ligaments of, 117.
of ox, 118.
muscles of, 180.
Hyoideus-muscles. *See* Muscles.
Hypochondriac region. *See* Abdomen.
Hypogastric region. *See* Abdomen.

Hypoglossal (*hupo*, under; *glossa*, the tongue) nerve, 401.
Hypopophysis (*hupo*, under; *apophusis*) cerebri, 470.

Ileo-Cæcal artery, 319.
Ileum (*eileo*, I roll). *See* Intestine, small.
position of, 232.
Iliac arteries. *See* Artery.
dissection of, 463.
veins. *See* Veins.
Iliaco-femoral artery, 321.
Iliacus (*ilia*, the flank) muscle, 159.
Ilio-abdominalis, 138.
Ilio-muscles. *See* Muscles.
Ilio-muscular nerve, 411.
Ilium (*ilia*, the flank), 28.
of ox, 96.
of sheep, 96.
Incisor teeth, 217.
eruption of. *See* Teeth.
Incissura ethmoidalis, 65.
Incus (an anvil), 420.
Inferior abdominal region, muscles of, 135.
cervical region, muscles of, 142.
Infra-orbital artery, 340.
Infundibula (funnels) of kidney, 261.
Infundibulum of brain, 379.
Inguinal (*inguen*, the groin) artery, 323.
Injection. *See* Dissections.
Inlet of pelvis, 31.
Innominate artery, *See* Artery.
bone, 27.
of ox and sheep, 96.
of pig, 101.
of dog, 104.
ossification, 27.
Inter-articular fibro-cartilages and ligaments. *See* the various Joints.
Inter-cervicalis muscles, 151.
Intercolumnar fascia, 266.
Intercostal arteries. *See* Artery.
muscles, 155.
nerves, 404.
Inter-phalangeal, distal, 124.
proximal, 122.
Inter-maxillary bone, 75.
Intermediate fasciculi of medulla oblongata, 375.
Internal femoral region, muscles of, 160.
Inter-osseous arteries. *See* Artery.
ligament. *See* Ligaments.
veins. *See* Veins.
Inter-peduncular space, 378.
Inter-spinous ligament, 113.
Inter-transversales muscles, 151.
Inter-transverse ligament, 113.
Inter-vertebral discs, 112.
Intestine, large, 233.
cæcum, 233.
capacity of, 233.
length of, 233.
colon, 234.
capacity and length of, 234.
large, 234.
floating, 236.
flexures of, 235.
dissection of, 459.
divisions of, 234.
dog in, 258.
follicles of, 234.
glands of, 234.
length and extent of, 233, 234.
mucous membrane of, 234, 235.
muscular coat of, 234, 236.
ox, of, 254
pig, in, 258.
position of, 234, 235.
rectum. *See* Rectum.
structure of, 234, 235.
tubuli of, 234.
valve of, 234.
vessels and nerves of, 234.
small, 231.
areolar, coat of, 232.
crypts of, 233.
dissection of, 459.
divisions of, 231.
dog, in, 258.
duodenum, 231.
dilatation of, 232.
epithelium, 232.
function of, 231.
glands of, 233.
agminated or Peyer's, 233.
Brunner's, 233.
crypts of Lieberkühn, 233.
solitary, 233.
ileum, 232.
jejunum, 232.
length and extent of, 231.
mucous membrane of, 232.
muscular coat of, 232.
nerves of, 233.
ox, of, 254.
pig, in, 258.
position of, 232.
serous coat of, 232.

Intestine, small, structure of, 232.
valvulæ conniventes of, 232.
vessels of, 233.
villi of, 233.
Intralobular veins. *See* Liver.
Intra-membranous ossification, 12.
Involuntary muscles, 131.
Iris (*iris*, a rainbow), 427.
colour of, 427.
muscular fibres of, 427, 428.
pigmentary elements, 427.
structure of, 427.
Ischiatic artery, 321.
Ischio-muscles. *See* Muscles.
Ischio-pubic articulation, 117.
Ischium (*ischion*, the hip), 29.
Island of Reil, 378.
Isthmus faucium, 209.
Iter ad infundibulum, 384.
e tertio ad quartum ventriculum, 384.
Ivory of teeth, 216.

Jacob's membrane, 428.
Jacobson's canal in mouth of dog and pig, 256.
nerve, 398.
Jaw, lower, 80.
upper, 73, 75.
Jejunum (*jejunus*, empty). *See* Intestine, small.
position of, 232.
Johnston's *memoria technica* for dentition of domestic animals, 479.
Joint, elbow, 118.
hip, 123.
knee, 124.
occipito-vertebral, 114.
radio-ulnar, 118.
shoulder, 118.
Joints in general, 105.
fat in, 110.
motions of bones, 112.
synovial membranes of, 109.
synovia of, 110.
Jugal bone, 76.
Jugular vein, 352.

Kerato-hyoideus (*keras*, a horn; *cricoid*, cartilage) muscle, 181.
Kidneys, 259.
adipose capsule of, 259.
bear, in, 259.
calyces or infundibula, 261.
coat of, fibrous, 260.
corpuscles of Malphigi, 260.
cortical substance, 260.
Kidneys, excretory duct of, 262.
form of, 259.
hilus or fissure of, 260.
intertubular stroma of, 260.
medullary substance of, 260.
nerves of, 261.
ox, in, 259.
papillæ of, 261.
pelvis of, 260.
position of, 259.
pyramids of Ferrein, 261.
Malphighi, 260.
sheep, in, 259.
sinus of, 260.
structure of, 260.
surfaces and borders of, 260.
tubuli of, 261.
of Bellini, 261.
convoluted, 261.
of Ferrein, 261.
looped, 261.
origin and course of, 261.
straight, 261.
structure of, 261.
vessels of, 261.
distribution of, 261.
Knee joint bones, 42.
broken, 43.
ligaments of, 119.
movements of, 121.
tying in of, 45.
Knuckle bone, 58.

Labial artery, 336.
Labyrinth (*laburinthos*, a maze, from complex structure), 422.
lining membrane of, 425.
membranous, 425.
osseous, 425.
Lachrymal apparatus, 433.
artery, 340.
bone, 76.
of ox, 89.
of pig, 91.
of dog, 93.
canals, 77, 434.
duct, 434.
fossa, 77.
gland, 433, 434.
nerve, 393.
sac, 434.
tubercle, 76.
Lamina cinerea of corpus callosum, 380.
cribrosa of sclerotic, 425.
spiralis of cochlea, 423.
Laminæ of hoof. *See* Hoof.
Laminal arteries, 331.
plexus, 346.

Larynx (*larunyx*, the larynx), 287.
cartilages of, 288.
arytenoid, 289.
cricoid, 288.
cuneiform, 290.
epiglottis, 289.
thyroid, 288.
dissection of, 460.
glottis of, 293.
interior of, 293.
ligaments of, 292.
mucous membrane of, 293.
muscles of, 290.
nerves of, 294, 399.
pouches of, 293.
sinus of, 293.
ventricles or sinuses of, 293.
vessels of, 294.
vocal cords of, 293.
Lateralis sterni, 155.
Latissimus dorsi muscle, 152.
Laxator tympani muscle, 421.
Leg, articulations of, 123.
bones of, 53.
dissection of, 455.
muscles of, 160.
Lens (a lentil) crystalline, 429.
capsule of, 429.
fibres of, 429.
structure of, 429.
suspensory ligament of, 429.
Lenticular (dim. from *lens*) follicles of stomach, 231.
ganglion, 413.
Lacunæ in bone, 5.
Lamboidal (the letter *lambda* shape) suture, 83.
Lamella cribriform, 71.
Lamellæ of bone, 6.
Lamina of a vertebra, 16.
elastic, of cornea, 426.
spiral, of cochlea, 223.
Laminæ or plates of vertebræ, 16.
Levator. *See* Muscles.
Levatores costarum, 154.
Lieberkühn's crypts, 233.
Ligamenta subflava, 113.
in cow, 113.
Ligaments, 108.
bursal, 108.
capsular, 108.
funicular, 108.
general anatomy, 108.
antero-lateral of the distal phalangeal, 123.
antero-carpo-metacarpal, 120.
common of the carpus, 121.
costo-transverse, 116.
Ligaments—*continued*.
antero-carpo-metacarpal—
lateral of the coffin-joint, 123.
of the first row of carpal bones, 119.
of the lower row of carpal bones, 119.
arciform of radio-ulnar, 119.
astragalo-calcaneal, 127.
metatarsal, 127.
calcaneo-metatarsal, 128.
capsular of the articular processes of the vertebræ, 113.
of the axoido-atloid joint, 114.
of the chondro-costal joint, 116
of the coffin joint, 123.
of the costo-sternal joint, 116.
of the costo-vertebral joint, 116.
of the elbow, 118.
of the hip joint, 123.
of the metacarpal-phalangeal, 122.
of the pastern, 123.
of the proximal interphalangeal, 123.
of the shoulder joint, 118.
of the stifle, 124.
of the tarsus, 127.
of the temporo-maxillary articulation, 115.
carpal, 121.
coronary, 125.
cotyloid, 123.
crucial, 125.
cuboido-cuneiform, 127.
interosseous, 127.
metatarsal, 127.
ear of, 421, 422.
external lateral of the carpus, 121.
of the elbow, 115.
tarsal, 126.
of the stifle, 124.
femoro-tibial, 124.
hyoid, 117.
inferior common of the vertebræ, 112.
radiating of radio-ulnar, 119.
sacro-iliac, 117.
sesamoid, 122.
sterno-costal, 116.
suspensory of occipito-atloidean, 114.
interarticular of the vertebro-costal-joint, 116.
of the temporo-maxillary-joint, 115.
intercarpal, 120.

Ligaments, interhyoid capsular, 118.
internal lateral of the carpus, 121.
of the elbow, 118.
tarsal, 126.
of the stifle, 124.
interosseous, 127.
calcaneo-astragaloid, 127.
carpo-metacarpal, 120.
intermetacarpal, 121.
of the first row of carpal bones, 119.
of the lower radio-ulnar joint, 119.
of the navicular joint, 123.
of the tibio-fibular, 126.
of the radio-ulnar joint, 119.
of the stifle, 125.
sacro-iliac, 117.
tarso-metatarsal, 128.
intersesamoid, 122.
interspinous, 113.
intertransverse, 113.
capsular of occipito-atloidean, 114.
metacarpo-phalangeal, 122.
of the first interphalangeal joint, 123.
sesamoid, 122.
styloid, 114.
larynx, of, 292.
maxillæ laterale externum, 115.
posticum, 115.
mucosum, 125.
navicular, 123.
nuchæ, 113.
odontoid, 114.
plantar, 128.
posterior, 121.
common, of the carpus, 121.
costo-transverse, 116.
lateral of coffin, 123.
of the pastern, 123.
pubio-femoral, 124.
radio-carpal, 120.
round of the hip joint, 124.
sacro-sciatic, 117.
semilunar, 124.
stellate, 115.
spinous, superior, 114.
inferior, 114.
superior, 123.
broad ligament of coffin, 123.
carpo-metacarpal, 120.
common, of vertebræ, 112.
sterno-costal, 116.
suspensory of occipito-atloidean, 114.
sacro-iliac, 117.
Ligaments, supra-spinous, 113.
teres of hip joint, 124.
transverse of hip joint, 124.
transverse of the ischio-pubic symphysis, 117.
Ligamentum denticulatum of cord, 369.
mucosum, 125.
teres, 124.
Limb, fore, articulations of, 118.
bones of, 36.
dissection of, 453.
muscles of, 189
hind, articulations of, 123.
bones of, 51.
dissection of, 455.
muscles of, 160.
homologues of, 470.
relation to segments of trunk, 471.
Linea alba, 136.
Lingual artery, 336.
bone, 81.
muscles, extrinsic and intrinsic. *See* Muscles and Tongue.
nerve, 395.
vein, 355.
Lips, 208.
of dog, 255.
of ox, 245.
of sheep, 245.
Liquor Cotunnii, 423.
Morgagnii, 429.
sanguinis, 301.
Scarpæ, 424.
seminis, 268.
Liver, 237.
capillaries of, 239.
cells of, 240.
coats of, 238.
dissection of, 459.
dog, in, 258.
ducts, 240.
commencement of, 240.
excretory apparatus of, 241.
fissure of, 237.
form of, 237.
fossæ of, 237.
function of, 241.
Glisson's capsule of, 239.
hepatic substance of, 239.
ligaments of, 238.
coronary, 238.
right and left lateral, 238.
round, 238.
suspensory, 238.
lobes of, 238.
of Spigelius, 238.
lobule of, 239.
lobulus caudatus, 238.

Liver, lobulus quadratus, 238.
of ox, 254.
pig, in, 258.
position of, 337.
secretion of, 241.
serous coat of, 238.
structure of, 239.
vessels of, 240.
Lobe, central, of cerebellum, 376.
of cerebrum, 378.
frontal, 378.
Lobes of cerebellum, 376.
of cerebrum, 378.
liver, 238.
lung, 297.
Lobules of liver, 238.
of lungs, 297.
Lobulus caudatus, 238.
quadratus, 238.
Spigelii, 238.
Locomotor organs, 36.
Locus niger, 378.
perforatus anticus, 379.
posticus, 379.
Longissimus dorsi, 154.
Longitudinal suture, 82.
Longus colli, 146, 156.
Lower, tubercle of, 304.
Lumbar arteries, 317.
nerve, 405.
plexus, 410.
vein, 345.
vertebræ, 24.
of ox, 95.
of pig, 99.
of dog, 102.
Lumbo-abdominalis, 140.
Lumbo-spinal arteries, 317.
Lumbricales (*lumbricus*, an earthworm) muscles, 204.
of dog, 206.
Lunar bone, 43.
Lungs, 296.
air-cells of, 298.
birds, in, 299.
capillaries of, 297.
colour of, 297.
dissection of, 460.
dog, in, 299.
emphysema (a broken wind), 298.
fissures of, 297.
lobes of, 297.
lobules of, 298.
lymphatics of, 298.
ox, in, 299.
nerves of, 298.
pig, in, 299.
position of, 296.
Lungs, roots of, 296.
ruminants, in, 298.
specific gravity of, 297.
structure of, 297, 298.
surfaces and borders of, 297.
vessels of pulmonary, 298.
bronchial, 298.
Lymph (*lympha*, water), 357.
duct, 358.
Lymphatic system, general anatomy of, 356.
dissection of, 464.
glands, 357.
structure of, 357.
vessels of, 358.
injection of, 464.
vessels, 358.
afferent, 357.
coats of, 358.
efferent, 357.
plexiform, 357.
structure of, 358.
valves of, 358.
vital properties of, 357.
Lymphatics, descriptive anatomy of, 358.
of the abdomen, 359, 361.
back, 363.
cæcum, 361.
cervical, 365.
chest, 363.
colon, 361.
cranium, 363.
diaphragm, 363.
face, 363.
head and neck, 363.
heart, 363.
intestines, large, 361.
small, 361, 362.
anterior limbs, 363, 364.
posterior, 359.
liver, 362.
lungs, 363.
pelvis, 359.
rectum, 361.
spleen, 362.
stomach, 362.
thorax, 363.

Macula cribrosa in vestibule, 422.
Magnum, 45.
Malar (*mala*, the cheek) bone, 76.
of ox, 89.
of pig, 91.
of dog, 93.
Male generative organs, 265.
Malleolus (dim. of *malleus*, a hammer, the ankle), external, 57.
internal, 57.
Malleus (a hammer), 420.

Malleus, ligaments of, 421.
Malphighian corpuscles of kidney, 260.
of spleen, 243.
pyramids of kidney, 260.
Mammary glands in female, 280.
acini of, 281.
in cow, 282.
in dog, 282.
ducts of, 281.
physiology of, 280.
pig, in, 282.
sheep, in, 282.
sinuses of, 281.
structure of, 281.
varieties of, 280.
vessels and nerves of, 281.
Marsupial reproduction, 265.
Manubrium (a handle) of malleus, 420.
Mark on incisor teeth, 224.
Marrow of bone, 7.
spinal. *See* Spinal Cord.
Masseter (*massaomai*, I chew) muscle, 178, 179.
Masseteric (masseter) artery, 337, 338.
nerve, 395.
Mastication, 207.
Mastoid (*mastos*, a nipple; *eidos*, form) artery, 333.
cells, 67.
foramen, 67.
process, 67.
ridge of occipital, 63.
Mastoideus, 147.
Mastoido-muscles. *See* Muscles.
Maxillary (*maxilla*, a jaw) artery. *See* Artery.
bone, inter, 75.
of ox, 89.
of pig, 91.
of dog, 93.
lower, 80.
of ox, 90.
of pig, 92.
of dog, 94.
upper, 72.
of ox, 189.
of pig, 91.
of dog, 93.
muscles. *See* Muscles.
nerve, 394.
sinus, 86.
vein, internal, 354.
Maxillo-labialis, 177.
musculo artery, 337.
Meatus [illegible], 419.
auditory, internal, 68, 424.
of nose, inferior, 79.
Meatus of nose, middle, 79.
superior, 79.
Meckel on muscle in orbit of ox, [illegible] rynchus, 476.
Mediastinum (*medius*, the middle; *sto*, I stand), 296.
Medulla oblongata, 394.
columns, 374.
fissures of, 374.
foramen cæcum of, 374.
grey matter of, 375.
ossium (marrow of bones), 7.
spinalis. *See* Spinal Cord.
Medullary canal of bone, 7.
sheath of nerve fibre, 366.
substance of encephalon, 374.
of kidney, 260.
of lymphatic glands, [illegible]
Medullated nerve fibres, 366.
Meibomian glands, 431.
Membrana granulosa, 278.
nictitans, 432.
in ox, 433.
in pig, 433.
in tetanus, 433.
pupillaris, 428.
tympani, 420.
Membrane arachnoid, of brain, 370.
of spinal chord, 368.
choroid, 426.
Jacob's, 428.
limiting of retina, 428.
lining of osseous labyrinth, 423.
of tympanum, 422.
papillary, 428.
Schneiderian, 286.
Membranes of the Brain and Spinal Cord, 368, 369.
Membrane cochlea, 423.
labyrinth, 423.
semicircular canals, 422.
Meningeal artery. *See* Artery.
Meninges (*meningx*, a membrane), 368, 369.
Mental (*mentum*, the chin) nerve, 396.
Mesenteric veins, 345.
Mesentery (*mesos*, middle; *enteron*, intestine), 244.
Mesocæcum (*mesos*, middle; cæcum), 244.
Mesocolon (*mesos*, middle; *kolon*, the [illegible] 244.
Metacarpal artery, 329, 330.
interossei of dog, 206.
veins, 351.
Metacarpo-phalangeal articulation, 121.
Metacarpus [illegible] wrist), 46.
as compared with human wrist, [illegible]
of pig, 101.

Metacarpus of dog, 104.
nerves, 409.
Metapophysis (*meta*, beyond; *apophysus*), 470.
Metatarsal artery, 325.
nerves, 412.
veins, 346, 347.
Metatarsus (*meta*, behind; *tarsos*, the instep), bones of, 61.
of ox, 98.
of dog, 104.
Milk, 282, 283.
Milk teeth, 218.
Modiolus (the nave of a wheel), 423.
Molar (*mola*, a mill) teeth, 219. *See* TEETH.
Monro, foramen of, 382.
Morgagni liquor, 429.
Morphology of vertebrate skeleton, 469.
Motion of bones in joints, 112.
Motores oculorum, 392.
Mouth, 207.
dissection of, 456.
lips of, 208.
mucous membrane of, 208.
of pig, 255.
Movement of joints, 112.
elbow, 118.
hip, 124.
knee, 124.
shoulder, 118.
stifle, 124.
vertebra, 115.
Mucous membrane of intestine, large, 244.
small, 233.
lachrymal apparatus, 434.
larynx, 293.
mouth, 208.
nose, 284.
œsophagus, 227.
palate, 209.
pharynx, 208.
rectum, 236.
stomach, 230.
tongue, 210, 211.
trachea, 94.
tympanum, 420.
ureters, 262.
urinary bladder, 263.
uterus, 262.
vagina, 275.
vulva, 274.
Müller, H., on muscle in infra-orbital fissure in man, 476.
on influence of sympathetic on muscles, &c., 477.
on existence of unstriped muscles in skin of ear, 479.
Muscle, classifications of, 129.
Muscles, involuntary, 131, 133.
Muscles, varieties of, 128.
voluntary, 132.
origin and insertion of, 129.
Muscles, abdominal inferior, dissection of, 451.
abducens aurem depremens, 172.
abductor, of dog, 206.
of first claw of dog, 206.
adductor brevis, 161.
longus, 162.
magnus, 162.
alveolo-labialis, 177.
anconeus, 193.
of dog, 205.
antea-spinatus, 186.
anterior, crural region of, 162.
extremity, 185.
dissection of, 453.
atloido-mastoideus, 150.
occipitalis brevis, 49.
longus, 148.
styloideus, 145.
suboccipitalis, 144.
attollens anterioris, 171.
maximus, 171.
posticus, 171.
auricular, region of, 171.
axillary, region of, 140.
dissection of, 451.
axoido-atloideus, 150.
basio-glossus, 182.
biceps rotator tibialis, 167.
brachial, anterior region of, 190.
dissection of, 453.
posterior, 191.
dissection of, 454.
buccinator, 177.
dissection of, 450.
caninus, 177.
caput magnum, 191.
medium, 192.
parvum, 192.
of pig, 205.
cervical trapezius, 147.
cervico-acromialis, 147.
auricularis inferioris, 173.
medius, 172.
superioris, 172.
costalis, 154.
subscapularis, 147.
complexus major, 148.
minor, 148.
compressor coccygis, 184.
coraco-humeralis, 189.
radialis, 190.
costal region, 153.
dissection of, 154.
costalis, 159.
costo-abdominalis, 136.

Muscles, costo-cervicalis, 145.
sternalis, 155.
subscapularis, 153.
croup, region of, 165.
dissection of, 455.
crural, anterior region of, 162, 163.
dissection of, 455.
posterior, 167.
dissection of, 456.
crureus, 164.
curvator coccygis, 184.
depressor coccygis, 184.
labii inferioris, 177.
superioris, 177.
diaphragmatic, region of, 170.
dissection of, 452.
diaphragm, 170.
of ox, 204.
digastricus, 180.
dilator naris lateralis, 176.
inferioris, 176.
superioris, 176.
transversalis, 176.
dorsal, region of, 156.
scapular, region of, 151.
dorso-acromialis, 151.
costalis, 153.
humeralis, 152.
mastoideus, 149.
occipitalis, 148.
spinalis, 150.
subscapularis, 152.
of ear, 171.
intrinsic, 421.
erector coccygis, 183.
extensor of outer claw of dog, 206.
extensor metacarpi magnus, 193.
of cat, 205.
of dog, 205.
of pig, 205.
obliquus, 194.
of cat, 205.
of dog, 205.
of ox, 205.
of pig, 205.
of sheep, 205.
pedis, 194, 200.
of dog, 205, 206.
of pig, 205.
[illegible], 205.
lateralis, 200.
pollicis, of dog, 206.
saffraginis, 195.
of dog, 206.
of ox, 205.
eyelids, of, 174.
facial, region of, 175.
Muscles, femoral, internal region of, 160.
flexor brachii, 190.
of dog, 204.
of ox, 205.
of pig, 204.
flexor of claw of dog, 206.
flexor metacarpi externus, 196.
internus, 197.
medius, 196.
obliquus, 196.
metatarsi, 201.
parvus, 201.
pedis accessorius, profundus, 190.
sublimis, 198, 204.
perforans *vel* profundus, 197, 203.
of dog, 206.
of ox, 206.
perforatus *vel* superficialis, 197, 202.
of dog, 206.
of ox, 206.
of pig, 206.
fore-arm of, 193.
anterior region of, 193.
posterior region of, 196.
dissection of, 454.
fore-limb, 185.
fronto-superciliaris, 174.
gastrocnemius externus, 201.
internus, 202.
gemini, 169.
general directions as to dissections of, 446.
genio-hyoideus, 180.
hyo-glossus, 183.
glossal, region of, 182.
gluteal, region of, 165.
dissection of, 455.
gluteus externus, 165.
internus, 166.
maximus, 166.
gracilis, 160.
head, 171.
dissection of, 450.
hind limb, 160.
humeral, region of, 189
humeralis externus, 190.
obliquus, 190.
of dog, 205.
of pig, 205.
humero-radialis, 190.
ulnaris externus, 192.
internus, 192.
parvus, 193.
hyoid, region of, 180.
dissection of, 450.

Muscles, hyoideus, 181.
brevis, 182.
transversus, 181.
hyo-glossus longus, 182.
parvus, 182.
iliacus, 159.
iliaco-trochantericus, 159.
ilio-abdominalis, 138.
aponeuroticus, 162.
femoralis parvus, 165.
spinalis, 156.
trochantericus, 165.
magnus, 166.
parvus, 166.
inferior abdominal, region of, 135.
cervical, region of, 142.
dissection of, 449.
intercervicales, 151.
intercostales, 155.
internal femoral, region of, 160.
intertransversalis colli, 151.
intertransversales lumborum, 157.
ischio-analis, 185.
coccygis, 184.
femoralis, 168.
peronealis, 185.
tibialis externus, 167.
medius, 167.
trochanterici, 169.
kerato-hyoideus magnus, 181.
parvus, 181.
labial, dissection of, 450.
larynx of, 290.
lateralis sterni, 155.
latissimus dorsi, 152.
legs, 45.
dissection of, 456.
levator ani, 185.
humeri, 142.
labii superioris alæquæ nasi, 175.
menti, 177.
palpebræ superioris externus, 174.
internus, 174.
levatores costarum, 154.
longissimus dorsi, 154.
longus colli, 146, 156.
lumbo-abdominalis, 140.
lumbrici, 204.
of dog, 206.
masseter externus, 178.
internus, 179.
dissection of, 450.
mastoideus, 147.
mastoido-auricularis, 173.
humeralis, 142.
Muscles, maxillary, anterior region of, 175.
posterior, 178.
maxillo-labialis, 177.
metacarpal interossei of dog, 206.
musculo-aponeuroticus, 170.
musculus ciliaris, 174.
mylo-hyoideus, 180.
nasalis brevis labii superioris, 176.
longus, 175.
naso-transversalis, 176.
obliquus abdominis externus, 136.
internus, 138.
capitis anticus, 145.
inferioris, 150.
posticus, 150.
superioris, 150.
obturator externus, 168.
internus, 168.
orbicularis oris, 178.
palpebræ, 174.
orbito-palpebralis, 174.
order in which to dissect, 447.
palpebral, region of, 174.
panniculus carnosus, 134.
dissection of, 448.
of dog, 204.
of pig, 204.
parotido-auricularis, 172.
pectoralis anticus, 140.
magnus, 141.
transversus, 141.
peroneus, 200.
of dog, 206.
pharyngo-glossus, 183.
plantaris, 202.
popliteus, 203.
postea-spinatus, 187.
posterior extremity, dissection of, 455.
minor, 187.
pronator teres of dog, 206.
psoas magnus, 185.
parvus, 185.
of dog, 204.
of pig, 204.
pterygoideus externus, 179.
internus, 178.
pyriformis, 169.
radialis accessorius, 199.
rectus abdominis, 139.
capitis anticus major, 144.
minor, 144.
posticus major, 149.
minor, 149.
femoris, 163.
parvus, 165.
retractor ani, 185.
retrahentes aurem, 172.

Muscles, rhomboideus brevis, 152.
longus, 147.
rules to be observed in dissection of, 447.
sacro-coccygeal, region of, 183.
coccygis lateralis, 184.
superioris, 183.
lumbalis *vel* costalis, 159.
trochantericus, 169.
sartorius, 160.
scalenus, 145.
scapular, region of, 186.
dissection of, 453.
scapulo-humeralis parvus, 186.
Grelé, 188.
ulnaris, 191.
magnus, 191.
scuto-auricularis externus, 173.
internus, 173.
semi-membranosus, 162.
spinalis dorsi et lumborum, 157.
tendinosus, 167.
serratus magnus, 153.
sphincter ani, 185.
spinalis colli, 150.
dorsi, 157.
dissection of, 449.
splenius cervico-trachelius, 147.
sternal region of, 155.
sterno-aponeuroticus, 141.
costales externi et interni, 156.
humeralis, 140.
maxillaris, 143.
prescapularis, 142.
pubialis, 139.
thyro-hyoideus, 143.
trochineus, 141.
stylo-glossus, 181.
hyoideus, 181.
maxillaris, 179.
sub-acromio-trochiterius, 187.
dorso-altoideus, 146.
lumbar, region of, 158.
lumbo-pubialis, 158.
tibialis, 160.
trochantericus, 158.
pubio tibialis, 160.
trochantericus externus, 168.
internus, 168.
sublumbar region, dissection of, 449.
subscapulo-humeralis, 188.
hyoideus, 144.
trochantericus, 188.
subscapularis, 188.
superficialis costarum, 153.
superior cervical, region of, 146.
dissection of, 448.
super-naso-labialis, 175.
Muscles, supero-acromio-trochiterius, 186.
maxillo-labialis, 175.
nasalis brevis, 176.
magnus, 176.
supinator longus of dog, 206.
parvus, 206.
tail, muscles of, 183.
temporalis, 178.
tempero-auricularis externus, 171.
internus, 171.
maxillaris, 178.
dissection of, 450.
tensor vaginæ femoris, 162.
teres externus, 186.
internus *vel* major, 188.
tibial, anterior region of, 200.
posterior, 201.
tongue, muscles of, 182.
trachelo-mastoideus, 149.
suboccipitalis, 144.
transversalis abdominis, 140.
transversales costarum, 154.
trapezius, dorsal, 151.
triceps abductor femoris, 167.
adductores femoris, 161.
extensor brachii, 191.
ulnaris accessorius, 198.
vastus externus, 164.
internus, 164.
zygomatico-auricularis, 171.
labialis, 174.
maxillaris, 178.
zygomaticus, 175.
Muscular contractility or irritability, 129.
stimuli of, 129.
rigidity, 446.
Muscular Tissue, general anatomy of, 129.
blood-vessels of, 134.
cleavage into discs, 133.
connection with tendons, 132.
corpuscles of, 133.
cross stripes of, 132.
fasciculi, 132.
fibres of striped, 132.
length and ending, 133.
unstriped, 133.
fibres of, 132.
involuntary, 131, 133.
lymphatics of, 134.
myolemma of, 132.
nerves of, 134.
terminations of, in, 134.
physical properties of, 129.
plain or unstriped, 133.
sarcolemma of, 132.
sarcous elements of, 133.
sheath of, 132.
vital properties of, 129.

Muscular Tissue, voluntary or striped, 132.
Muscular tissue of arteries, 313.
darlos, 266.
Fallopian tubes, 277.
heart, 309.
intestine, large, 234, 236.
small, 230.
iris, 427.
nomenclature, 129.
œsophagus, 227.
pharynx, 226.
rectum, 236.
stomach, 230.
tongue, 212.
urinary bladder, 262.
uterus, 275.
vagina, 275.
Musculi papillares of heart, 305.
pectinati of heart, 305.
Musculo-aponeuroticus, 170.
Musculo-occipital artery, 333, 334.
Musculus ciliaris, 174
Mesenteric plexus, 417, 418.
Mylo-hyoid (*mule*, a mill, the jaw; hyoid bone) nerve, 396.
Mylo-hyoideus muscle, 180.
Myolemma (*mus*, a muscle; *lemma*, a husk or rind), 132.
Myology, 128.

Nares (nostrils), anterior, 73.
mucous membrane, 226.
posterior, 226.
of ox, 89.
Nasal lateral branch of ophthalmic artery, 339.
Nasal (*nasas*, the nose) bone, 72.
of ox, 89.
of pig, 91.
of dog, 93.
cartilages, 226.
chambers, 285.
fossæ or cavities, 86.
dissection of, 460.
mucous membrane of, 286.
nerve, 393, 394.
openings, 286.
of pig, 91.
Schneiderian membrane of, 286.
suture, 82.
walls of, 285.
Nasalis brevis, &c. *See* Muscles.
Naso-transversalis, 176.
Nates (buttocks) in cerebrum, 385.
in ox, 385.
Navicular (*navicula*, a small ship or boat), bone of fore foot, 50.
Navicular ligament, 123.
Neck, dissection of, 448, 449.
Nerves, motor, 368.
sensory, 368.
terminations of, 367.
Nerves, descriptive anatomy of, 390.
abducens, 396.
auditory, 398.
auricular, anterior, 397.
middle, 397.
posterior, 397.
auriculo-temporal, 395.
brachial, 407.
buccal, 395.
cardiac, 416.
cervical, 402.
chorda tympanic, 397.
coccygeal, 406.
cochlear, 398.
crural, 410.
cubital cutaneous, 408.
dental, 394.
diaphragmatic, 407.
dorsal, 404.
eighth cervical, 403.
dorsal, 404.
facial, 396.
femoral, anterior, 410.
popliteal, 411, 412.
subpubic, 411.
fifth cervical, 403.
dorsal, 404.
first cervical, 403.
lumbar, 405.
fourth cervical, 403.
dorsal, 404.
lumbar, 405.
frontal, 393.
glosso-pharyngeal, 398.
gluteal, 411.
gustatory, 395.
humeral posterior, 408.
hypo-glossal, 401.
iliaco-muscular, 410.
ilio-muscular, 411.
intercostal, 404.
Jacobson's, 398.
lachrymal, 393.
laryngeals of pneumogastric, 399.
lingual, 395.
lumbar, 405.
lumbo-sacral, 410.
masseter, 395.
maxillary, inferior, 394.
superior, 394.
mental, 396.
metacarpal, 409.
metatarsal, 412.

Nerves, motores oculorum, 392.
mylo-hyoidean, 396.
nasal, 393.
of superior maxillary, 394.
ninth, 398.
obturator, 411.
olfactory, 391.
ophthalmic, 393.
optic, 391.
palato-maxillary, 394.
palpebro-nasal, 393.
petrosal, lesser superior, 397.
plantar, 412.
pneumogastric, 398.
popliteal, 412.
portio-dura, 396, 398.
pterygoid, internal, 395.
radial, 409.
sacral nerves, 406.
sacro-sciatic, 411.
scapular anterior, 407.
sciatics, 411, 412.
second cervical, 403.
dorsal, 404.
lumbar, 405.
seventh cervical, 403.
dorsal, 404.
sixth cervical, 403.
dorsal, 404.
lumbar, 405.
spinal, 401.
spinal accessory, 400.
spiral, 408.
splanchnic, great, 417.
lesser, 418.
staphyline, 394.
subscapular, 408.
subzygomatic, 395.
supra-orbital, 392.
sympathetic, 413.
temporal, deep, 395.
temporo-facial, 397.
third cervical, 403.
dorsal, 404.
lumbar, 405.
thoracic, 407.
tibial, 412.
trifacial, 392.
ulnar, 408.
vestibular, 398.
Nerves, Sympathetic, descriptive anatomy of, 413.
ganglia of. *See* Ganglion.
gangliated cords of, 413.
cervical parts, 414.
lumbar part, 418.
sacral part, 419.
thoracic part, 416.
Nerves, Sympathetic, plexuses of. *See* Plexuses.
choroid coat of eye, 426.
in cochlea, 423.
heart, 311, 416.
intestine, small, 233, 417.
large, 234, 417.
kidney, 261.
larynx, 294.
lungs, 298.
muscle, 134.
nose, 285.
semicircular canals, 398.
spleen, 243.
stomach, 231.
tongue, 212.
trachea, 294.
urinary bladder, 263.
uterus, 277.
Nerve-cells or vesicles, 366.
varieties of, 366.
Nerve-corpuscles, 366.
Nerve-fibres, afferent, 368.
axis of, 366.
of cerebro-spinal nerves, 367.
gelatinous or grey, 366.
distribution on different nerves, 369.
medullated, 366.
neurilemma of, 367.
terminations of, 367.
white appearance of, 366.
axis cylinder, 366.
connection with grey matter, 366.
ganglion-cells, 367.
white efferent, 368.
in ganglia, 367.
looped, 367.
medullary sheath of, 366.
membranous tube, 366.
in plexuses, 367.
primitive band of, 366.
sheath of, 366.
of roots of spinal nerves, 367.
termination of. *See* Nerves (Cells of Spinal termination of).
white substance of, 366.
Nervous Substance—
cells, corpuscles, or vesicles of. *See* Nervous Cells.
of cerebro-spinal nerves. *See* Nerves.
of cerebrum grey, 377.
white, 378.
fibres of. *See* Nerve-Fibres.

Nervous Substance—*continued.*
ganglia. *See* Ganglia.
of medulla oblongata, grey, 372.
white, 372.
of retina, 428.
of spinal cord grey, 375.
white, 375.
structural elements of, 366.
of sympathetic, 413.
Nervous System, general anatomy of, 365.
cerebro-spinal centre, 365.
dissection of, 465.
functions of, 365.
sympathetic portion of, 413.
Nervous system, descriptive anatomy of, 365.
cerebro-spinal, 390, 401.
cranial nerves, 390.
spinal nerves, 401.
sympathetic nerves, 413.
Nervus abducens, 396.
motorius oculi, 392.
patheticus, 392.
trigeminus, 392.
vagus (wandering nerve), 398.
Neural (*neuron*, a nerve) arch, 470.
spines of vertebræ, 470.
Neurapophysis (*neuron*, a nerve; *apophysis*), 470.
Neurilemma (*neuron*, a nerve; *lemma*, a peel or skin), 366.
Nipple, 281.
in cow, 282.
Nose, 284.
alæ of, 284.
ass or mule, in, 284.
cartilages of, 284.
cavities of, 285, 286, 287.
commissures of, 284.
constituent parts of, 284.
diverticulum of, 284.
dog, of, 285.
mucous membrane, 286.
muscles of, 175.
nerves of, 285.
nostrils, 285.
in ox, 285.
snout of pig, 285.
septum of, 284.
skin of, 285.
vessels of, 285.
Notch, carotid, 71.
condyloid, 63.
ethmoidal of frontal, 65.
stylo-condyloid, 63.
Notches of vertebræ, 16.

Obliquus muscles. *See* Muscles.
Oblique muscles of eye, 430.
Obturator (*obturo*, I stop up) artery, 321.
foramen, 31.
ligament or membrane, 117.
muscles, 168.
nerve, 412.
Occipital (*occiput*, the back of the head) artery, 323.
bone, 62.
of ox, 88.
of pig, 90.
of dog, 92.
foramen, 62.
nerves. *See* Nerves.
sinus, 389.
vein, 363.
Occipito-atloidean ligament, 114.
axoidean ligament, 114.
Odontoid (*odous*, a tooth; *eidos*, shape) ligaments, 114.
process of the axis, 21.
Œsophagus (*oio* or *oiso*, obs. *phero*, I bear; *phangein*, to eat), 227.
coats of, 227.
in ox, 227.
dissection of, 458.
foramen for, in diaphragm, 170.
Olecranon (*olene*, the elbow; *kranos*, a helmet) fossa, 39.
Olfactory bulb, 379.
nerve. *See* Nerves.
Olivary (*oliva*, an olive) bodies, 374.
corpus dentatum of, 374.
Omasum of stomach of ox, 252
Omentum (the canal) gastro-colic, 230.
gastro-hepatic, 230.
gastro-splenic, 230.
Opercular (coverings or lids) of dental follicles, 220.
Ophthalmic (*ophthalmos*, an eye) artery. *See* Artery.
ganglion, 413.
nerve, 393
lobes, 385
Optic nerve, 391.
roots of, 39°.
thalamus, 383.
tract, 378.
Orbicularis muscles, 174, 178.
Orbits (*orbita*, circle), 83.
muscles of, 174.
Organs of circulation, 300.
of digestion, 207.
generation, female, 273.
male, 265.
mastication and deglutition, 214.
respiration, 283.
of senses, 419, 424.

Organs, urinary, 259.
Os calcis, 58.
of ox, 97.
corona, 50.
cuboides, 59.
cuneiforme magnum, 60.
medium, 60.
parvum, 60.
femoris, 53.
hyoides, 81.
of ox, 90.
of pig, 92.
lingual, 81.
lunare, 43.
magnum, 45.
metacarpi magnum, 47.
parvi, 48.
metatarsi magnum, 61.
naviculare, 52.
orbiculare of tympanum, 420.
pedis, 50.
pubis, 30.
suffraginis, 49.
tali, 58.
unguis, 76.
uteri externum, 275.
internum, 276.
Ossa innominata, 27.
metatarsi parvi, 61.
triquetra, triangular bones, 65.
Wormiana, 65.
Ossicula auditûs, 420.
Ossified cartilage, 11.
Osteology (*osteon*, a bone; *logos*, discourse), 2.
comparative, 87.
Ostium abdominale of Fallopian tube, 277.
uterinum of Fallopian tube, 277.
uteri, 276.
Otic (*ous*, gen. *otos*, an ear; *konis*, dust) ganglion, 414.
Oto-coniæ (*ous*, gen. *otos*, an ear; *konis*, dust), 424.
Outlet of pelvis, 31.
Ovaries (*ovum*, an egg), 277.
function of, 278.
Graafian vesicles of, 278.
ligaments of, 278.
situation, 277.
stroma of, 278.
structure, 278.
tunica albuginea of, 278.
vessels of, 278.
Oviparous reproduction, 265.
Ovo-viviparous reproduction, 265.
Ovum, 278.
structure of, 278.
Owen's nomenclature of vertebral elements, 470.
Owen's views as to nature of limbs, 471.

Pacchinian bodies, end of nerve fibres in, 368.
Palate, 208.
bone, 77.
dissection of, 456.
of ox, 246.
soft, 209.
of ox, 246.
Palatine arteries. *See* Artery.
bone, 77.
of ox, 89.
of pig, 91.
of dog, 93.
foramina, 77.
nerves. *See* Nerves.
Palato-labial artery, 340.
Palato-maxillary nerve, 394.
Palpebral (*palpebra*, an eyelid) muscles, 174.
nerve, nasal, 393.
Pancreas (*pan*, all; *kreas*, flesh), 241.
duct of, 242.
in dog, 258.
in ox, 242.
in pig, 258.
function of, 242.
head and tail of, 242.
of ox, 255.
position, 241.
secretion of, 242.
structure of, 241.
vessels of, 242.
Pancreatic duct, 242.
juice, 242.
Panniculus adiposus, 435.
carnosus, 134.
of dog, 204.
of pig, 204.
Papilla lachrymalis, 433.
Papillæ of cheek, 209.
dental, 220.
of hair follicles, 436.
of skin, 435.
of tongue, 211.
circumvallate or large, 211.
of ox, 246.
conical, 211.
of ox, 246.
filiform, 211.
of ox, 246.
fungiform or middle-sized, 211.
structure of, 211.
Papillary stage of dentition, 220.
Par trigeminum, 392.
vagum, 398.
Parapophysis (*para*, beside; *apophysis*), 470.
Parietal bone, 64.
of ox, 88.

Parietal bone of pig, 90.
of dog, 92.
Parotid Gland (*para*, near; *ous*, gen. *outos*, the ear), 213.
accessory, 213.
dissection of, 457.
duct of, 213.
ox, of, 246.
structure of, 213.
Parotido-auricularis, 172.
Pastern bone, 49.
small, 50.
joint, ligaments of, 122.
Patella (a dish or plate), 55.
of ox, 97.
ligaments of, 124.
character of, 55.
Pectoral muscles. *See* Muscles.
Pedal plexuses, 354.
Peduncles of cerebellum, 375.
of cerebrum, 378.
Pelvis (a basin), 27.
articulations of, 115.
brim of, 31.
dissections of, 460.
of dog, 104.
of kidney, 260.
Penis, 271.
bull, in, 278.
corona glandis of, 271.
corpora cavernosa of, 271.
corpus spongiosum, 272.
dog, in, 280.
function of, 271.
glands of, 271.
glans of, 272.
integument of, 271.
ligament, suspensory, of, 271.
meatus urinarius of, 272.
muscles of, 272, 273.
nerves of, 272.
pig, in, 279.
raphe of, 271.
septum pectiniforme, 272.
sheath of, 271.
trabeculæ of, 272.
vessels of, 272.
Penniform (*penna*, a feather; *forma*, shape) muscles, 128.
Peptic (*pepto*, I digest) glands, 231.
Percival's classification of muscles, 129.
Perforans muscles. *See* Fore and Hind Limb. *See* Muscles.
Perforated space, anterior, 379.
posterior, 379.
Perforatus muscles. *See* Fore and Hind Limb.
Pericardium (*peri*, about; *kardia*, the heart), 301.
Pericardium, function of, 302.
dissection of, 461.
liquor of, 302.
structure of, 301.
Perichondrium (*peri*, about; *chondros*, cartilage), 13.
Perilymph (*peri*, about; *lympha*, water), 423.
Perineal arteries (*peri*, about; *naio*, I am situated), 321.
Periodontal (*peri*, about; *odous*, a tooth), 221.
Periosteum (*peri*, about; *osteon*, a bone), 6
Peristaltic (*peristalto*, I constrict or narrow) movement of deglutition, 228.
Peritoneum (*peri*, about; *teino*, I stretch), 244.
continuity of traced, 244.
folds of, 244.
ligaments formed by, 244.
mesenteries of, 244.
omenta of, 244.
structure of, 244.
Peroneal (*perone*, the pin of a buckle, the fibula) arteries, 325.
Peroneus muscle, 200.
of dog, 206.
Perpendicular artery, 331.
Pes anserinus (goose's foot), 367.
hippocampi, 382.
Petit, canal of, 428.
Petrosal nerves, 397.
Peyer's glands, 233.
Phalanges (*phalangx*, a band of soldiers) of dog, 104.
Pharyngeal artery, 335.
plexus, 415.
Pharyngo-glossus, 183.
Pharynx (*pharungx*), 226.
dissection of, 458.
mucous membrane of, 227.
muscles of. *See* Muscles.
ox, in, 249.
Phrenic (*phren*, the diaphragm) arteries, 317.
Pia mater of brain, 371.
of spinal cord, 369.
Pig, for various points in anatomy of, see under different organs
rachitis in bones of, 3.
Pigment of choroid, 427.
iris, 427.
Pillars of fauces, 209.
Pineal gland, 384.
acervulus cerebri in, 385.
Pisiform (*pisum*, a pea; *forma*, shape) bone, 46.
Pith of hair. *See* Hairs.
Pituitary (*pituita*, phlegm or mucous) body, 378.
membrane of nose, 286.

Placental reproduction, 265.
Planes, anatomical, of description, 14.
of cranial cavity, 85.
Plantar (*planta*, the sole of the foot) arteries. *See* ARTERIES.
ligaments, 128.
nerves. *See* NERVES.
veins, 346, 347.
Plantaris muscle, 202.
Plate, central, of ethmoid, 71.
cribriform, 71.
Pleura (*pleura*, a rib or side) costalis, 296.
diaphragmaticus, 296.
pulmonalis, 296.
Pleuræ, 296.
functions of, 296.
mediastinum or partition of, 296.
structure of, 296.
Pleurapophysis (*pleura*, a side; *apophysis*), 470.
PLEXUSES of nerves, 367.
auricular, 402.
brachial, 407.
carotid, 415.
cavernous, 415.
cervical, deep, 402.
superior, 414.
gastric, 417.
hepatic, 417.
hypogastric, 406.
lumbo-aortic, 417.
lumbo-sacral, 410.
dissection of, 468.
mesentericus (musculo-intestinal plexus), 417, 418.
pelvic, 406, 419.
pharyngeal, 415.
renal, 417.
sacral, 419.
solar, 417.
spermatic, 418.
splenic, 417.
tracheal, 416.
PLEXUSES of veins, choroid, 383.
of lateral ventricle, 383.
Pneumogastric (*pneumon*, the lung; *gaster*, the stomach) nerve. *See* NERVES.
Point of the hip, 28.
Pons Tarini (bridge of Tarin), 379.
Pons Varolii (bridge of Varolius), 375.
Popliteal artery. *See* ARTERY.
nerve, 412.
dissection of, 463.
vein, 346, 349.
Popliteus muscle, 203.
Portal canals, 239.
Portal vein, 240, 344.
Portio dura, 396.
mollis of seventh cranial nerve, 396.
Porus opticus (optic pore), 425.
Postea-spinati, 187.
Pouches, guttural, 424.
Poupart's ligament, 138.
Prehension, 207.
Prehumeral artery, 328.
Preparation of arteries, 461.
Prevertebral artery, 333.
Primitive band or axis of nerve fibre, 366.
groove, dental, 220.
sheath of nerve fibre, 366.
Process of bone, 10.
auditory, external, 69.
coracoid of occipital, 63.
of scapula, 37.
coronoid of lower jaw, 80.
hyoid, 69.
mastoid, 67, 68.
odontoid, 20.
olecranon of ulna, 42.
olivary, 70.
orbital of frontal, 65.
palatine, 73.
pterygoid, 71.
spur of hyoid, 82.
styloid of occipital, 63.
zygomatic, 67.
of intermaxillary, 76.
Process, ciliary, 428.
of incus, 420.
of malleus, 420.
of vertebræ articulating, 16.
ligaments of, 113.
spinous, 16.
transverse, 16.
Processus e cerebello ad testes, 385.
brevis, 420.
cochleariformis (spoon-shaped process), 421.
gracilis, 420.
Promontory of tympanum, 421.
Pronator teres of dog, 206.
Prostate (*pro*, before; *isterni*, I place) gland, 269.
dog and cat, in, 279.
fluid of, 269.
structure of, 269.
Prostatic fluid, 269.
Protuberance, parietal, 64.
Psoas (*psoa*, the loin) muscles, 158.
of dog, 204.
of pig, 204.
Pterygoid (*pterux*, a wing; *eidos*, shape) arteries, 337, 339.

Pterygoid bones, of ox, 89.
of dog, 94.
foramen or canal, 69.
muscles, 178, 179.
nerve, 395.
Pubic arch, 31.
bone, 31.
Pubio-femoral ligament, 124.
in ox, 124.
Pulmonary artery. *See* Artery.
dissection of, 463.
vein, 343.
Punctum lachrymale, 434.
Pupil of eye, 427.
form and size, 427.
membrane of, 428.
Pyloric artery, 318.
orifice of stomach, 229.
Pylorus (*puloros*, a gate-keeper), 229.
Pyramid in tympanum, 421.
Pyramids of medulla oblongata, inferior, 374.
superior, 375.
of kidney, 261.
Pyriformis (*pyrus*, a pear; *formis*, shape) muscle, 169.

Racemose (*racemus*, a bunch of grapes).
Rachitis, bone in, 3.
Radial artery, 329.
nerve, 409.
vein, 351.
Radialis accessorius, 199.
Radio-carpal articulation, 120.
ulnar articulation, 118.
Radius (a ray, or the spoke of a wheel), 40.
of ox, 98.
of pig, 100.
of dog, 103.
Ragged hips, 39.
Ram, vasa deferentia of, 278.
Ramus (a branch) of ischium, 329.
of pubis, 30.
anastomoticus of carotid, 332.
Raphe (*rhaphe*, a seam; from *rhapto*, I sew) of corpus callosum, 380.
of medulla oblongata, 374.
scrotum, 266.
tongue, 210.
Recti muscles of eye, 430.
Recto-uterine folds, 276.
Rectum (*intestinum rectum*, the straight intestine), 236.
position and course of, 236.
structure of, 236.
vessels and nerves of, 236.
Rectus muscle. *See* Muscles.
Recurrent arteries. *See* Artery.
nerve. *See* Nerves.
Reichert's method of examining non-striped muscle, 475.
Reil, island of, 378.
Renal (*ren*, the kidney) artery, 319.
vein, 345.
Reproduction, physiology of, 265.
Respiration, organs of, 283.
dissection of, 460.
in birds, 299.
physiology of, 283.
varieties of, 283.
Restiform (*restis*, a cord; *forma*, shape) bodies, 375.
Rete mucosum, 435.
Reticulum in stomach of ox, 251.
Retina (*rete*, a net), 428.
ciliary part, 428.
Jacob's membrane of, 428.
limiting membrane of, 428.
nervous layer of, 428.
physical characters of, 428.
structure of, 428.
vessels of, 428.
Retractor ani, 185.
Retrahentes aurem muscle, 172.
Rhomboideus (*rhombos*, a rhomb or equilateral four-sided figure with oblique angles; *eidos*, shape) muscles, 147, 152.
Ribs, 33.
of ox, 96.
of pig, 100.
of dog, 103.
peculiar, 35.
Rima (cleft) glottidis, 293.
Ring, abdominal, external, 138.
internal, 138.
Rostrum (a beak) of corpus callosum, 380.
Rotation, 112.
Rudolphi on muscular fibres in orbit of bears, 476.
Rumen in stomach of ox, 249.
Ruminants, generative organs of, 278.
special variations in digestive apparatus of, 245.
Rumination, function of, 255.
Ruysch's tunic or membrane, 426.

Saccular stage of development of teeth, 221.
Saccule of vestibule, 424.
Sacral (sacrum) arteries, 317, 321.
nerves, 406.
Sacro-iliac articulation, 116.
in cow, 117.
muscles. *See* Muscles.
lumbal articulation, 115.
sciatic ligaments, 117.
nerves, 411.

Sacrum (os sacrum, a sacred bone, because formerly offered in sacrifices), 25.
articulations of, 27.
of ox, 95.
of pig, 100.
Sacs of milk teeth, 220.
of permanent teeth, 221.
Saggittal (*sagitta*, an arrow) suture, 82.
Saliva, 214.
Salivary glands, 212.
Santorini, muscle of, 135.
Saphenic artery, 323.
veins, 348, 349.
Sartorius (*sarter*, a tailor) muscle, 160.
Scale vestibuli (*scala*, a stair), 422.
Scalenus (*skalenos*, with unequal sides) muscles, 145.
Scaphoid (*skappe*, a skiff or boat; *eidos*, shape) bone of foot, 43.
Scapula (probably *skapane*, a spade), 36.
of ox, 98.
of pig, 100.
of dog, 103.
Scapular artery, 327, 328.
muscles, region of, 186.
nerve, 407.
Scapulo-humeral articulation, 118.
muscles. *See* Muscles.
Scarpas liquor, 424.
Schindylesis (*schinduleo*, I split), 111.
Schneiderian membrane, 286.
Sciatic (*ischion*, the hip) nerves, 411, 412.
Sclerome (*skleros*, dry, hard, with termination of completeness), 471.
Sclerotic (*skleros*, hard) coat, 425.
structure of, 425.
Sclerotome (*skleros*, hard; *temno*, I cut), 471.
Scrotum (a hide), 266.
dartos tunic, 266.
Scuto-auriculares muscles, 173.
Sea-cow, cervical vertebræ of, 17.
Sebaceous (*sevum*, suet) glands, 436.
Segment of trunk, 469,
relation of limbs to, 470, 471.
Sella turcica (Turkish saddle), 70.
Semicircular canals, 422.
Semimembranous muscle, 162.
Seminal ducts, 268.
vesicles, 268.
Seminiferous tubes, 267.
Semipenniform muscles, 129.
Semispinalis dorsi et lumborum muscle, 157.
Semitendinosus muscle, 167.
Senses, organs of, 424, 429.
Septum (a partition, from *sepio*, I hedge in) of heart, auricular, 303.
ventricular, 302.
lucidum, 381.
Septum, pectiniform (comb-like partition), 272.
scroti, 266.
Sereal homology, 469.
Serrated (*serra*, a saw) suture, 82.
Serratus muscle. *See* Muscles.
Serum of blood, 301.
Sesamoid (*sesamon*, a kind of small grain; *eidos*, shape) bones of fore foot, 50
ligaments, 122.
Seventh cervical vertebra, 21.
of ox, 95.
of pig, 99.
Sexual organs, 264.
Shape's classification of muscles, 129.
Sheath of nerve fibre, medullary, 366.
of nerves, common, 367.
Sheaths, synovial, 109.
Shoulder joint, bones of, 36.
ligaments of, 118
Shuttle bone, 50.
Sigmoid valves, 306.
aortic, 308.
pulmonary, 306.
Sinus (a hollow)—
cavernous, 389.
ethmoidal, 287.
frontal, 86, 287.
lateral, 389.
longitudinal, 389.
maxillary, 74, 86.
inferior, 287.
superior, 287.
occipital, 389.
petrosal, 389.
pocularis (cup-like sinus), 269.
sphenoidal, 287.
transverse, 389.
Sinuses, cranial,
sphenoidal, 71, 87.
of Valsalva, 306.
aortic, 308.
pulmonary, 306.
venous, of cranium, 389.
Sixth cervical vertebra, 21.
of ox, 95.
Skeleton (*skello*, I dry). *See* Bones.
Skin, general anatomy of, 434.
chemical composition of, 434.
corium, deep and papillary, 435.
cuticle. *See* Cuticle.
dermis of, 435.
epidermis, 434.
furrows of, 434, 435.
glands of, sebaceous, 436.
sudoriferous, 436.
nerves of, 435.

Skin, papillæ of, 435.
pigment of, 435.
rete mucosum of, 435.
structure of, 435.
true, 435.
vessels of, 435.
Skull, anterior region of, 82.
as a whole, 82.
bones of, 62.
number of bones in, 62.
Sloth, cervical vertebræ of, 17.
Socket of the tusk, 75.
Sœmmering's classification of cranial nerves, 390.
Solar (*sol*, the sun) plexus, 346.
Sole of hoof, 443.
Somatome (*soma*, a body; *temno*, I cut), 471.
Space, perforated, anterior, 379.
posterior, 379.
Spaces, Haversian, of bone, 5.
Spermatic cord, coverings of, 266.
structure of, 266.
artery, 319.
vein, 345.
Sphenoid (*sphen*, a wedge; *eidos*, shape) bone, 69.
of ox, 88.
of pig, 90.
of dog, 93.
Sphenoidal sinus, 87.
Spheno-palatine artery, 340.
ganglion, 413.
Sphincter (*sphingo*, I bind) of rectum, 185.
of pupils, 428.
Spinal accessory nerves, 400.
Spinal Cord, descriptive anatomy of, 372.
central canal of, 372.
columns of, 372.
commissures of, 372.
cylinders of, 373.
dissection of, 465.
fibres of, 373.
fissures of, 372.
grey matter of, 373.
length and form of, 372.
membranes of, 368.
minute structure of, 373.
origin of nerves from, 372.
sections of, 373.
weight of, compared with brain, 373.
in ass, dog, hare, pig, and man, 373.
Spinal arteries. *See* Arteries.
Spinal nerves. *See* Nerves.
divisions of anterior, 401.
posterior, 401.
Spinalis. *See* Muscles.
Spine. *See* Vertebral column.
Spine, hæmal, 470.
maxillary, 73.
neural, 470.
zygomatic, 67.
Spiral nerve, 408.
Splanchnic nerves, 417, 418.
Spleen (*splen*), 242.
coats of, 243.
corpuscles of, 243.
function of, 244.
hilus or fissure of, 243.
of ox, 255.
nerves of, 243.
position of, 242.
pulp of, 243.
shape, 242.
structure of, 243.
trabeculæ of, 243.
vessels of, 243.
vesicles of, 243.
Splenic arteries, 318
flexure of colon, 235.
vein, 345.
Splenius (*splenium*, a pad) cervico-trachelius, 147.
Splints, 6.
Splint bone, 47, 48.
Sporular generation, 264.
Squamous (*squama*, scale) suture, 82.
Stannius on orbit of domestic animals, 476.
Stapedius (*stapes*) muscle, 421.
Stapes (a stirrup), 420.
Staphyline artery, 340.
nerve, 394.
Steno's duct, 213.
Sternal articulation, 116.
region, muscles of, 155.
Sterno-muscles. *See* Muscles.
Sternum, 32.
artery of, 325.
of dog, 103.
of ox, 96.
of pig, 100.
Stifle joint, 124.
ligaments of, 124.
movement of, 124.
Stomach, 229.
alveoli, 331.
coats of, 230.
connections of, 230.
dissection of, 458.
dog, in, 258.
epithelium of, 231.
follicles of, 231.
glands of, 231.

Stomach, mucous membrane of, 231.
muscular coat of, 230.
ox, in, 249.
nerves of, 231.
pig, in, 258.
position of, 229.
pylorus, 229.
shape of, 229.
structure of, 230.
tubules of, 131.
vessels of, 231.
Strangeways on a supernumerary oblique muscle of eye, 472.
Stria longitudinales, 380.
Stripes, cross of muscle, 132.
cause of, 133.
Stroma of ovaries, 278.
Stubb's classification of muscles, 129.
Stylo-muscles. *See* Muscles.
Styloid (*stulos*, a stile or pen; *eidos*, shape) process of occipital, 63.
Styloid, lateral ligament, 114.
Stylo-mastoid foramen, 69.
Subacromio-trochiterius, 187.
Subarachnoid fluid, 366.
space, 369.
Subclavian artery. *See* Artery.
Subcutaneous abdominal artery, 322.
Subdorso-atloideus, 146.
Sublingual artery, 336.
gland of ox, 246.
of dog, 256.
Sublobular veins of liver, 239.
Sublumbar region, muscles of, 158.
Sublumbo-pubialis, 158.
tibialis, 160.
trochantericus, 158.
Submaxillary ganglion, 414.
artery, 335.
gland of dog, 256.
dissection of, 457.
Submental artery, 336.
Subpubio-tibialis, 160.
trochanterici, 168.
Subscapularis, 158.
Subscapular nerve, 408.
Subscapulo-muscles. *See* Muscles.
Subzygomatic artery, 337.
nerve, 395.
vein, 354.
Sudoriferous glands, 436.
Suffraginis, 49.
Sulci (furrows) in brain, 377.
Superficialis costarum, 153.
Superior cervical region muscles, 146.
Super-naso labialis, 175.
Supero-acromio-trochiterius, 186.
maxillo-labialis, 175.
Supero-maxillo-nasalis, 176.
Supinator muscles of dog, 206.
Supra-orbital artery, 340.
nerve, 393.
Supra-renal bodies, 263.
cortical part of, 263.
function of, 263.
medullary part of, 263.
Supra-spinous ligaments, 113.
Sutura squamosa, 111.
Suture (*sutura*, a seam), forms of, 82.
coronal, 83.
dentata, 110.
frontal, 65, 82.
fronto-nasal, 83.
harmonia, 111.
inter-parietal, 82.
lambdoidal, 83.
lambosa, 111.
longitudinal, 82.
nasal, 82.
serrata, 110.
squamosa, 83, 111.
Sweat glands, 436.
Sylvius, aqueduct of, 376.
Sympathetic nerve. *See* Nerve, Sympathetic.
dissection of, 469.
Synarthrosis (*sun*, with, together; *arthron*, cartilage), 110.
Syndesmology (*sundesmos*, a ligament; *logos*, a discourse), 105.
Synovia (*sun*, with *ōon*, an egg), 110.
Synovial, bursal, 109.
capsules, 109.
fluid, 110.
folds or fringes, 109.
membranes, 109.
Synovitis, 110.
Syncranium, 72, 73.
Syssclerotome (*sun*, along with; *skleros*, dry; *temno*, I cut), 471.
Syssomatome (*sun*; *soma*, body; *temno*), 471.
Systemic veins, 243.

Tabular bones, 8.
Tænia (*taina*, a band or ribbon) semicircularis, 382.
hippocampi, 382.
Tail, muscles of, 183.
Tapetum (a carpet), 427.
Tarsal (*tarsus*, the cartilage supporting the eye cartilages) ligaments, 128.
Tarso-metatarsal ligaments, 128.
Tarsus (the upper surface of the foot), 57.
of ox, 97.
of dog, 104.
ligaments of, 126.

Teeth, 214.
as age indicators, 223.
alveolus of, 215.
arrangement in jaws, 217.
canine, 216.
cavities of reserve of, 221.
cervix of, 215.
characters of general, 215.
chemical composition of, 215.
classification of, 217.
in colt, 224.
in crib-biters, 226.
crown of, 215.
crusta petrosa of, 217.
dentine of, 216.
development of, 220.
difference between bone and, 215.
enamel of, 216.
in dog, 257.
formation of, 220.
formula for teeth in horse, 217.
in ox, 246.
in pig, 256.
in sheep, 248.
in foal, 223.
follicular stage of, 220.
Girard's method of estimating age by, 225.
incisor, 217.
as indicators of age in horse, 223.
in dog, 258.
in ox, 247.
in sheep, 249.
in pig, 257.
infundibulum, 218.
interdental spaces, 217.
laniaries, 219.
milk, 218.
molar, 219.
ox, in, 246.
periodontal membrane of, 216.
permanent, 217.
calcification of, 222.
cavities of reserve of, 222.
development of, 222.
eruption of, 223.
formula of, 217.
primitive groove of, 220.
pulp, dental, 216.
nerve of, 216.
primitive, 222.
relation of, to food, 215.
sacs of, 222.
in shell mouth, 218.
table of, 215.
temporary, 217.
development of, 220.
Teeth, temporary, eruption of, 223.
follicular stage of, 220.
formula of, 217.
papillary stage of, 220.
saccular stage of, 221.
shedding of, 224.
tubules of, 216.
varieties of, 215.
wolf, 220.
Temporal (*tempora*, the temples), arteries, 335, 337, 339.
bone, 66.
of ox, 88.
of pig, 90.
of dog, 92.
fossa, 84.
muscle, 178.
nerve. *See* Nerve.
petrous, 67.
squamous, 66.
vein, superficial, 254.
Temporo-auricularis externus et internus, 178.
maxillary articulation, 114.
maxillaris, 198.
Tendons (*tendo*, I stretch), 128.
connection with muscles, 128.
Tensor (*tendo*, I stretch). *See* Muscles.
Tensor tympani, 421.
Tentorium (a tent, from *tendo*, I stretch)
cerebelli, 370.
ossific, 64.
Teres. *See* Muscles.
Testes (testicles), 265.
capsule of, 266.
coni vasculosi, 267.
coverings of, 266.
descent of, 266.
dog and cat, in, 279.
epididymis, 268.
excretory duct of, 268.
glandular substance of, 267.
globus major et minor, 267.
gubernaculum of, 266.
lobes of, 267.
mediastinum of, 269.
ox, in, 278.
pig, in, 279.
position of, in fœtus, 266.
ruminants, in, 278.
secretion of, 265.
septum of, 267.
sheep, in, 278.
structure of, 267.
tubuli of, 267.
recti of, 267.
trabeculæ septulæ of, 267.
tunica albuginea of, 267.

Testes, tunica vaginalis propria of, 266.
reflex of, 266.
vasculosa of, 269.
vas deferens of, 268.
vasa efferentia of, 267.
recta of, 267.
vasculum aberrans of, 268.
Testes of corpora quadrigemina, 585.
Thalami optici (optic couches), 383.
Thebesius, foramina of, 304.
valve of, 304.
Thigh, bone of, 56.
Thoracic (thorax) arteries. *See* Artery.
articulation, 115.
duct, 358.
dissection of, 464.
nerves, 407.
vein, 350, 352.
Thorax (*thorax*, a breast-plate), 32.
bones of, 32.
cavity of, 296.
dissection of organs in, 461.
pleura of, 296.
shape of, 36.
Thymus gland, 294.
central stem of, 294.
development of, 294.
lobes of, 294.
structure of, 294.
Thyroid artery, 322.
vein, 354.
Thyroid (*thureos*, a shield; *eidos*, shape), 294.
development of, 294.
fluid of, 294.
lobes of, 294.
structure of, 294.
Thyroid cartilage, 288.
Tibia (a pipe or flute, from its supposed resemblance), 56.
of ox, 97.
of dog, 104.
Tibial artery. *See* Artery.
muscles, 200, 201.
nerve. *See* Nerve.
vein, 348.
Tibio-fibular articulation, 126.
Tissue, elastic, 108.
fibrous, 108.
white fibrous, 108.
Tongue, 210.
in ox, 2.
dissection of, 457.
of dog, 256.
frænum of, 210.
glands of, 211.
mucous membranes of, 211.
muscles of, extrinsic, 182.
intrinsic, 212.
Tongue, nerves of, 212.
of ox, 246.
papillæ of, circumvallate, 211.
conical and filiform, 211.
fungiform, 211.
of pig, 256.
raphe of, 210.
of sheep, 246.
vessels of, 212.
Tonsils, 226.
Torcular (a wine or oil press) Herophili, 389.
Trabeculæ (dim. from *trabo*, a beam) of corpus cavernosum, 272.
of spleen, 243.
Trabs cerebri, corpus callosum, 380.
Trachea (*arterea trachea*, the rough artery; *trachus*, rough), 294.
cartilage of, fibrous membrane of, 294.
crico-trachealis ligament of, 294.
mucous membrane of, 294.
situation of, 294.
structure of, 294.
vessels and nerves of, 294.
Trachelo-mastoid (*trachelos*, the neck; mastoid) muscle, 149.
suboccipitalis, 144.
Tract optic, 391.
Transverse arteries. *See* Artery.
Transversalis abdominis, 140.
costarum, 154.
Transverse suture, 83.
Trapezium (*trapezion*, dim. of *trapeza*, a table), 44.
Trapezoid bone, 45.
Trapezius muscle, 151.
Triceps. *See* Muscles.
Tricuspid (*tres*, three; *cuspus*, the point of a weapon) valve, 305.
Trifacial nerve, 392.
Triquetral (*triquetrus*, three-cornered) bones, 65.
Trochanter (*trochanter*, *trochaino*, *trochos*, words implying turning) of femur, 54.
of humerus, 39.
Trochlea (*trochilea*, a pulley) of femur, 55.
Tube, Eustachian, 421, 424.
Tuber cinereum, 379.
Tubercle of Lower, 304.
Tuberosity, alveolar, 74.
maxillary, 174.
of os calcis, 59.
Tubes, Fallopian, 277. *See* Fallopian Tubes.
uriniferous, 261.
convoluted, 261.
straight, 261.
Tubuli contorti (twisted or convoluted tubes) of kidney, 261.
recti of kidney, 261.

Tubuli seminiferi, 267.
uriniferi, 261.
Tunica abdominal, 136.
albuginea of sclerotic, 425.
albuginea of ovary, 278.
choroidea, 426.
Ruyschiana, 426.
vaginalis, 266.
Turbinated bones, 79.
of ox, 89.
of pig, 90.
Turner on a non-striped muscle connected with orbital periosteum of man and mammals, 474.
Tushes, appearance of, 224.
Tusks, 219.
Tying in of the knee, 45.
Tympanic (*tympanum*, the drum of the ear) artery, 339.
Tympanum (*tumpanon*, a drum) or middle ear, 419.
bones or ossicula of, 420.
cavity of, 420.
ligaments of, 421, 422.
membrane of, 420.
lining, 422.
muscles of, 421.
vessels and nerves of, 422.
walls of, 420.

Ulna (*olene*, the elbow), 41.
of dog, 103.
Ulnar artery, 328.
nerve, 408.
vein, 301.
Ulnaris accessorius, 98.
Umbilical (*umbilicus*, the navel cord) artery, 320.
region. *See* Abdomen.
Unciform (*uncus*, a hook; *forma*, shape) bone, 46.
Urachus (*ouron*, urine; *echo*, I hold), 262, 263.
Ureters (*oureo*, I pass urine), 262.
orifice of, 262.
structure of, 262.
Urethra, male, 270.
bulb of, 270.
crest of, 270.
fossa navicularis, 270.
glands and lacunæ of, 271.
lacuna magna, 271.
mucous membrane, 271.
orifice, external, 270.
internal, 270.
portion of bulbous, 270.
prostatic, 270.
spongy, 270.
sinus pocularis, 271.
Urinary bladder. *See* Bladder.
organs, 259.
dissection of, 460.
Urine, 259.
Uriniferous tubes, 261.
Uterine artery, 322.
Utero-ovarian artery, 320.
Uterus (womb), 275
arbor vitæ of, 276.
body of, 275.
cavity of, 276.
cervix or neck, 275.
cornua of, 275.
epithelium, 276.
fibres of, 276.
functions of, 275.
fundus of, 275.
ligaments of, 276.
broad, 276.
round, 276.
lymphatics of, 277.
mucous membrane of, 276.
nerves of, 271.
os or mouth of external, 275.
internal, 276.
tincæ of, 275.
position of, 275.
rugæ of, 276.
ruminants, in, 278.
sow, in, 279.
structure of, 276.
tissue, proper, of, 276.
vessels of, 276.
Utricle of vestibule of the ear, 424.
Uvea (*uva*, a cluster of grapes), 427.
Uvula (dim. of *uva*) of bladder, 263.
vesicæ, 263.

Vagina, 275.
nerves and vessels of, 275.
structure and connections, 275.
Vaginal artery, 321.
synovial membranes, 109.
Valsalva, sinuses of, 306.
Valve, Eustachian, 304.
of foramen ovale, 304.
mitral or bicuspid, 308.
of Thebesus, 304.
pyloric, 230.
tricuspid, 305.
Vieussens, 304.
Valves, auriculo-ventricular, 305, 308.
sigmoid or semilunar of aorta, 308.
pulmonary, 306.
of veins, 342.
Valvulæ conniventes, 232.
Vas abberans of testis, 268.

Vas deferens, 267, 268.
Vasa afferentia or efferentia of lymphatic glands, 357.
efferentia of testis, 267.
recta of kidney, 261.
of testis, 267.
Vasti muscles, 164.
Veins, general anatomy of, 341.
action of valves of, 342.
anastomoses of, 341.
coats of, 341.
contractility of, 341.
muscular fibres in, 341.
structure of, 341.
valves of, 342.
varieties of, 341.
vessels and nerves of, 343.
vital properties of, 341.
Veins, descriptive anatomy of, 343.
auricular, 352.
axillary, 350, 362.
azygos, 350.
brachial, external, 352.
internal, 352.
bronchial, 343.
buccal, 354.
cardiac, 343.
cephalic, 354.
circumflex of iliac, 349.
coronaries, 353.
coronary plexus, 346.
diaphragmatic, 344.
dorsal, 350.
femoral, 346, 349.
frog, veins of, 347.
gastro-epiploic, 345.
glosso-facial, 353.
hepatic, 344.
humeral, 352.
iliac, 345.
external, 349.
internal, 349.
interosseus of foot, 347.
jugular, 352.
laminal plexus, 346.
lingual, 355.
lumbar, 345.
maxillary, internal, 354.
mesenteric, anterior, 345.
posterior, 345.
metacarpal, 351.
metatarsal, 346, 347.
occipital, 353.
pedal plexuses, 351.
plantar, 346, 347.
popliteal, 346, 349.
portal, 344.
pulmonary, 343.
Veins, radial, anterior, 351.
posterior, 351.
renal, 345.
saphenous, great, 348.
lesser, 349.
solar plexus, 346.
spermatic, 345.
splenic, 345.
subzygomatic, 354.
systemic, 343.
temporal superficial, 354.
thoracic, internal, 350.
subcutaneous or spur, 352.
thyroid, 354.
tibial, anterior, 348.
posterior, 348.
ulnar, 351.
vena cava, anterior, 349.
posterior, 344.
varicosa, 353.
vertebral, 350.
Velum pendulum palati, 208.
dissection of, 457.
Vena cava, anterior, 349.
posterior, 344.
opening in diaphragm for, 170.
portal, 240.
tributaries of, 239.
Venæ Galeni (veins of Galen), 377.
Venous blood, characters of, 341.
Ventricles (*ventriculus*, dim. of *venter*, a belly),
choroid plexuses, 383.
of corpus callosum, 380.
fifth, 381.
fourth, 377.
lateral, 380.
choroid plexuses of, 381.
cornua of, 381.
of septum or Sylvian, 381.
third, 384.
choroid plexuses of, 383.
commissures of, 384.
communication with lateral ventricles, 384.
of heart, 305, 307.
fibres of, 310.
interior of, 305, 307.
left, 307.
right, 305.
Vertebrata dentata, 20.
prominens, 21.
Vertebræ, cervical, 17.
of ox, 94.
first and second, 18, 20.
of ox, 94.
of pig, 99.
coccygeal, 27.

Vertebræ, coccygeal, of ox, 196.
of pig, 100.
of dog, 101.
cranial, 470, 471.
dorsal, 22.
of ox, 95.
of pig, 99.
false, 17.
general characteristics of, 15.
homologies of, 469.
lumbar, 24.
of ox, 95.
of pig, 99.
number of, 17, 22, 24, 25, 27.
in ox, 94.
in pig, 99.
in dog, 101.
sacral, 25.
serial relations, 469.
typical, 469.
Vertebral artery, 326, 333.
column, 15.
of ox and sheep, 94.
of pig, 99.
of dog, 101.
form of, 15.
ligaments of, 112.
Vesica prostatica. *See* Prostate.
urinaria (urinary bladder). *See* Bladder.
Vesicles of De Graaf, 278.
changes in, 278.
seminal, 268.
in dog and cat, 279.
ox, sheep, and ruminants generally, in, 278.
structure of, 268.
sinus pocularis of, 269.
Vesico-prostatic artery, 320.
Vessels. *See* Arteries and Veins.
Vestibule, aqueduct of, 68.
of ear, 422.
aqueduct of, 422.
scala of, 422.
nerve of, 398.
Vestigium foraminis ovalis, 304.
Vidian canal, 69.
fissure, 69.
Vieussens, isthmus of, 304.
valve of, 376.
Villi (*villus*, shaggy hair) of small intestine, 233.
Vitreous (*vitrum*, glass) humour, 429.
Vocal cords, 292, 293.
Voluntary muscle, 131.
Vomer (a ploughshare), 78.
of ox, 90.
Vulva, 273.
commissures of, 273.
erectile tissue of, 274.
fissura magna of, 274.
fossa navicularis of, 274.
glands of, 274.
labia of, 274.
mucous membrane of, 274.
muscles of, 275.

Wagner on contraction of palpebral fissure, &c., 478.
Wall-eyed horse, colour of pupil in, 427.
Wharton's duct, 213.
of ox, 246.
of dog, 256.
Willis' classification of cranial nerves, 390.
circle of, 387.
Wilson's muscle, 273.
Wirsung's canal, 242.
Womb. *See* Uterus.
Wormian bones, 65.

Zinn's zonule, 428.
Zonula Zinnii *vel* ciliaris, 428.
Zygapophyses (*sug*, a root of *seugnumi*, I yoke or join together; *apophysis*), 470.
Zygomatic arch (a cross bar or bolt, from a root above given), 67.
bone, 76.
spine, 67.
Zygomatici muscles, 171, 174, 175, 178.

PRINTED BY NEILL AND COMPANY, EDINBURGH.

MACLACHLAN & STEWART'S PUBLICATIONS.

Mr T. ANNANDALE, F.R.S., F.R.C.S.

SURGICAL APPLIANCES AND MINOR OPERATIVE SURGERY. Illustrated with Eighty Woodcuts. Fcap. 8vo, 5s.

Also, by the same Author:—

I.

ABSTRACTS OF SURGICAL PRINCIPLES FOR MEDICAL STUDENTS.

Part I. Inflammation, Suppuration, Mortification, and Ulceration. 2. Tumours. 3. Dislocations. 4. Fractures. Price 1s. each.

II.

OBSERVATIONS AND CASES IN SURGERY, 1s.

Dr JOSEPH BELL, F.R.C.S.

A MANUAL OF THE OPERATIONS OF SURGERY, FOR the USE of SENIOR STUDENTS, HOUSE SURGEONS, and JUNIOR PRACTITIONERS. Second Edition, fcap. 8vo, copiously illustrated, 6s.

BLAINE'S VETERINARY ART.

BLAINE'S OUTLINES OF THE VETERINARY ART; OR, a TREATISE on the ANATOMY, PHYSIOLOGY, and CURATIVE TREATMENT of the DISEASES of the HORSE. Seventh Edition, by Charles Steel, M.R.C.V.S.L. Illustrated by Surgical and Anatomical Plates. 8vo, cloth, 18s.

Mr JAMES BOYD DAVIES.

PRACTICAL NATURALIST'S GUIDE, CONTAINING INSTRUCTIONS for Collecting, Preparing, and Preserving Specimens in all Departments of Zoology, intended for the use of Students, Amateurs, and Travellers. Fcap. 8vo, 2s.

By Professor GAIRDNER, Glasgow.

OUTLINE FIGURES FOR RECORDING PHYSICAL DIAGNOSES; for the Use of Students, Army and Navy Surgeons, and Medical Practitioners. Second Edition, price 1s. 1d., free by post.

Professors GAMGEE and LAW.

GENERAL AND DESCRIPTIVE ANATOMY OF THE DOMESTIC ANIMALS, with numerous Illustrations. Royal 8vo. Part I., 12s.; Part II., 10s. 6d.

Professor JOHN GAMGEE, M.R.C.V.S.

DAIRY STOCK; ITS SELECTION, DISEASES, AND PRODUCE. With a Description of the Brittany Breed. Plates. Fcap. 8vo, 7s. 6d.

OUR DOMESTIC ANIMALS IN HEALTH AND DISEASE.

First Division.—Organs of Digestion: their Functions and Disorders.

Second Division.—Organs of Circulation and Respiration.

Third Division.—Organs of Secretion. Urinary System: its Functions and Disorders. Cutaneous System: its Functions and Disorders. Epizootic and Enzootic Maladies.

Fourth Division.—Enzootic Disorders. Functions and Diseases of the Nervous System. The Art of Shoeing and Lameness. Crown 8vo. *Profusely Illustrated,* 6s. each, or bound in 2 vols., 22s.

DR GUY AND DR JOHN HARLEY.

HOOPER'S PHYSICIANS' VADE MECUM; OR, MANUAL of the PRINCIPLES and PRACTICE of PHYSIC. Seventh Edition, considerably Enlarged and re-written. Fcap. 8vo. 12s. 6d.

DR R. E. SCORESBY-JACKSON, F.R.S.E.

NOTE-BOOK OF MATERIA-MEDICA, PHARMACOLOGY, and THERAPEUTICS, embracing all the Medicines of the British Pharmacopœia. New edition, bringing the Work down to the present time (1870), by Dr A. MACDONALD, Lecturer on Materia Medica, Surgeon's Hall. Crown 8vo.

DR J. MACKENZIE.

THE FAMILY MEDICAL GUIDE. 18mo, 6d.

DR J. MOORE NELIGAN.

MEDICINES, THEIR USES AND MODE OF ADMINISTRATION, including a Complete Conspectus of the British Pharmacopœia, an account of New Remedies, and an Appendix of Formulæ. Seventh Edition. Edited by RAWDON MACNAMARA, M.R.I.A. 8vo, price 18s.

DR WILLIAM SWEETSER.

MENTAL HYGIENE; OR, AN EXAMINATION OF THE INTELLECT and PASSIONS, designed to Illustrate their Influence on Health and the Duration of Life. Royal 8vo, 1s.

DR P. H. WATSON, F.R.C.S.

THE MODERN PATHOLOGY AND TREATMENT OF VENEREAL DISEASES. 8vo, 1s.

EXCISION OF THE KNEE-JOINT. A DESCRIPTION OF A NEW APPARATUS for the AFTER TREATMENT, with Illustration Cases. 8vo, cloth, price 3s. 6d.

PROFESSOR LIZARS.

PRACTICAL OBSERVATIONS ON THE USE AND ABUSE of TOBACCO. Illustrated with three Coloured Plates. 8vo. Ninth Edition, price 1s.

Also, by the same Author:—

PRACTICAL OBSERVATIONS ON THE TREATMENT OF STRICTURE of the URETHRA and FISTULA in PERINEO. Illustrated with Cases and Drawings of these Affections. Third Edition, greatly Improved and Enlarged. 8vo, 3s. 6d.

EDINBURGH VETERINARY REVIEW, 1859 to 1864.

Six vols. 8vo, bound, £1, published at £5.

THE CATTLE PLAGUE.

REPORTS TO THE LORD PROVOST AND MAGISTRATES of the CITY of EDINBURGH on the *Pathological Appearances, Symptoms, Treatment, and Means of Preventing Cattle Plague*. With 27 Coloured Lithographs, and Analytical Tables of 100 Dissections, by ANDREW SMART, M.D. 4to. Sewed, 3s. 6d.

LONDON: SIMPKIN, MARSHALL, & CO., AND R. HARDWICKE,
192 PICCADILLY.